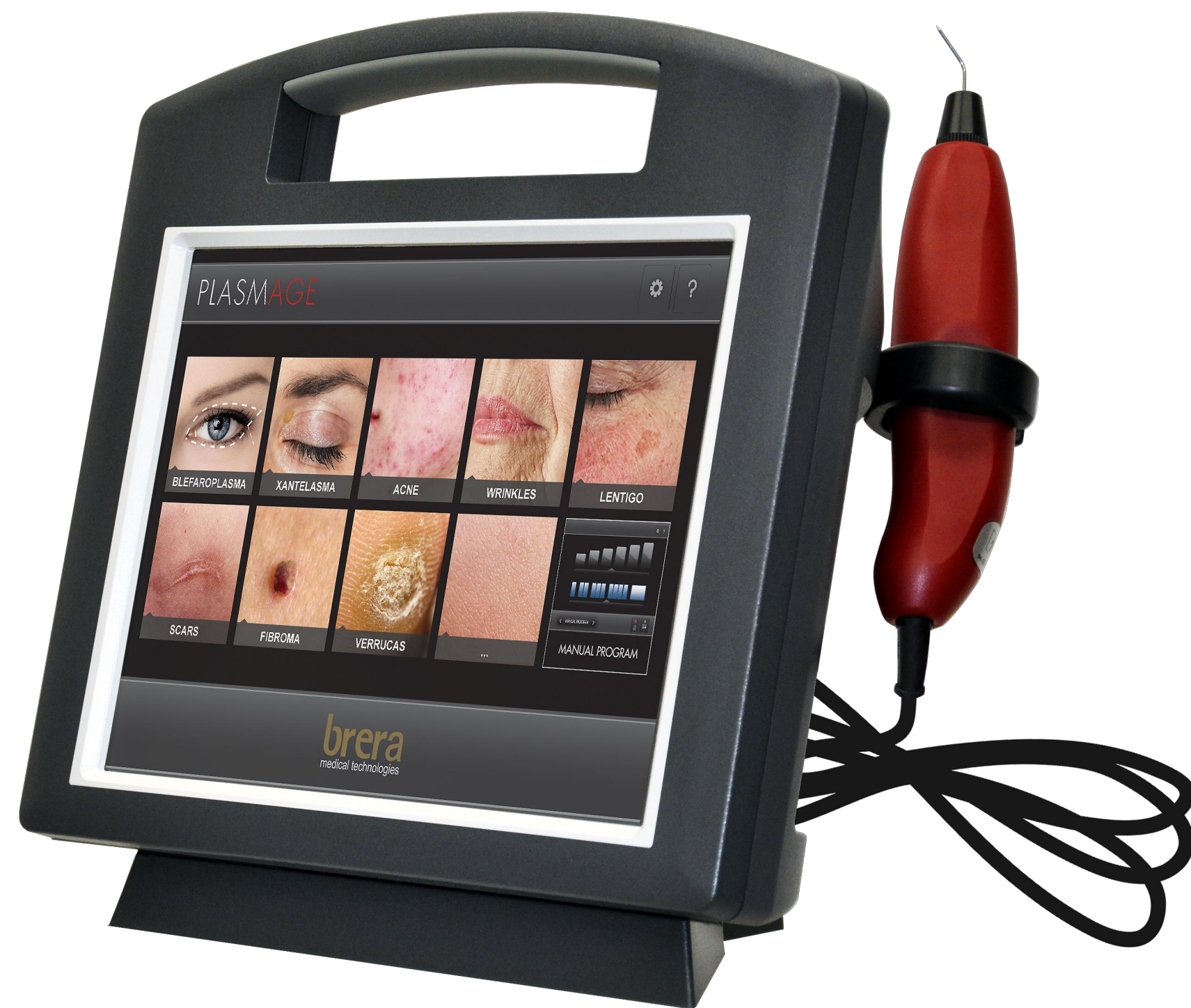



BEFORE AND AFTER GALLERY

PLASMA**A**GE

PLASMA^{AGE}



On the cutting edge of medical technologies:

- Plasma based energy
- Patented Fractional Plasma
- Extreme precision
- Non ablative
- Fine tuning of the power



PLASMA[®]GE

Blefaroplasma, the new concept of eye lifting:

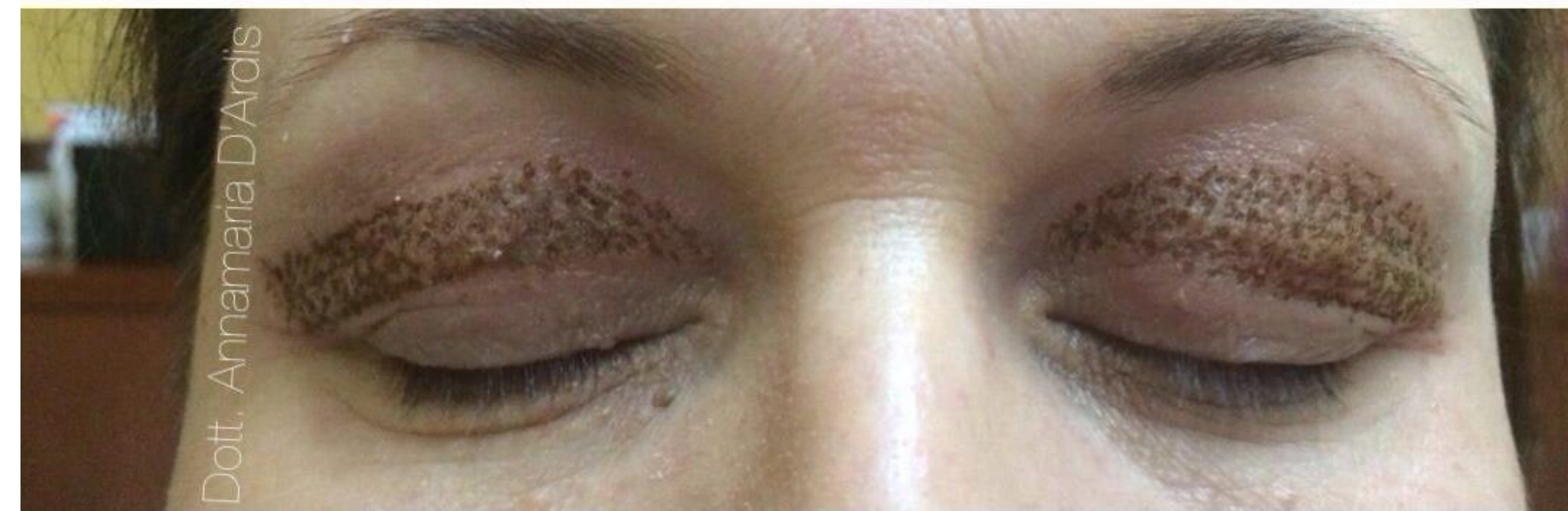
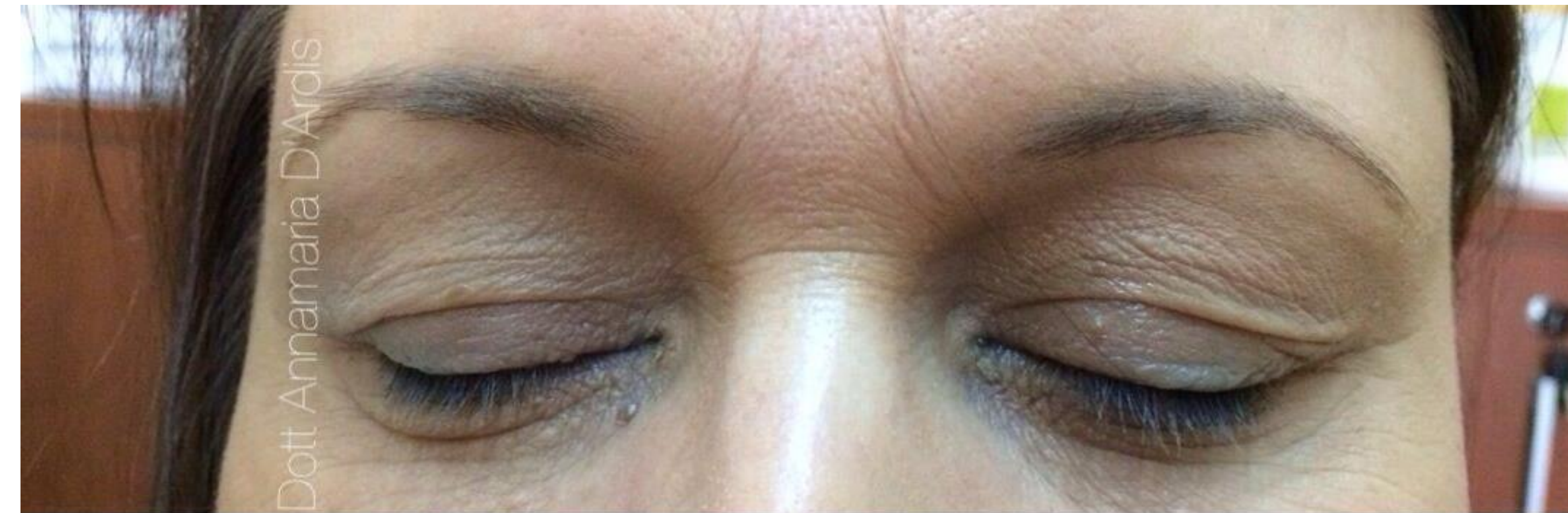- Sublimation of the skin
- Upper, lower eyelids and crows feet
- Short time recovery
- Impressive results

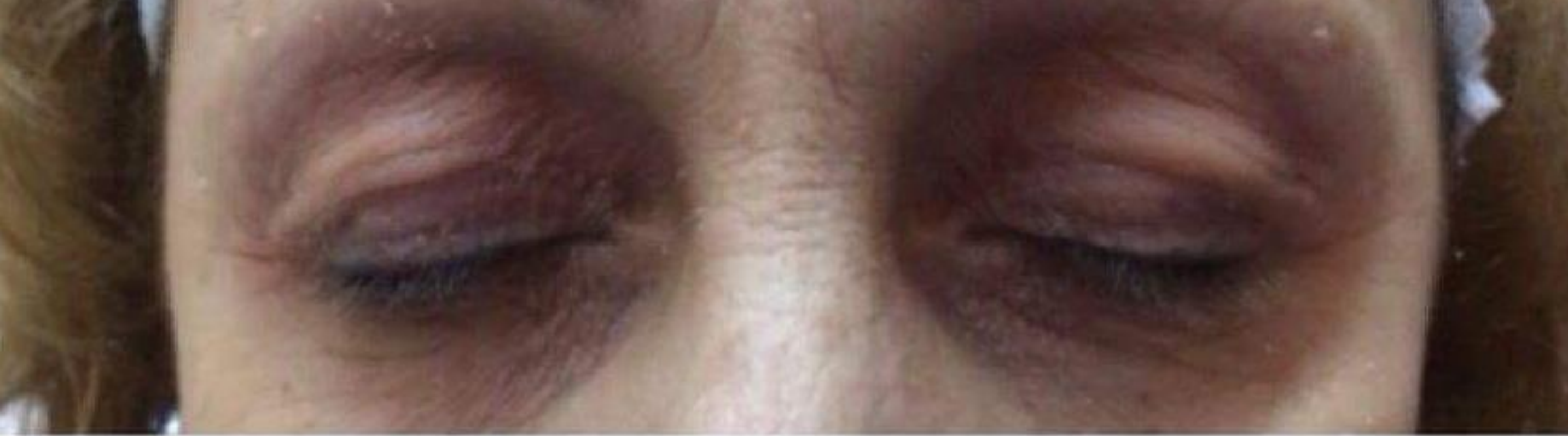PLASMA[®]

Blefaroplasma[®]

- with the courtesy of Dr. Annamaria D'Ardis, Napoli, Italy
- 1 session: before, right after the treatment and 10 days later

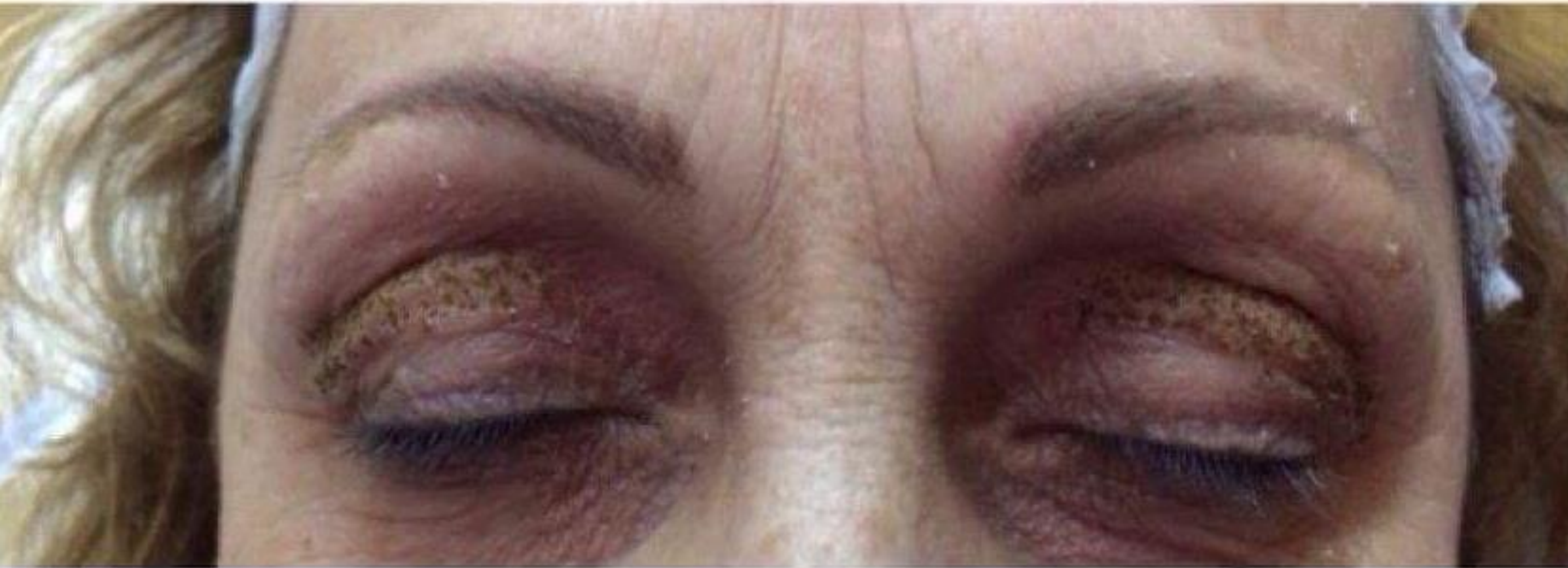brera[®]
medical technologies





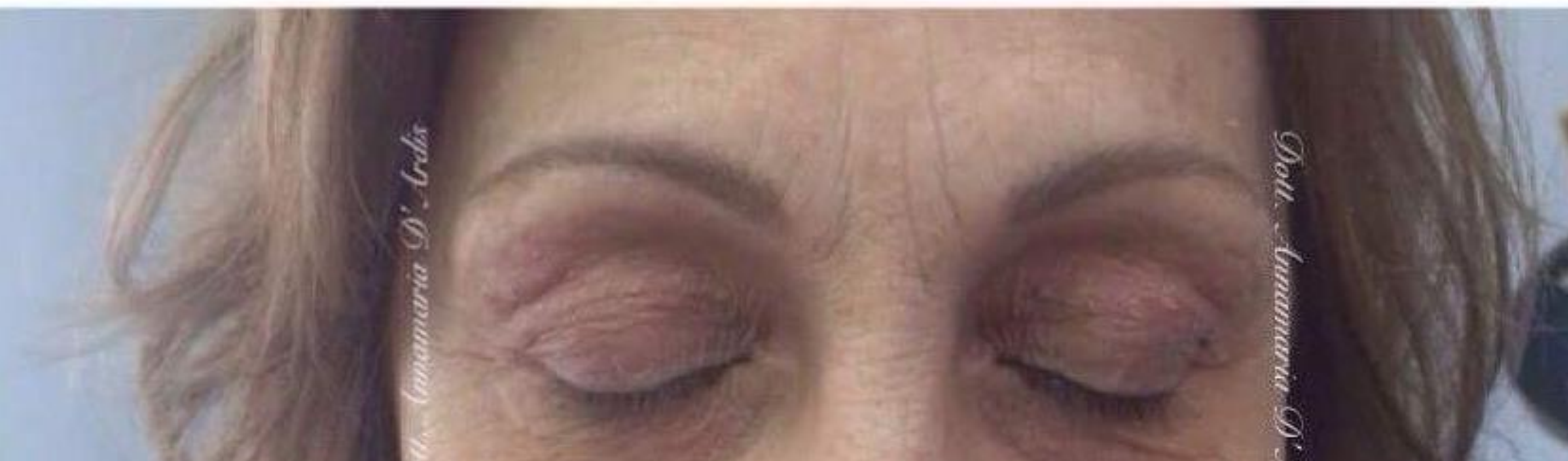PLASMA[®]

Blefaroplastia[®]

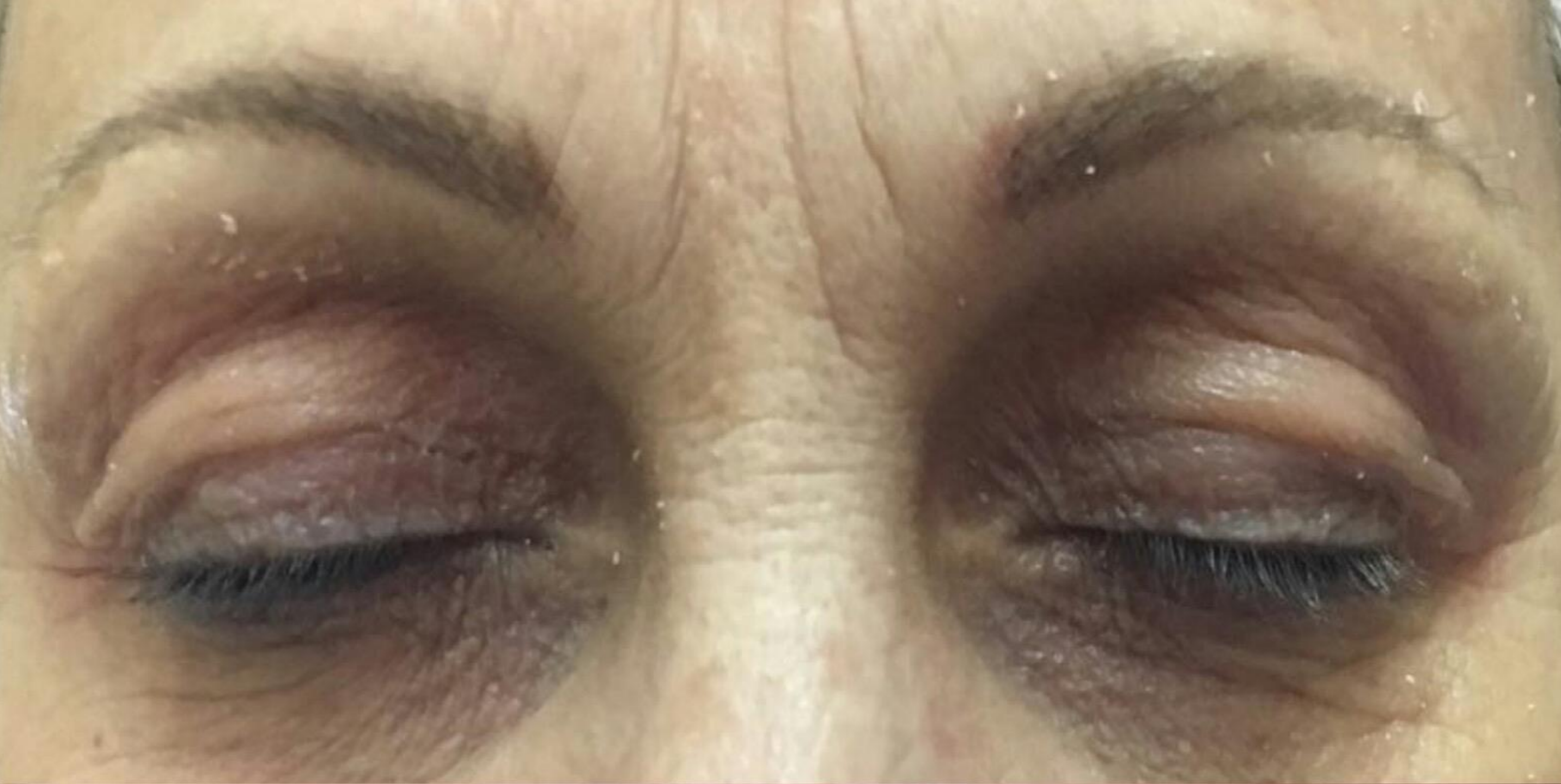

➤ with the courtesy of Dr.
Annamaria D'Ardis, Napoli, Italy

➤ 1 session: before, right after the
treatment and 7 days later



brera[®]
medical technologies

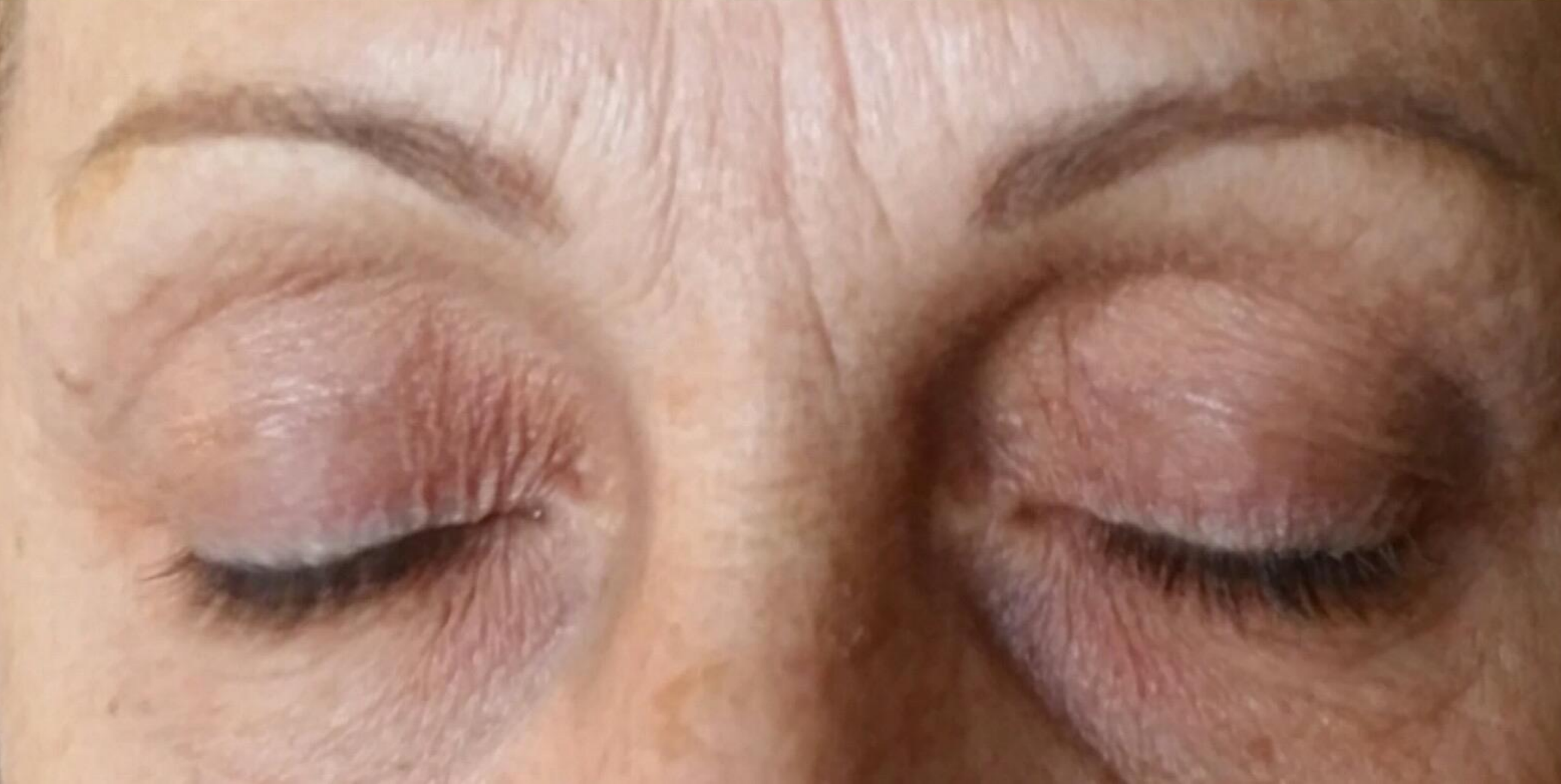

PLASMA[®]GE

Blefaroplasma[®]

- with the courtesy of Dr. Annamaria D'Ardis, Napoli, Italy

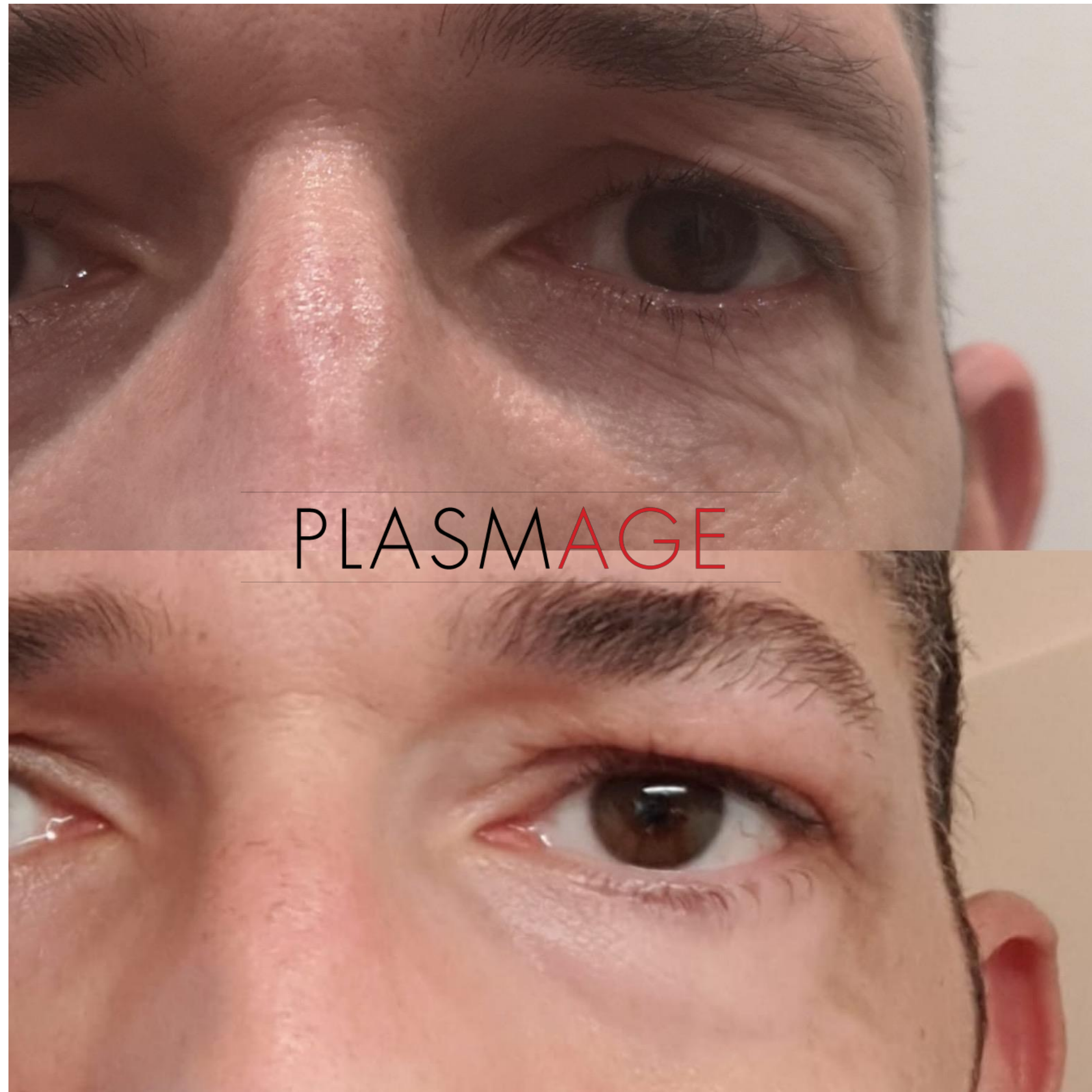- same patient, a totally new rejuvenated skin 6 months later with one session



PLASMA[®]GE

Blefaroplasma[®]

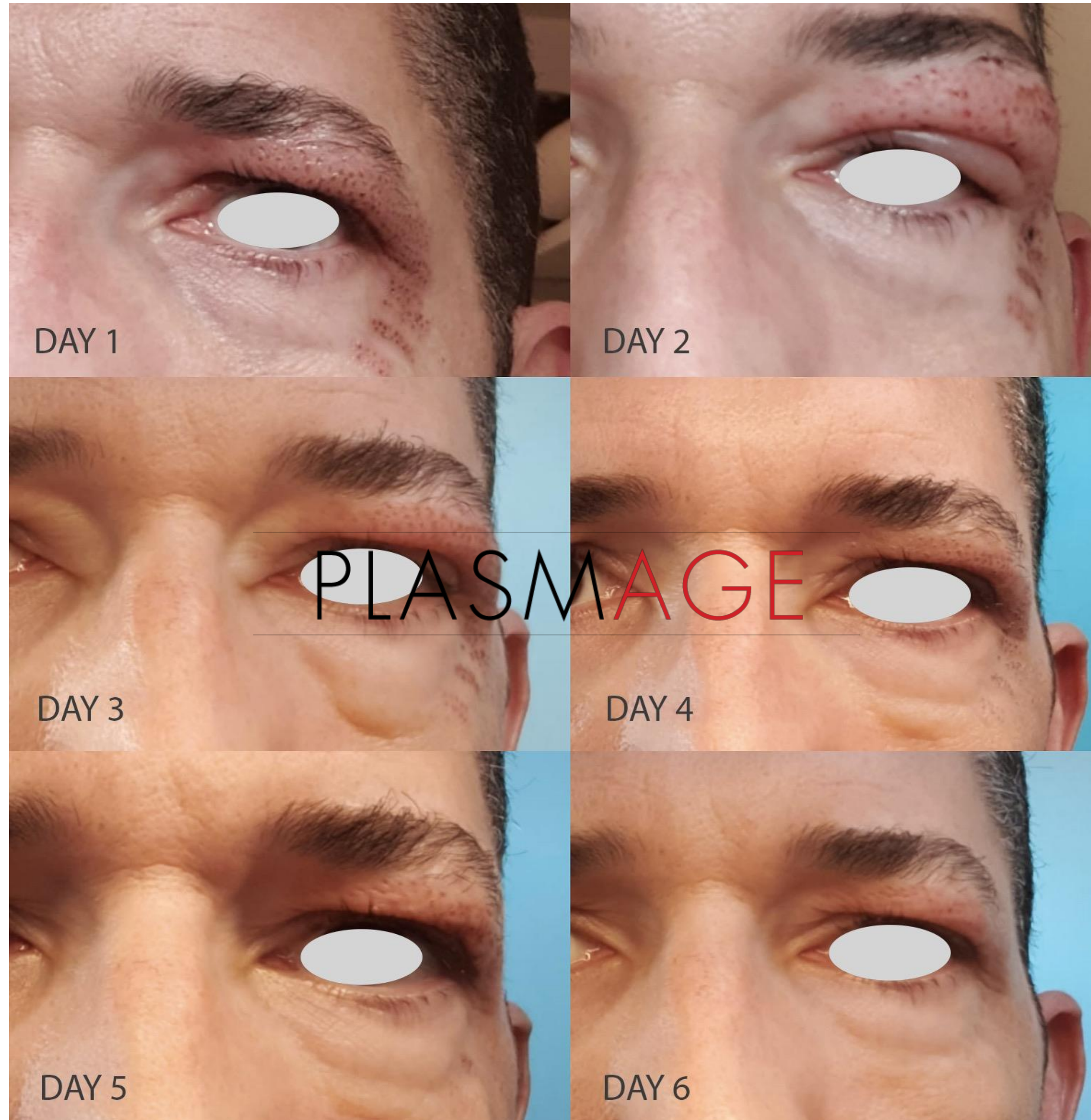- with the courtesy of Brera Medical
- before and after 3 weeks

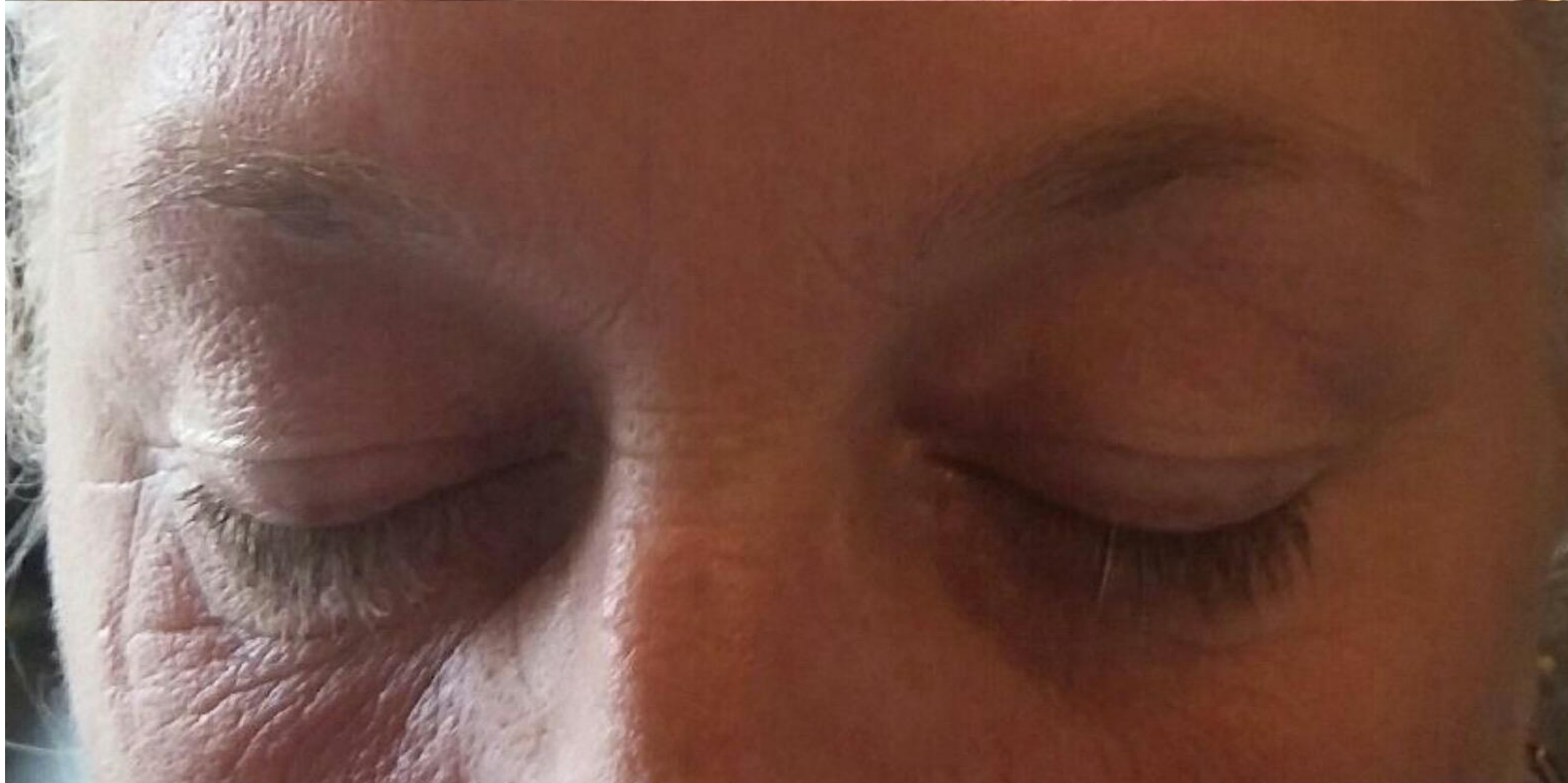
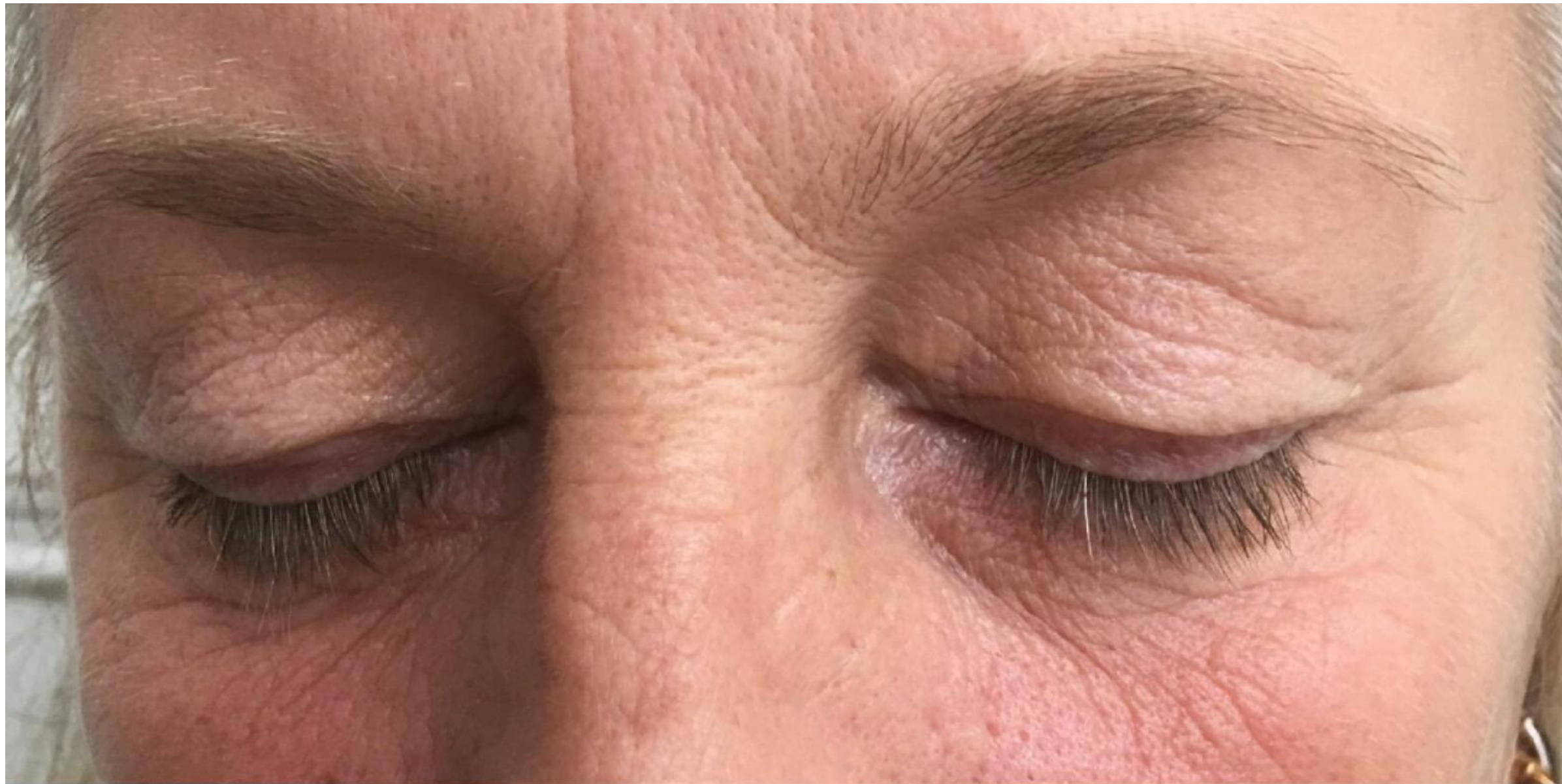
PLASMA[®]GE

Blefaroplasma[®]

- with the courtesy of Brera Medical
- Same patient, follow up of the swelling and crusting





PLASMA[®]GE

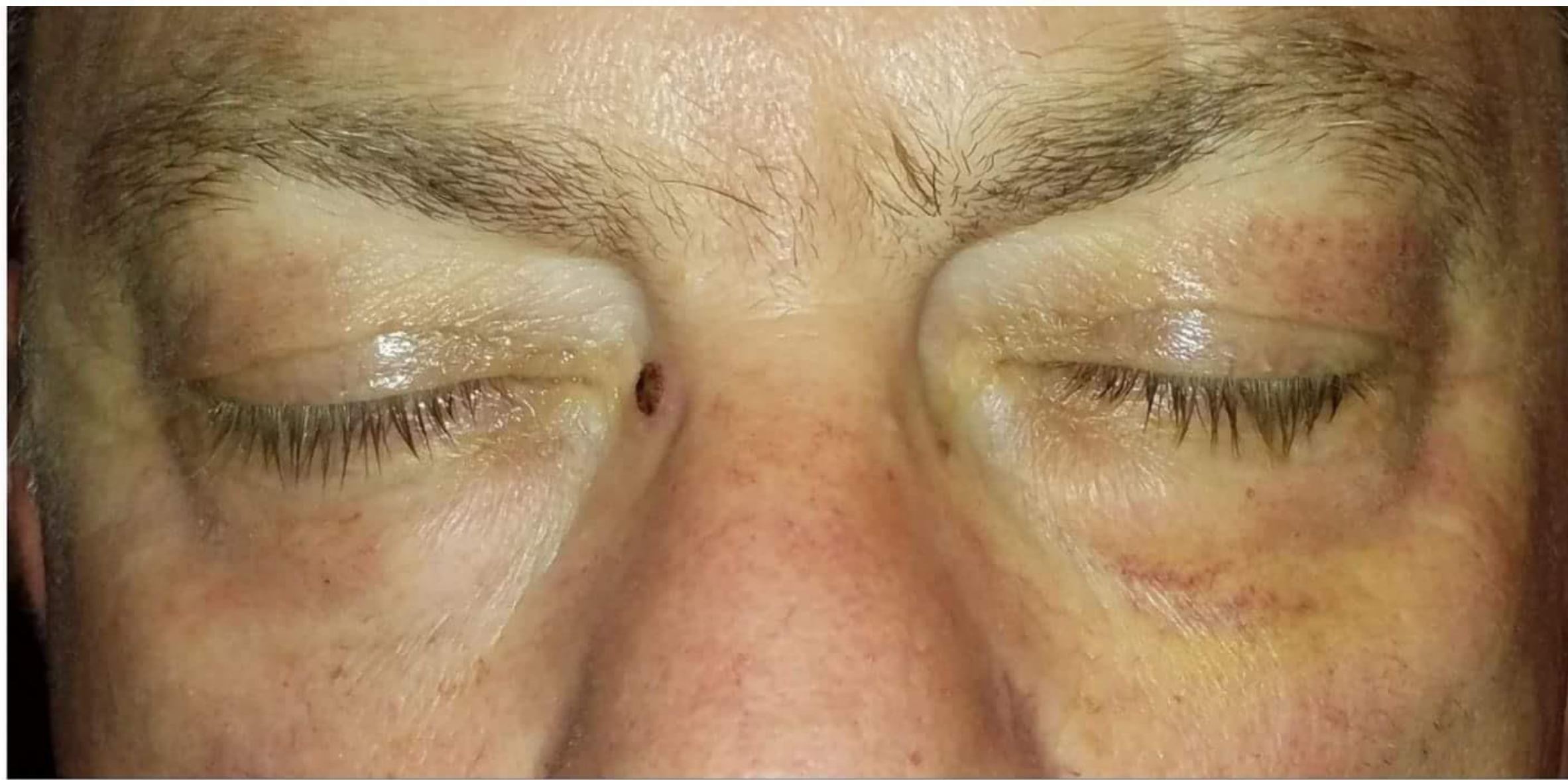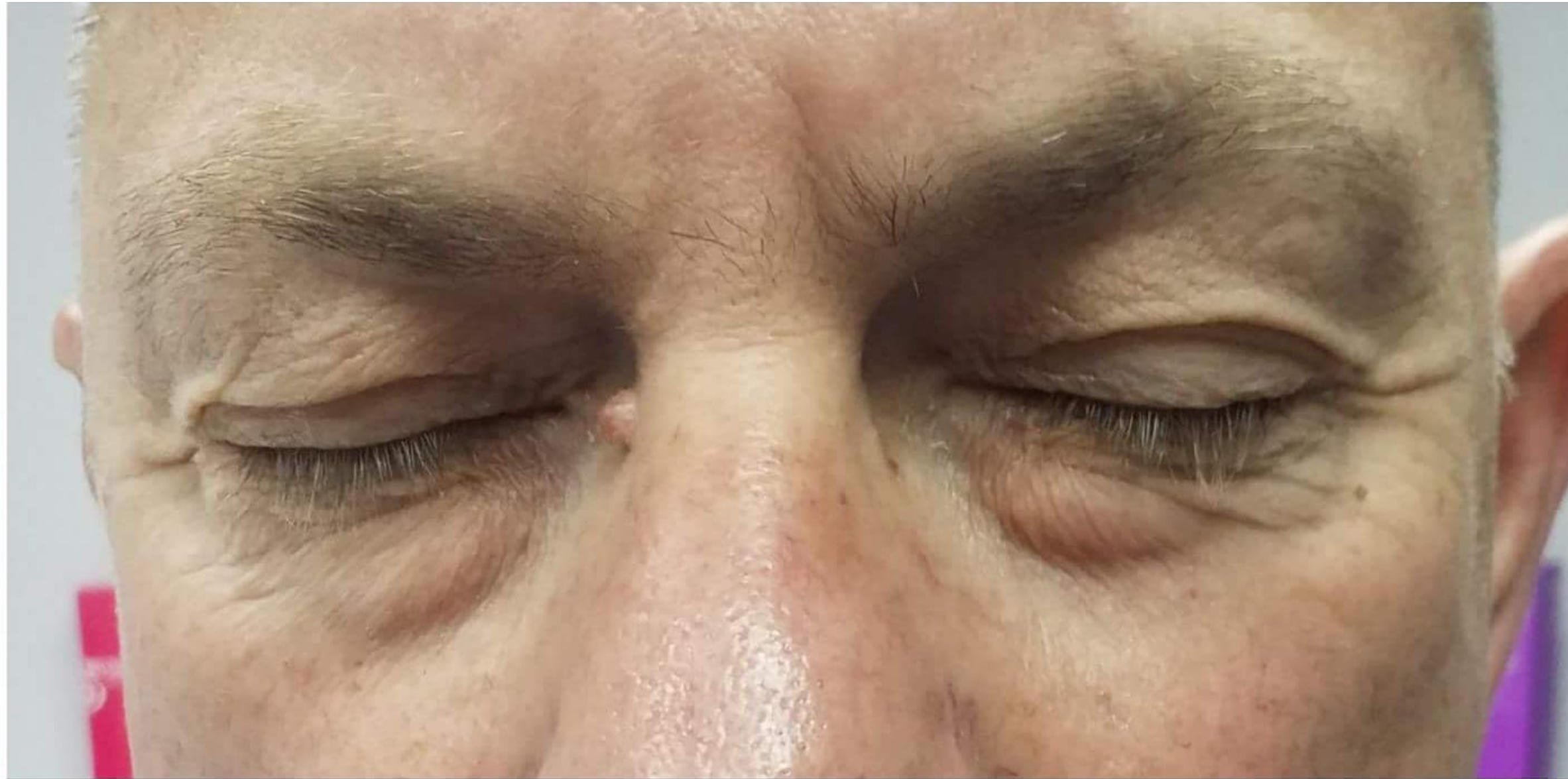Blefaroplastia[®]

- with the courtesy of Dr. Kate Goldie, London, UK

- 1 session: before then 60 days later

PLASMA[®]

Blefaroplasma[®]

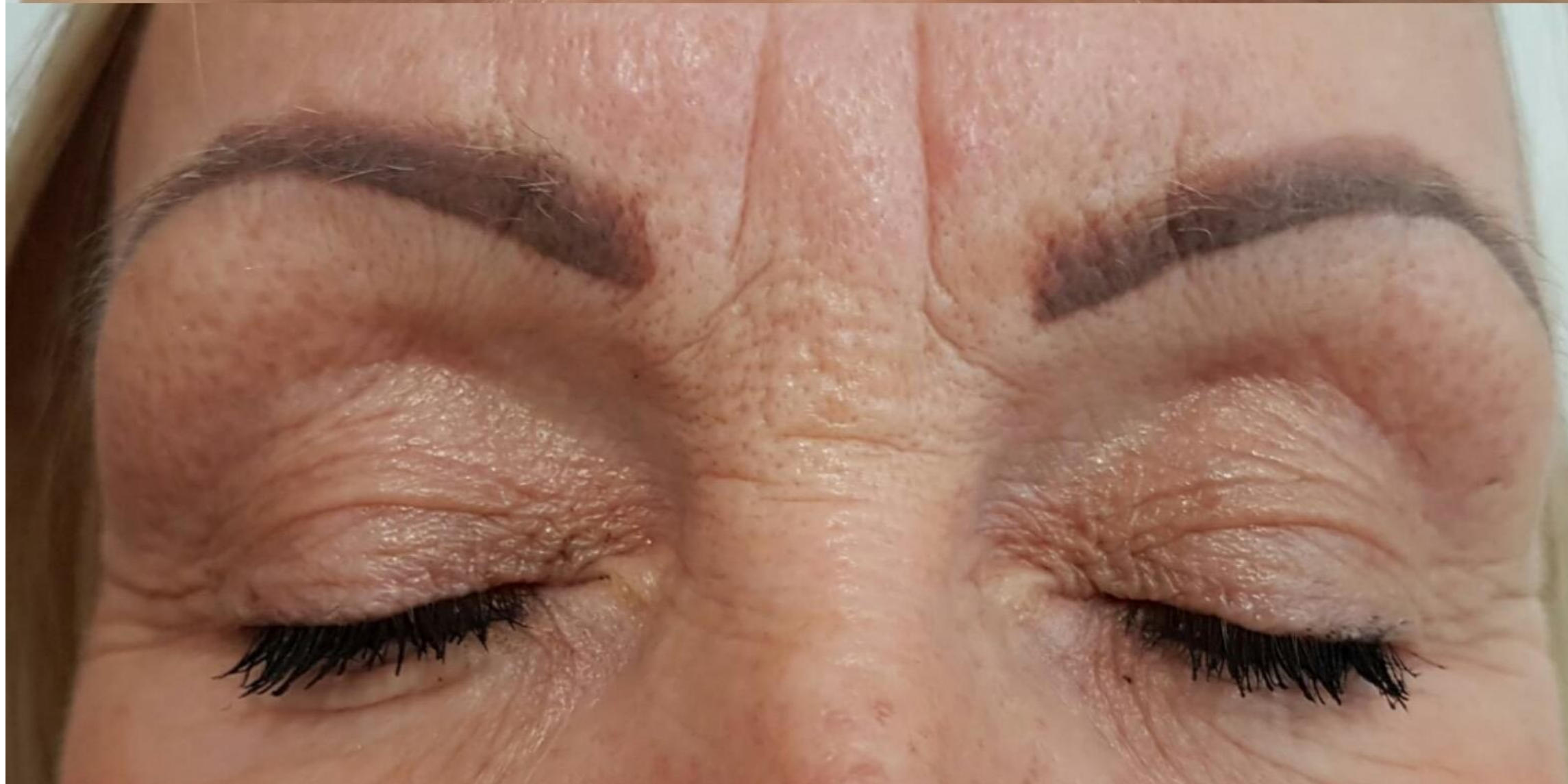
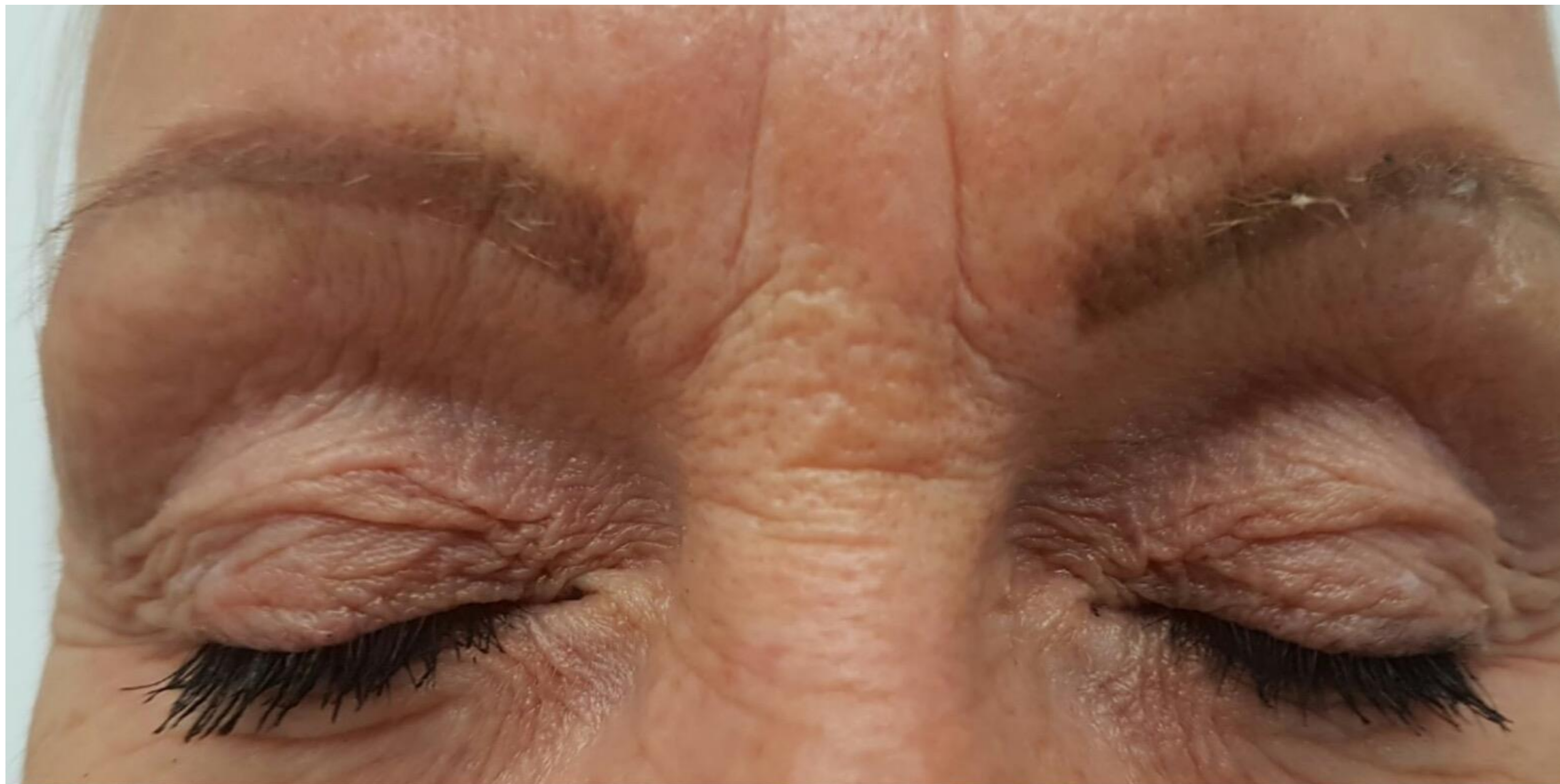
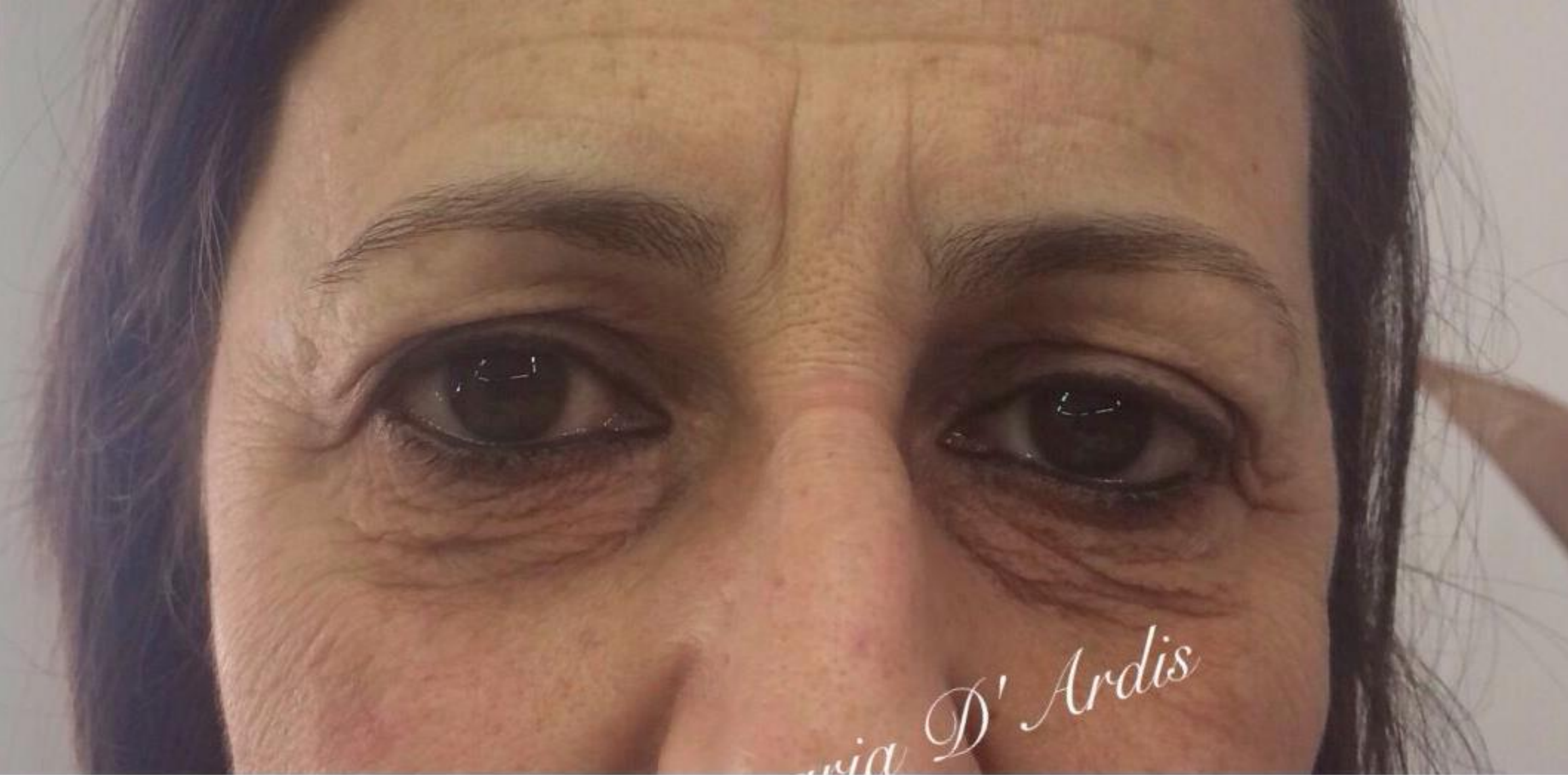- 1 session: before then 10 days
- One mole removed as well

PLASMA[®]GE[®]

Blefaroplasma[®]

- with the courtesy of Dr David Crispin Chavez, London, UK
- 1 session: before and 15 days later

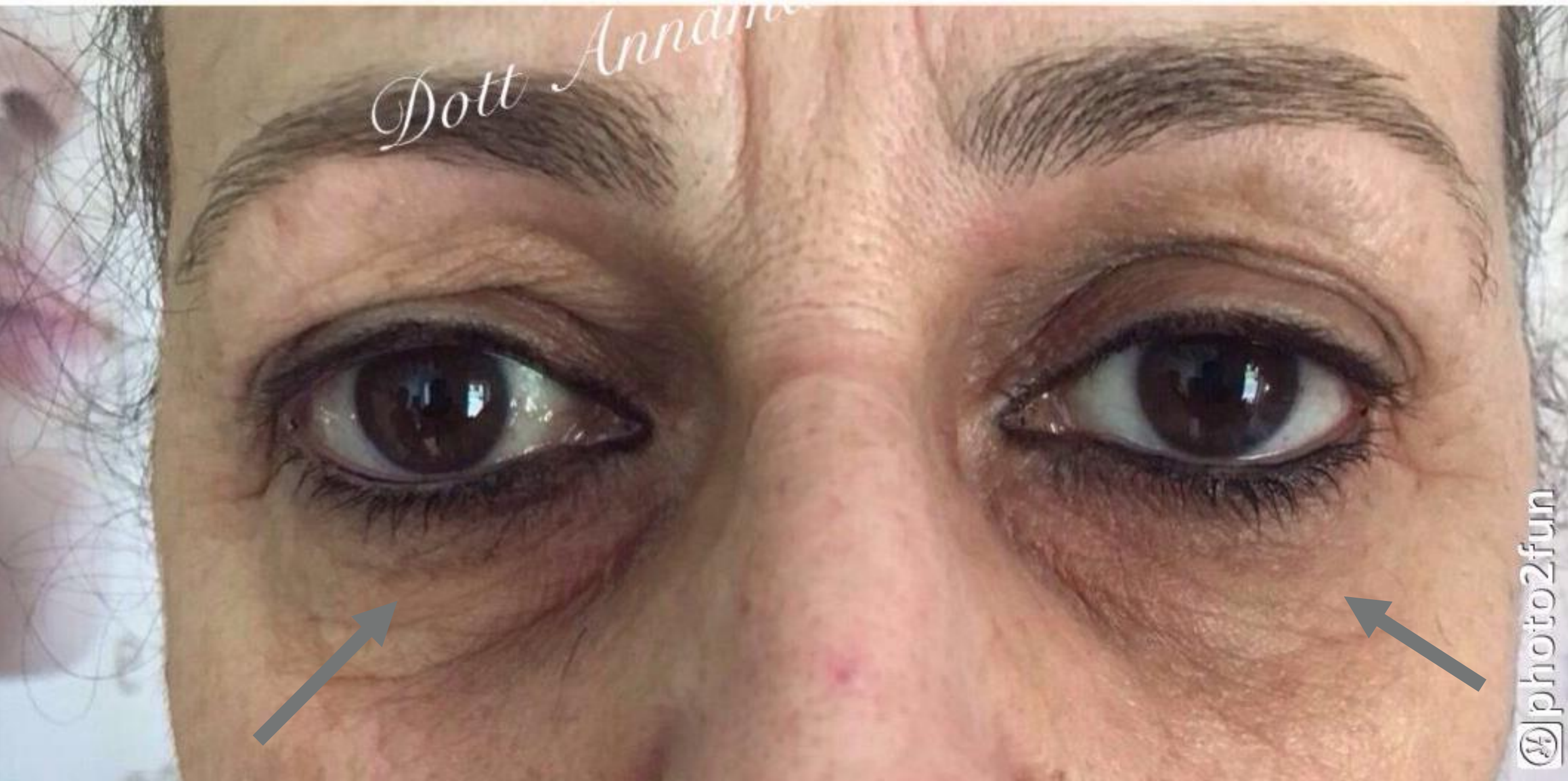



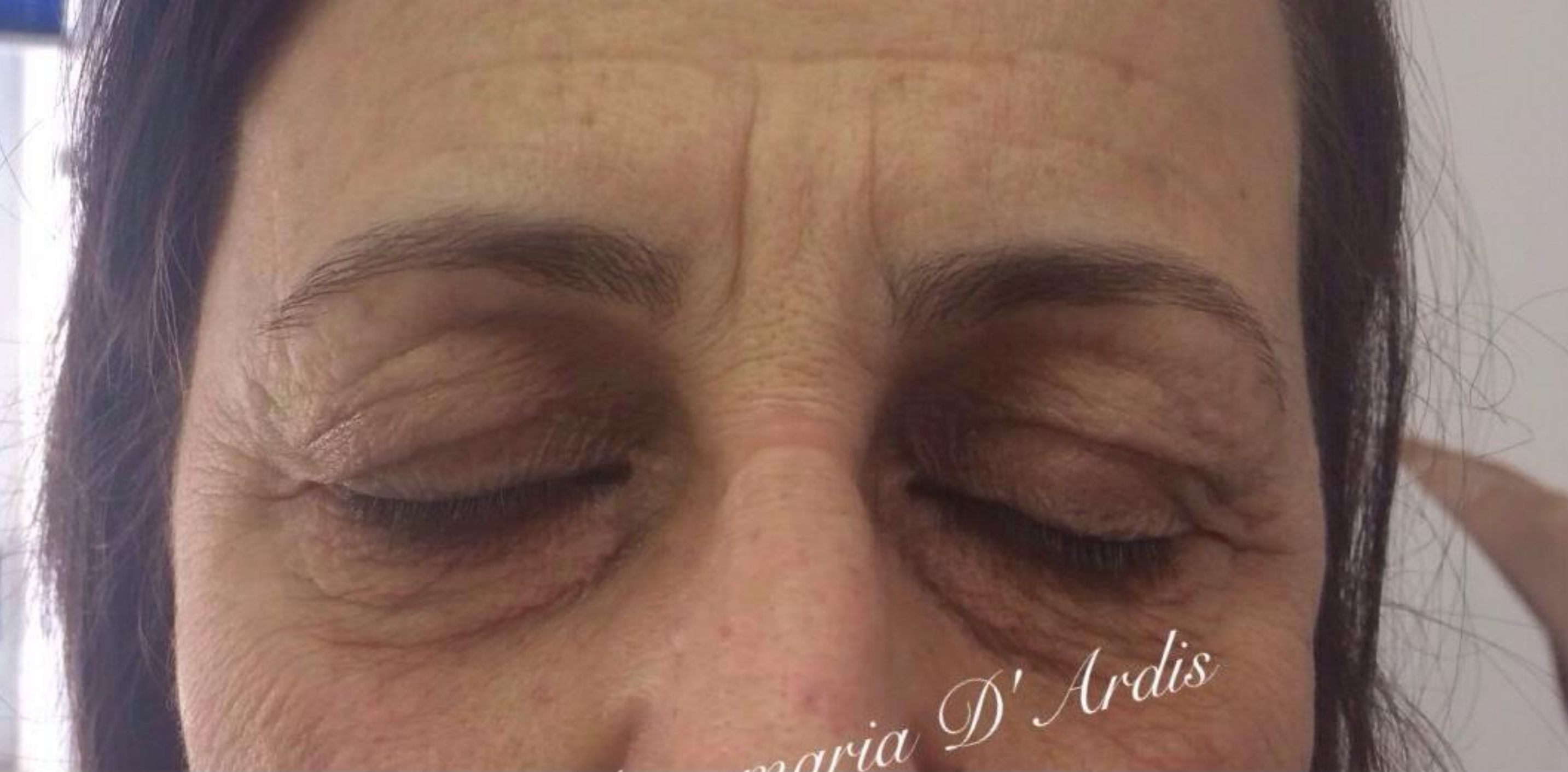PLASMA[®]GE

Blefaroplasma[®]

- with the courtesy of Dr. Annamaria D'Ardis, Napoli, Italy
- 1 session: before and 15 days later



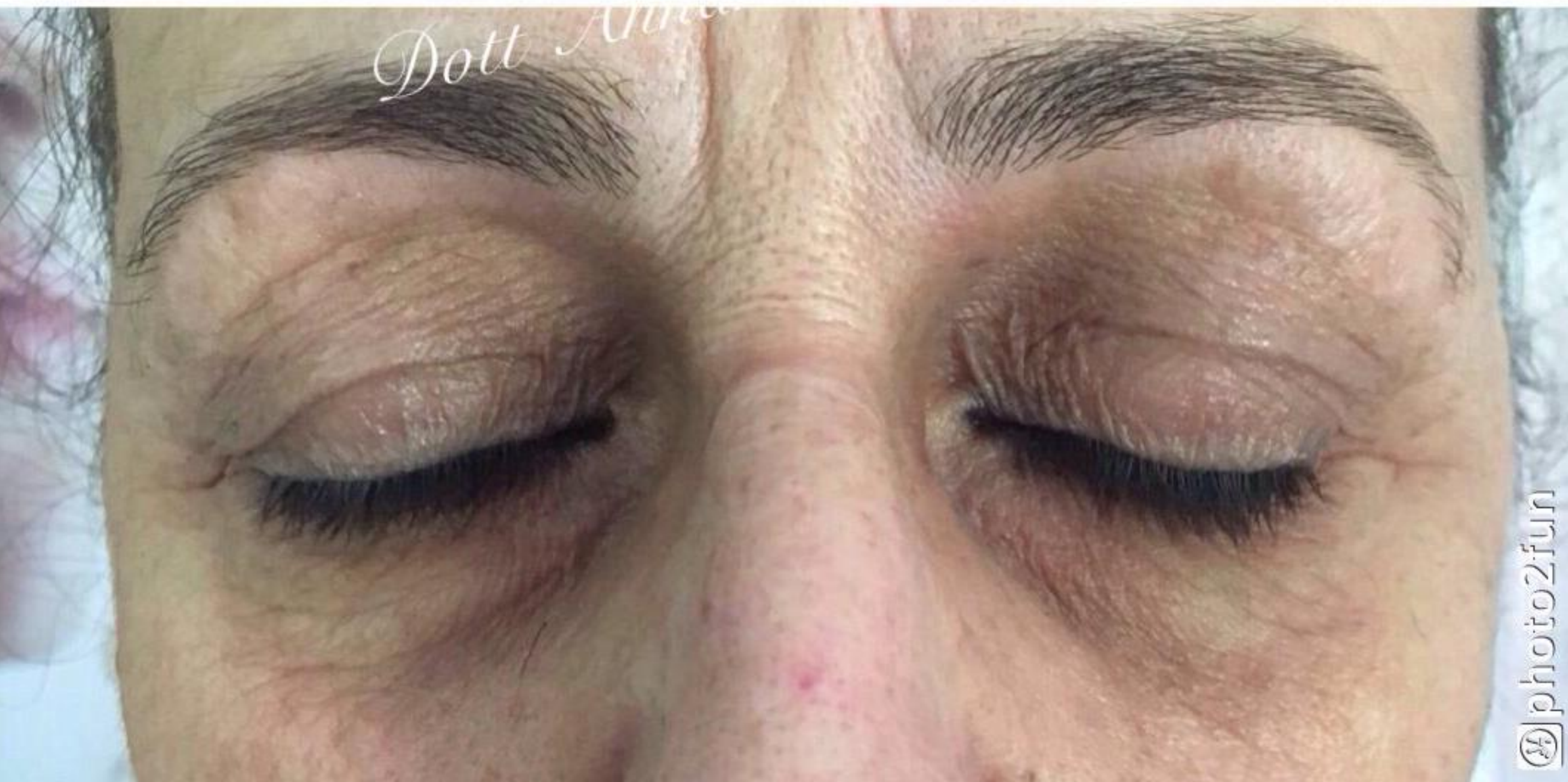brera[®]
medical technologies



PLASMA[®]GE

Blefaroplasma[®]

- with the courtesy of Dr. Annamaria D'Ardis, Napoli, Italy
- 1 session: before and 15 days later

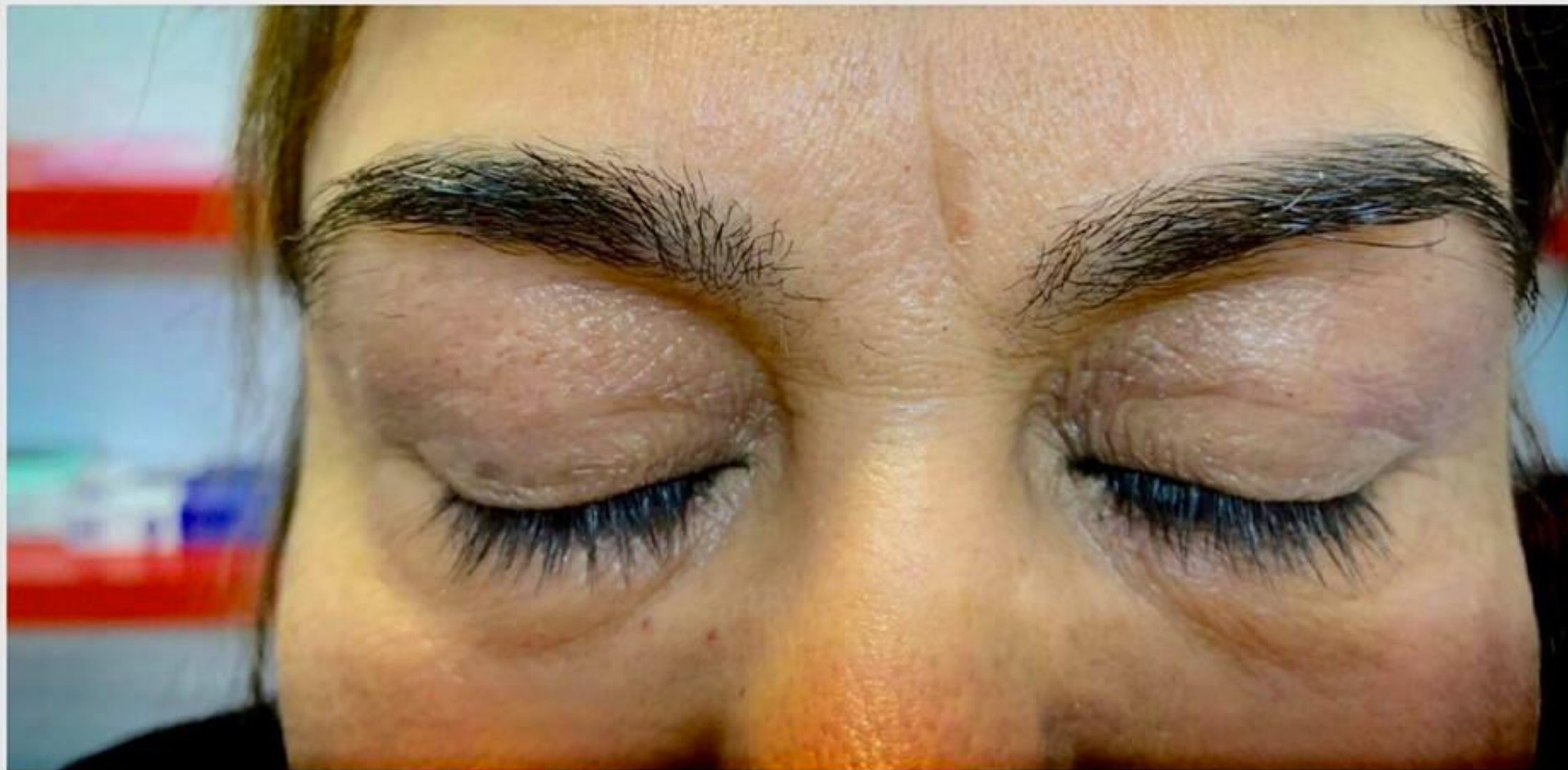
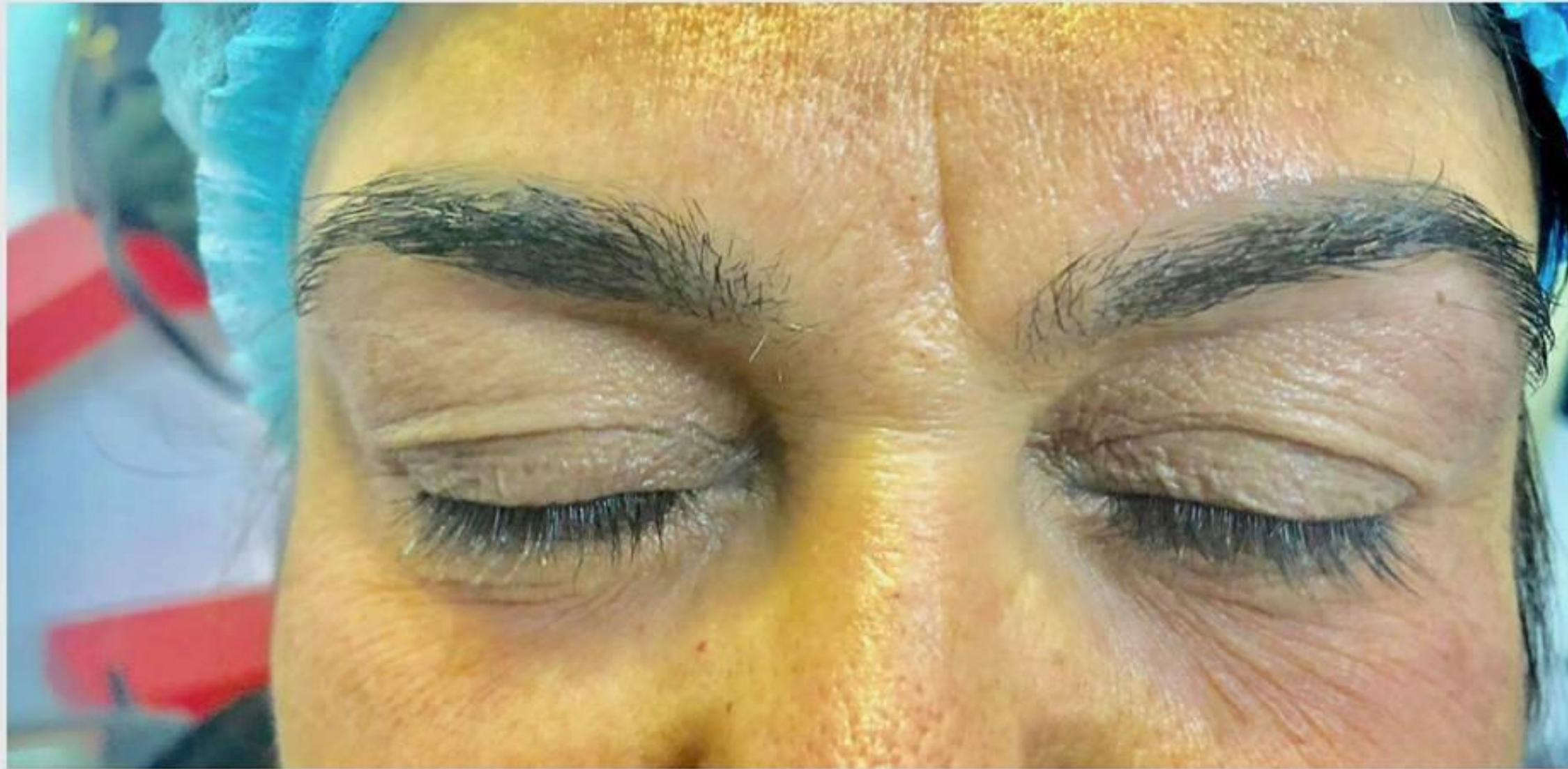
brera[®]
medical technologies

PLASMA[®]

Blefaroplasma[®]

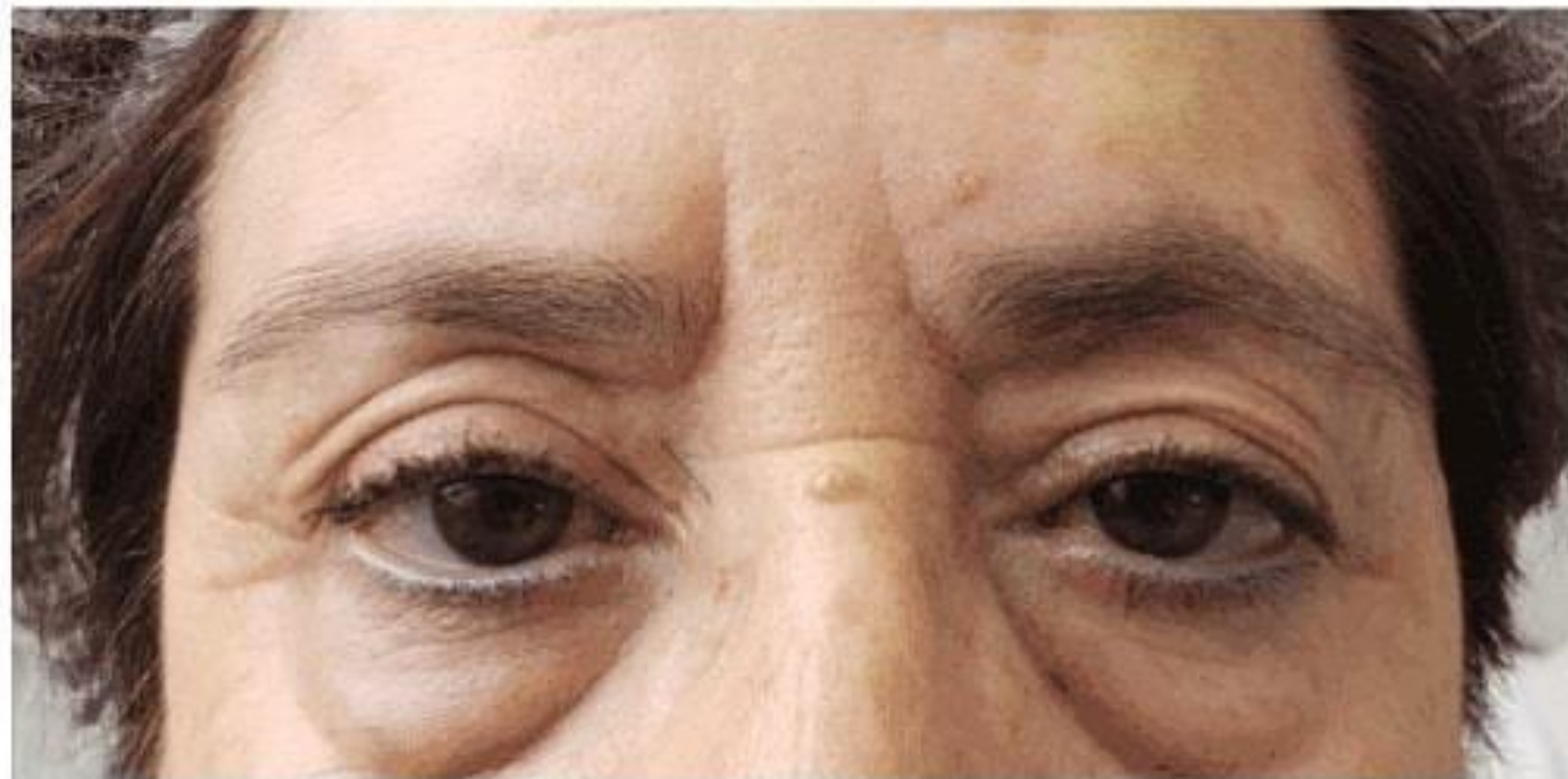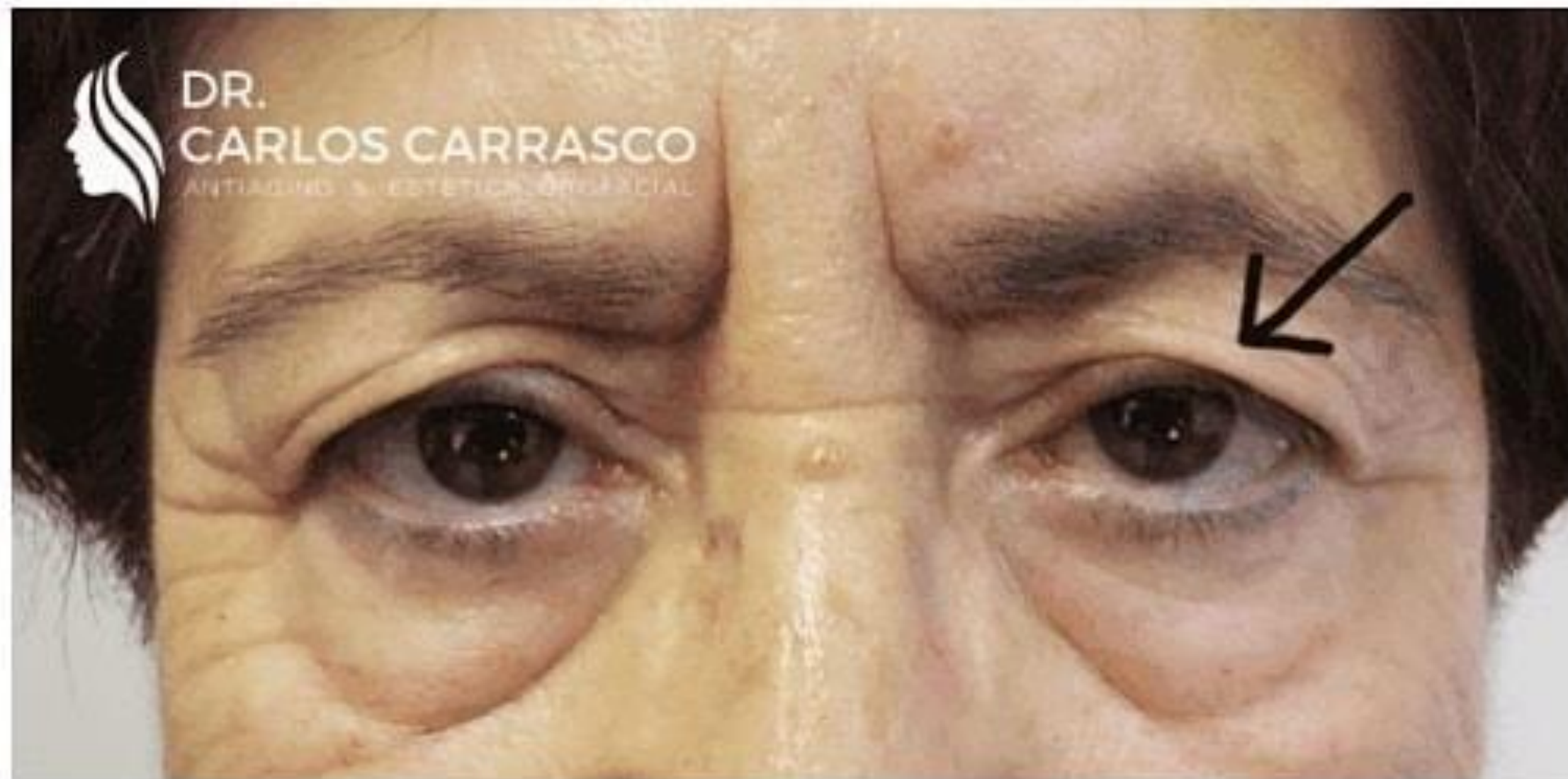- with the courtesy of Dr Shilan Barzinjy, Tel Aviv Israel
- before and after one month

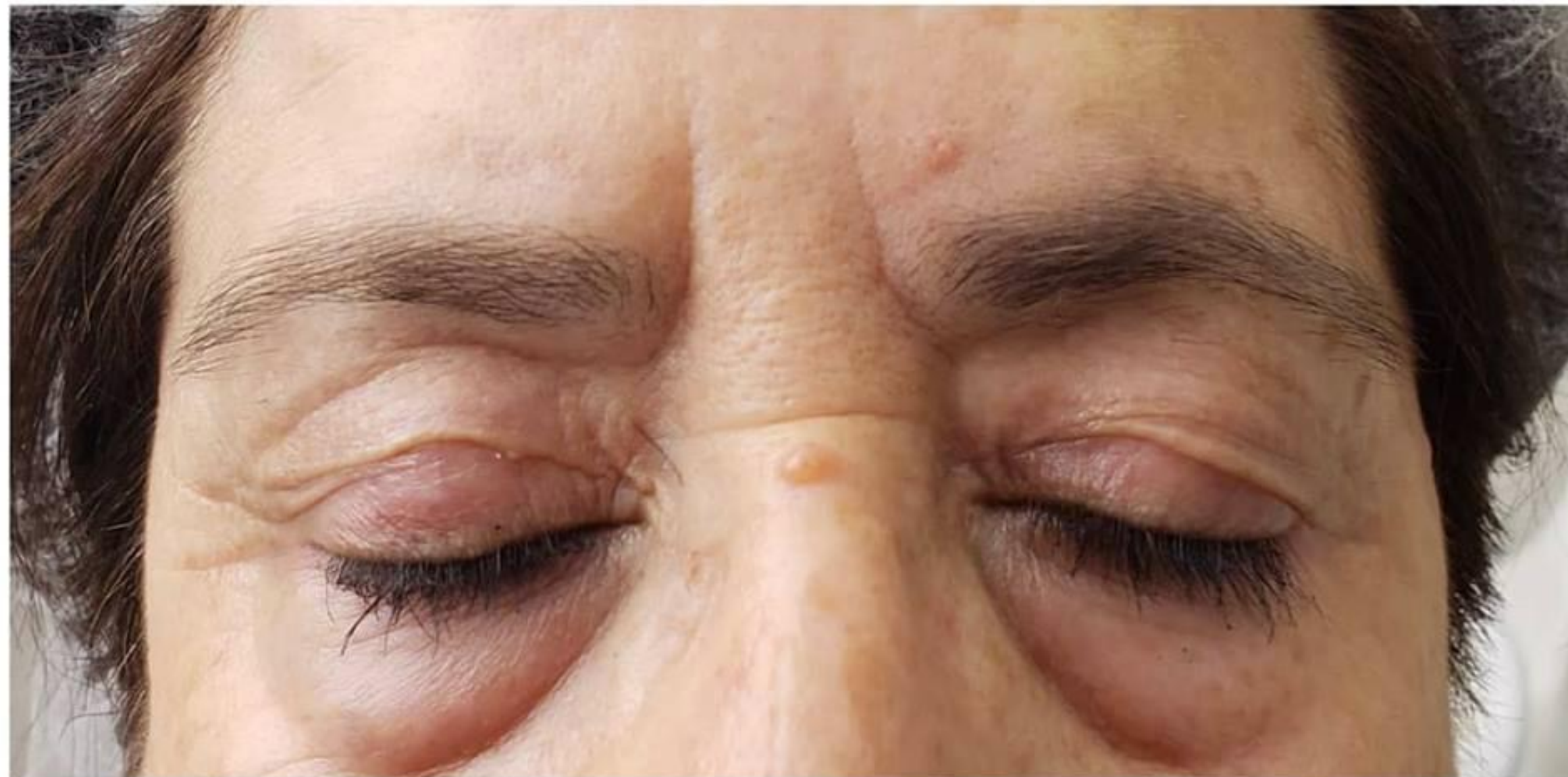
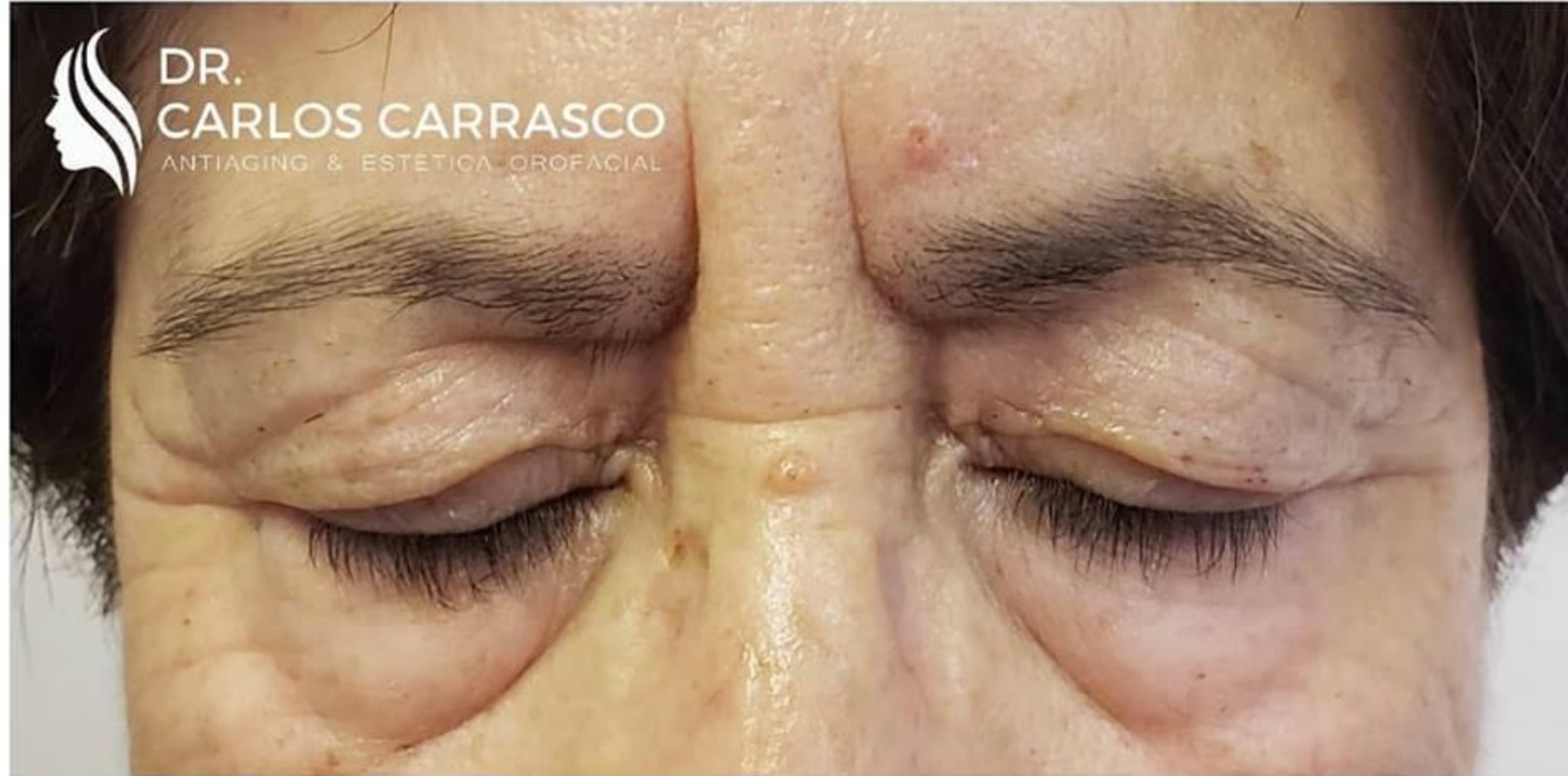
PLASMA[®]GE

Blefaroplasma[®]

- with the courtesy of Dr Carlos Carrascos, Santiago Chile
- before and after one month

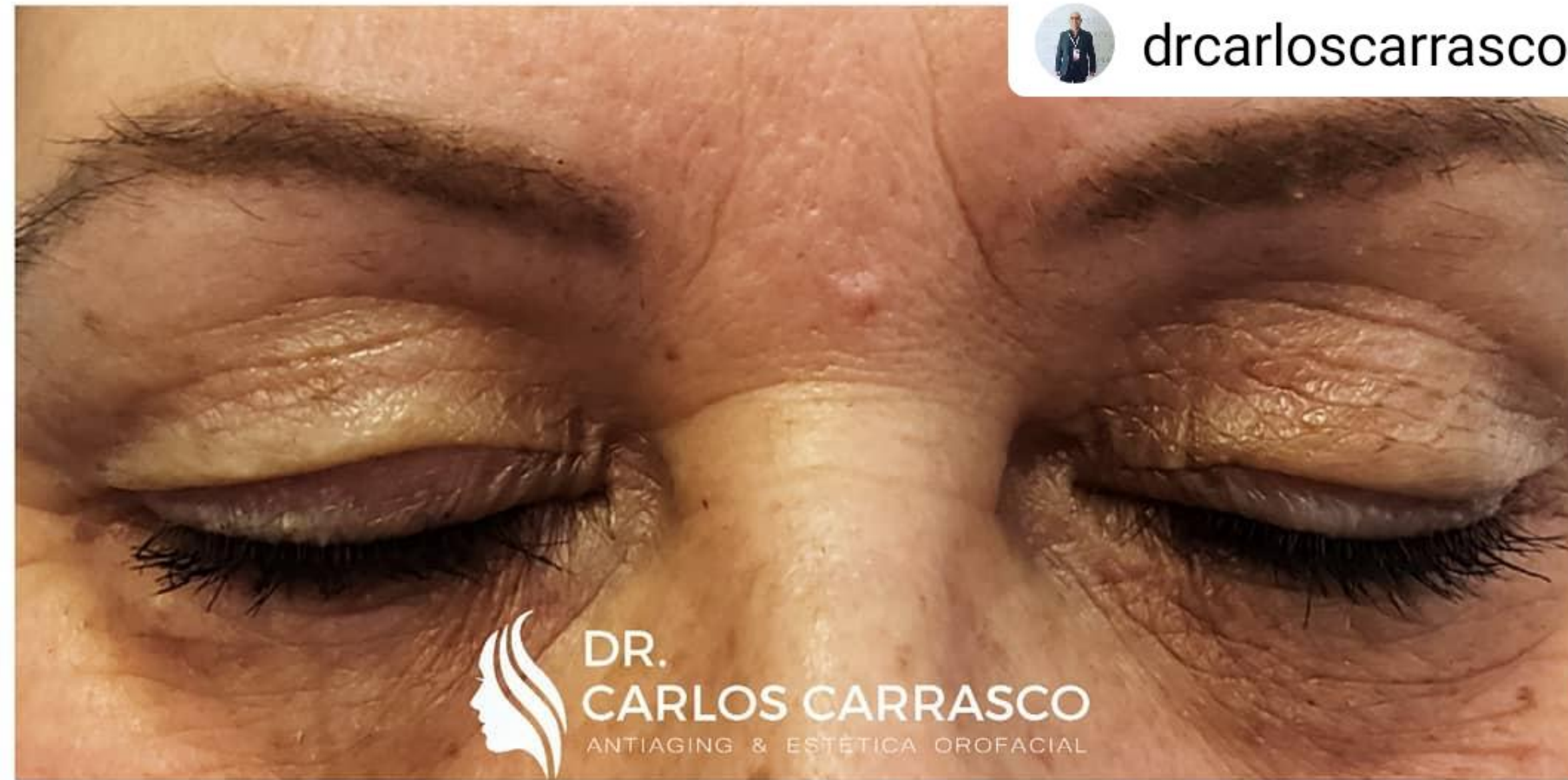



PLASMA[®]GE

Blefaroplasma[®]

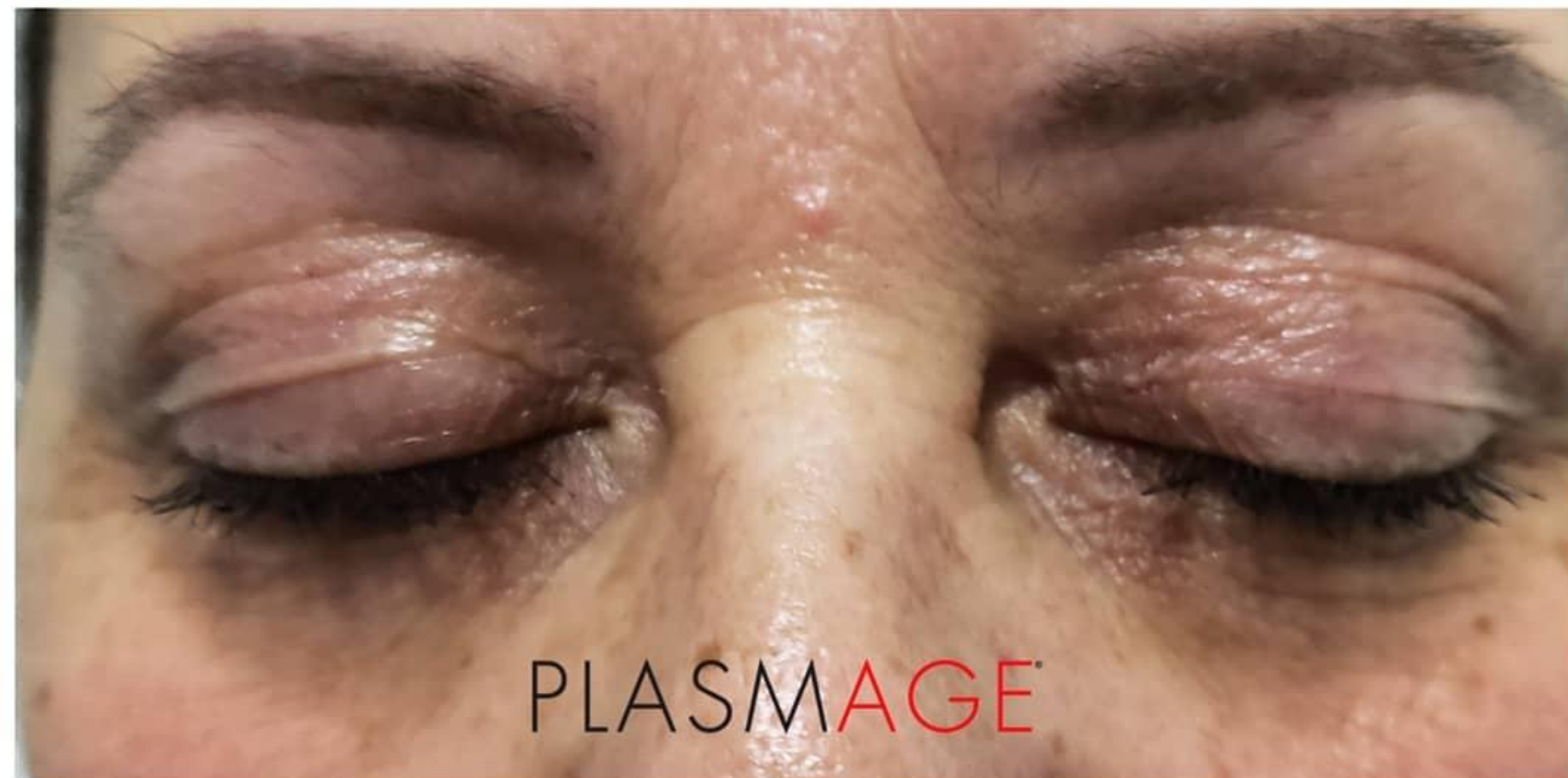- with the courtesy of Dr Carlos Carrascos, Santiago Chile
- before and after one month
- same patient

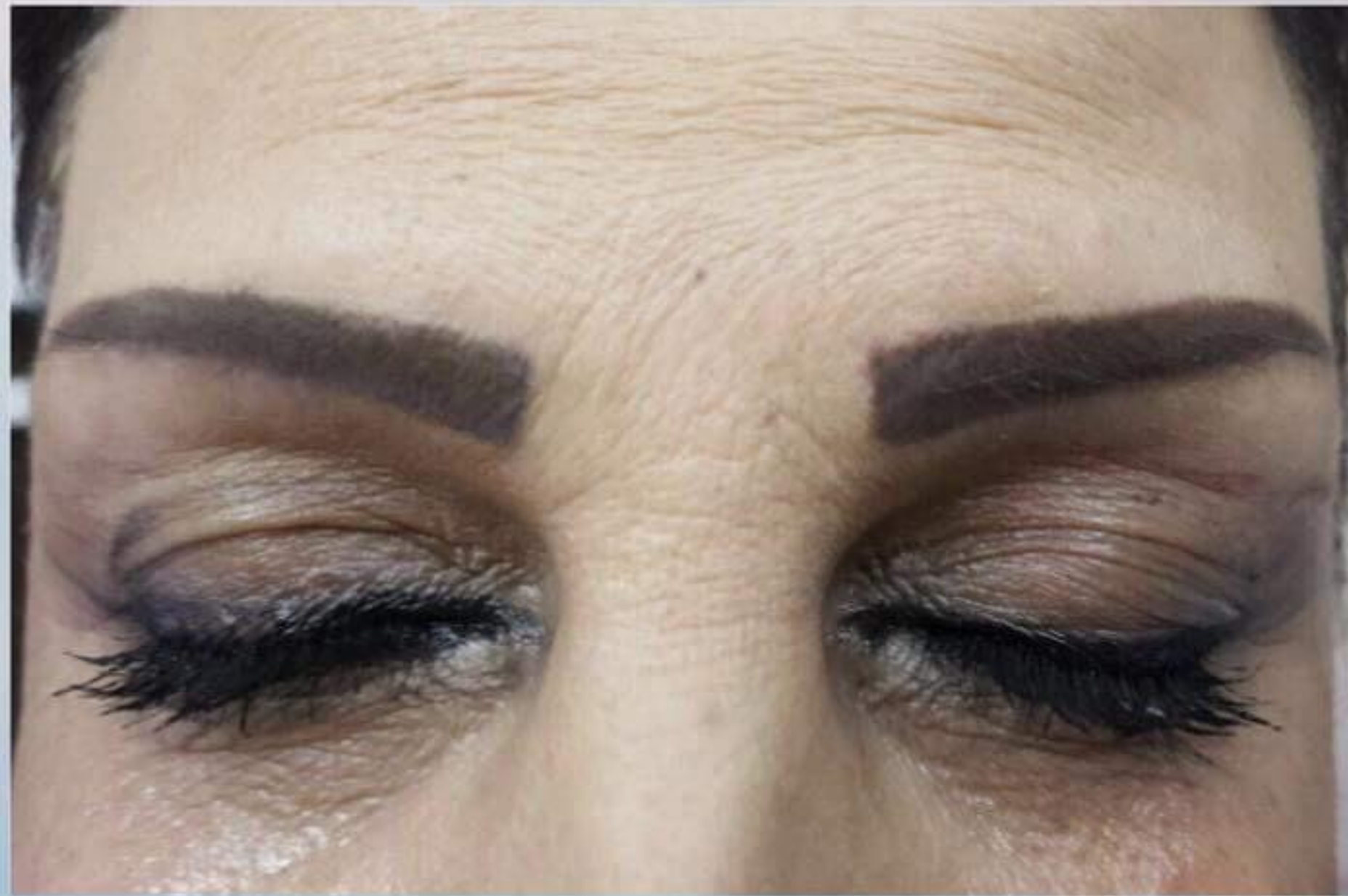

PLASMAGE®

Blefaroplastia®

- with the courtesy of Dr Carlos Carrascos, Santiago Chile
- before and after one month





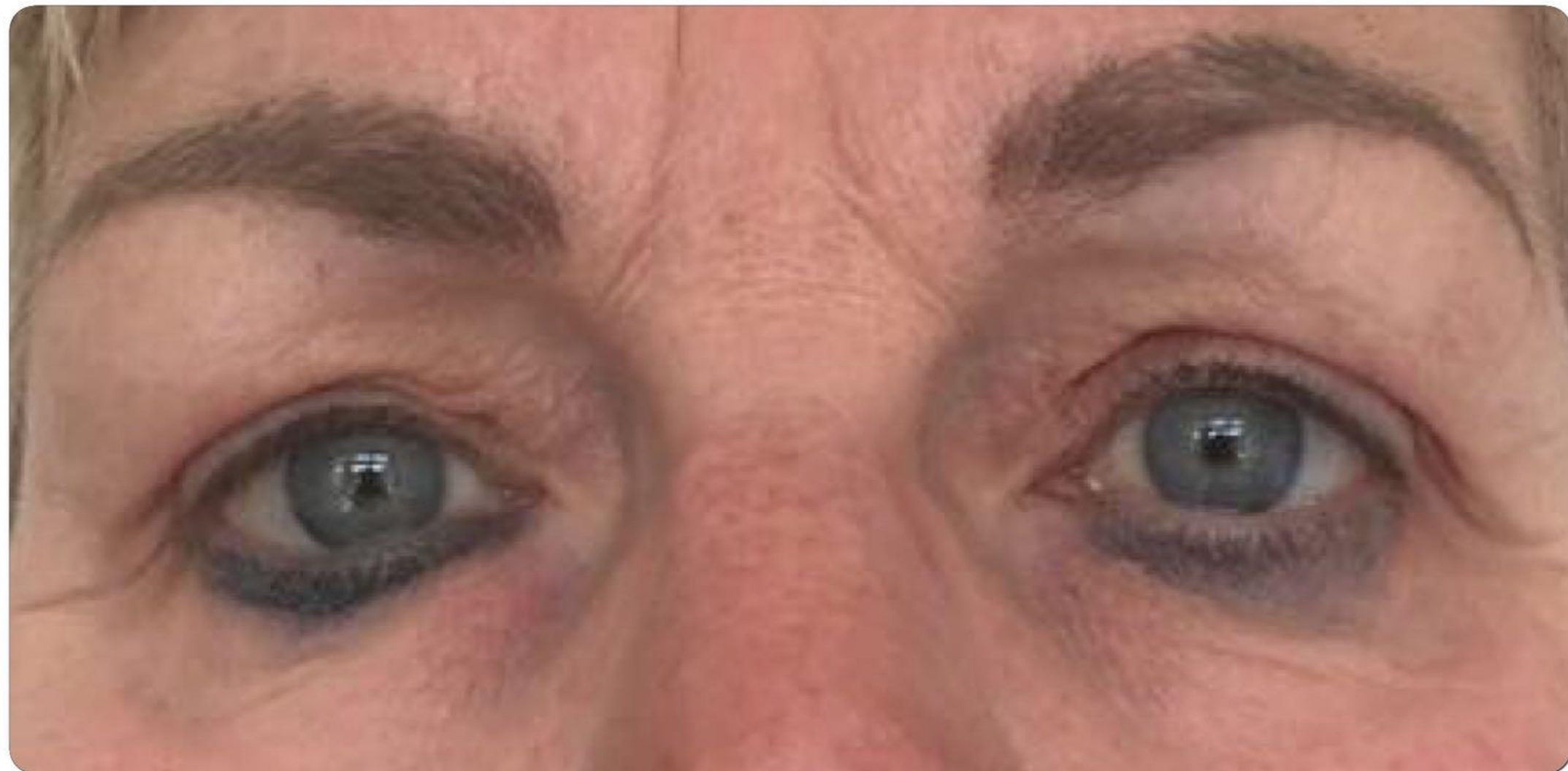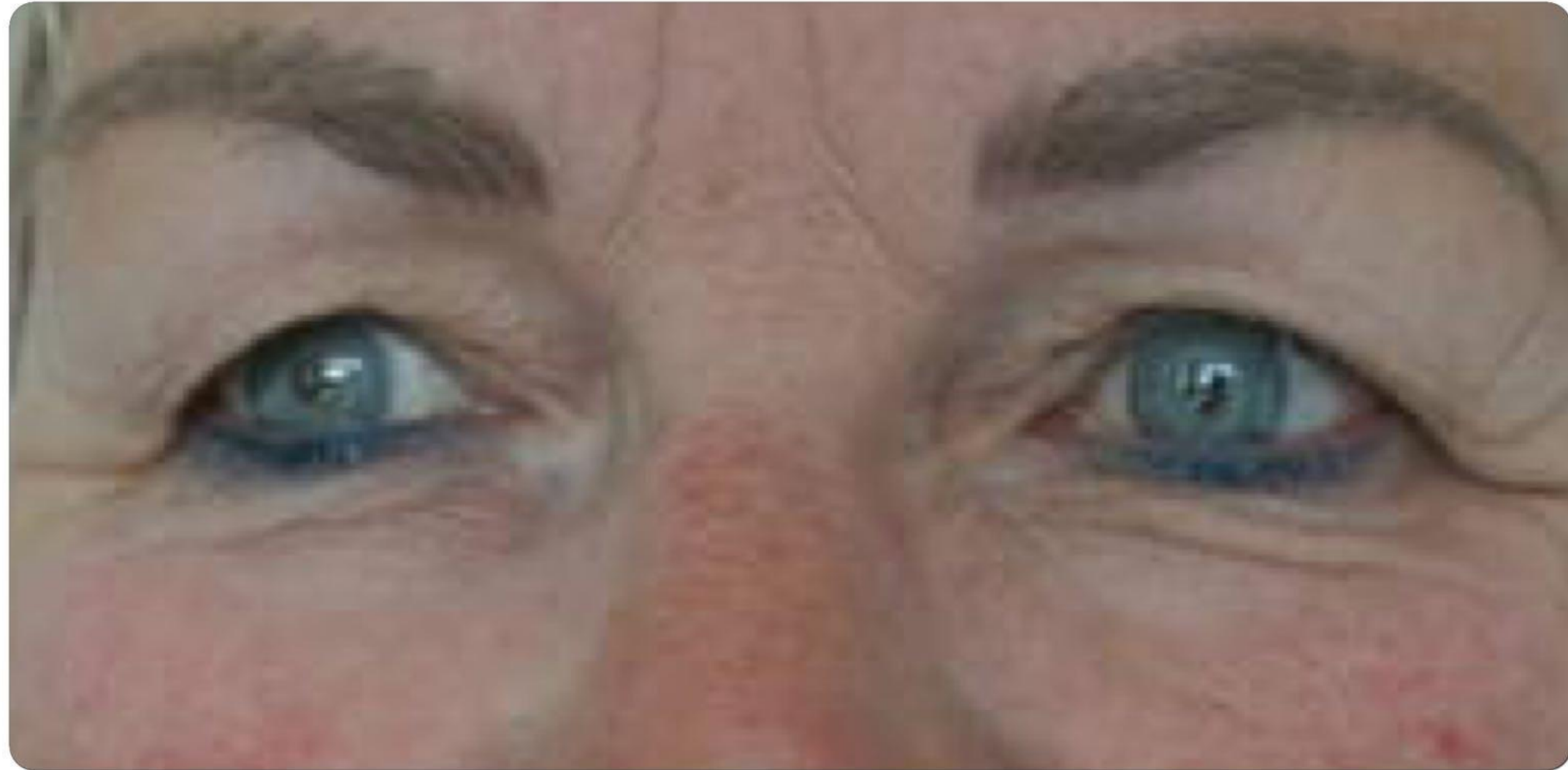PLASMA[®]

Blefaroplasma[®]

- with the courtesy of Dr Sennar Talabani, Kurdistan / Iraq
- before and 30 days after
- one session

PLASMA[®]GE

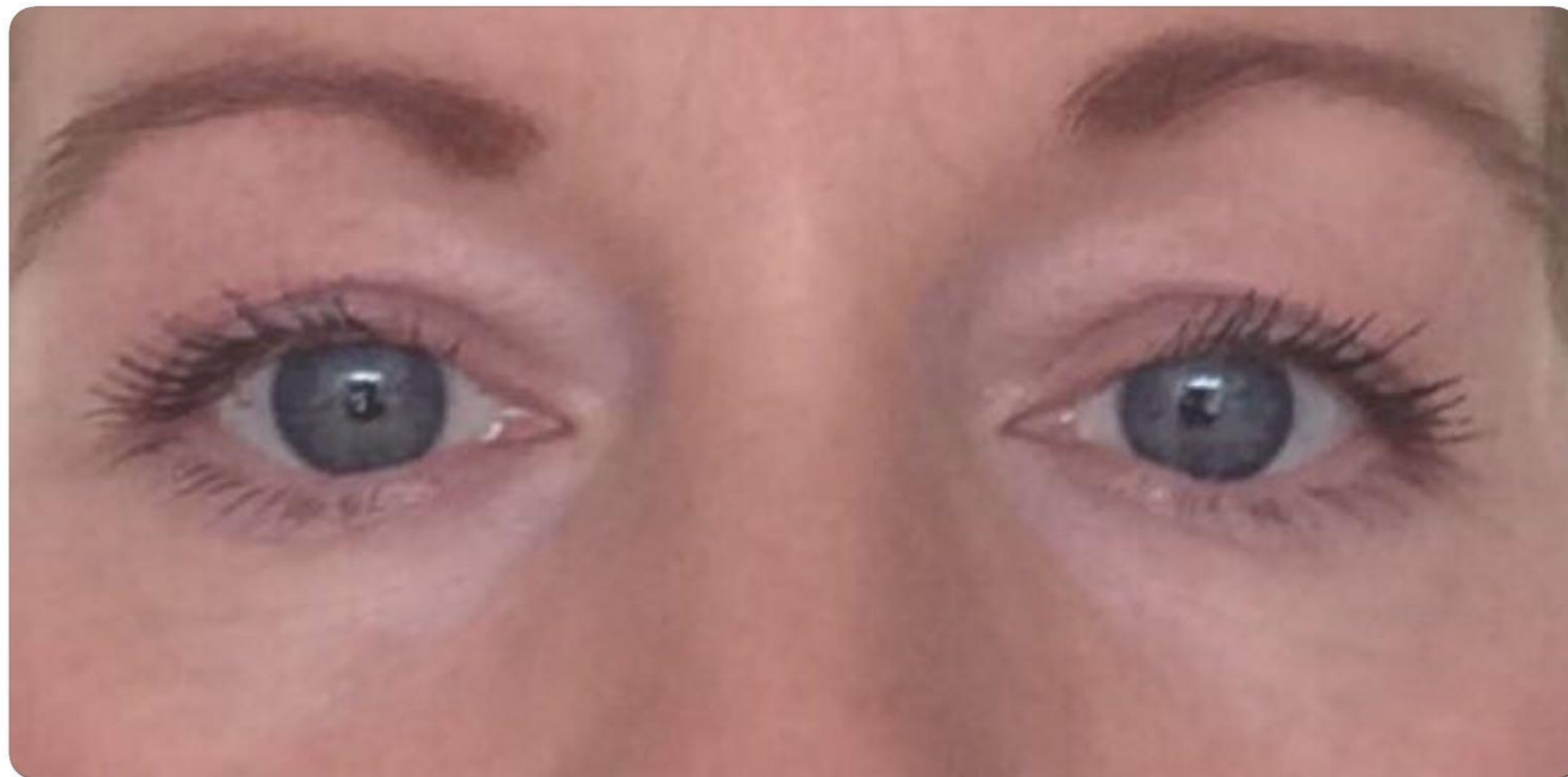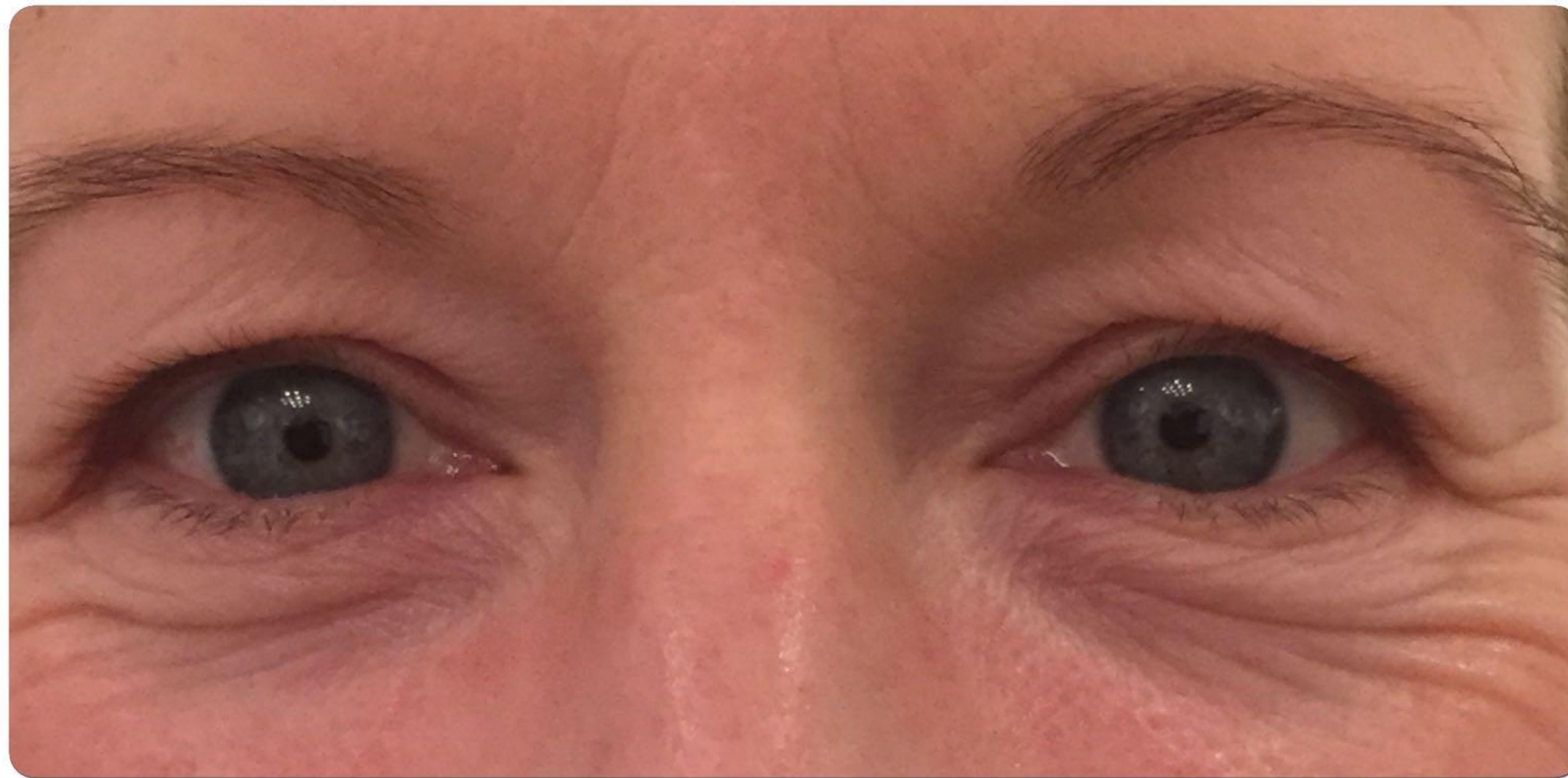Blefaroplastia[®]



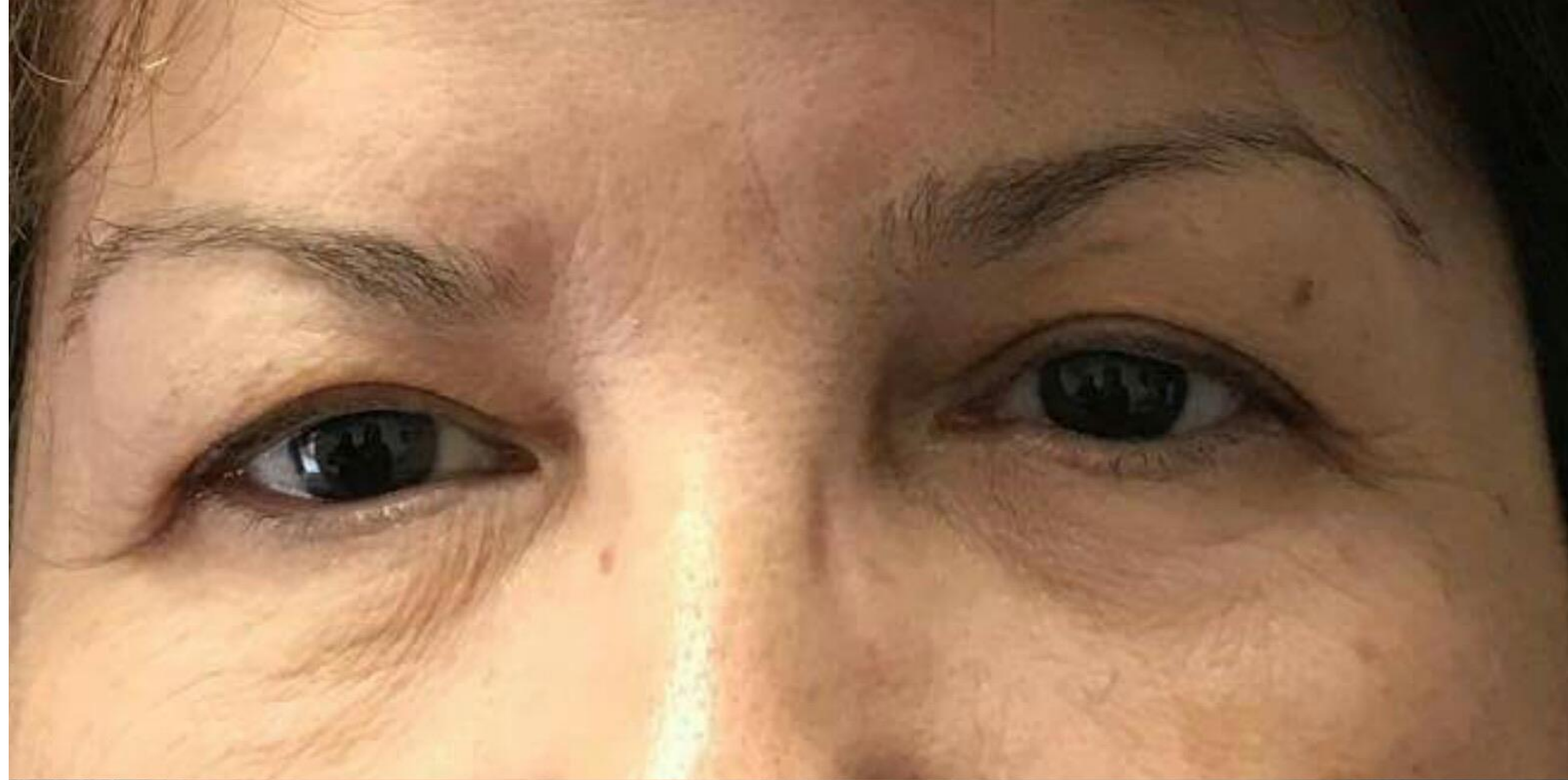- with the courtesy of Dr Tatjana Water, Obdan, The Netherlands
- before and 30 days after
- one session

PLASMA[®]

Blefaroplasma[®]



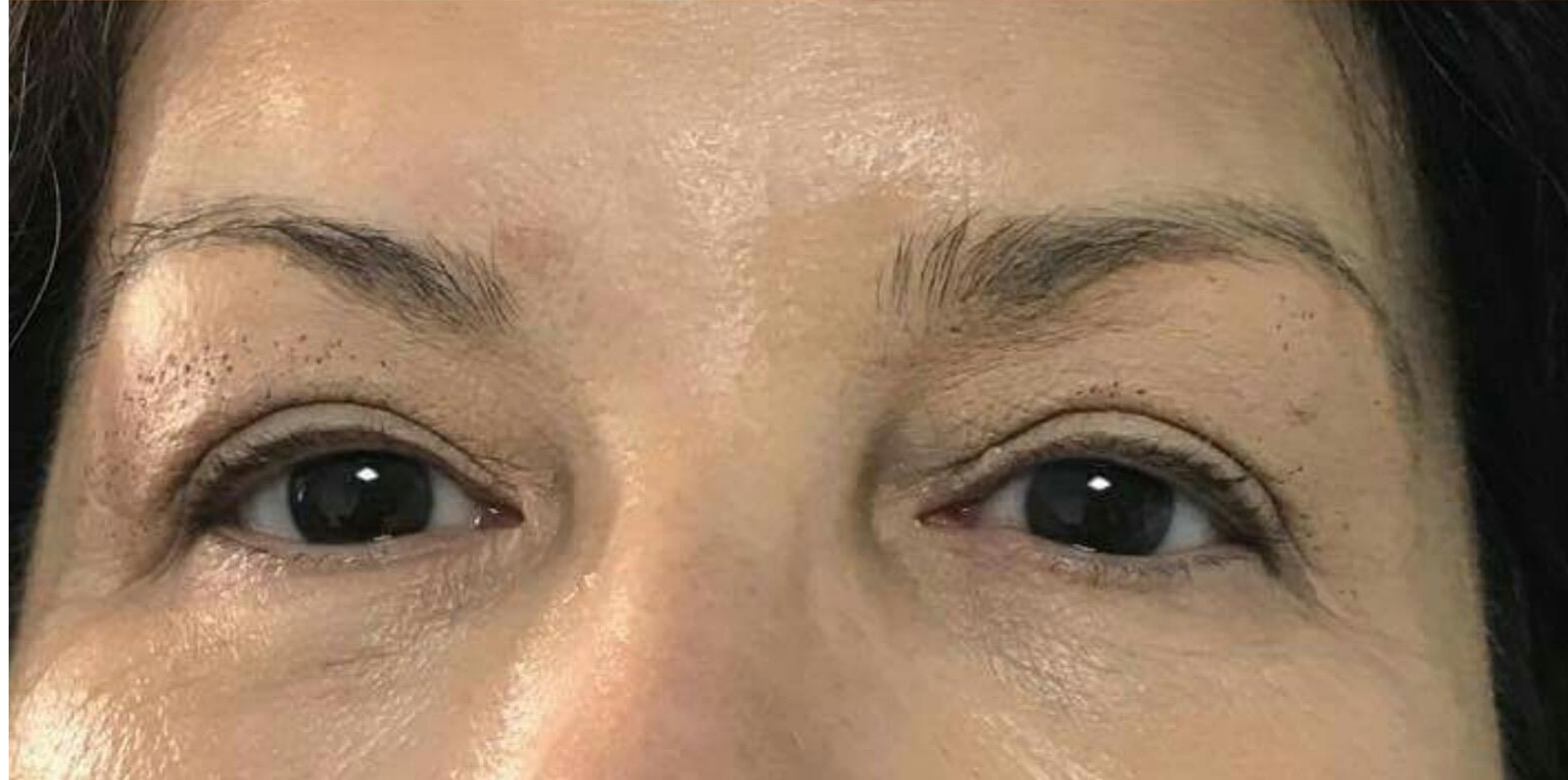- with the courtesy of Dr Tatjana Water, Obdan, The Netherlands
- before and and 30 days after
- one session



PLASMA[®]

Blefaroplasma[®]

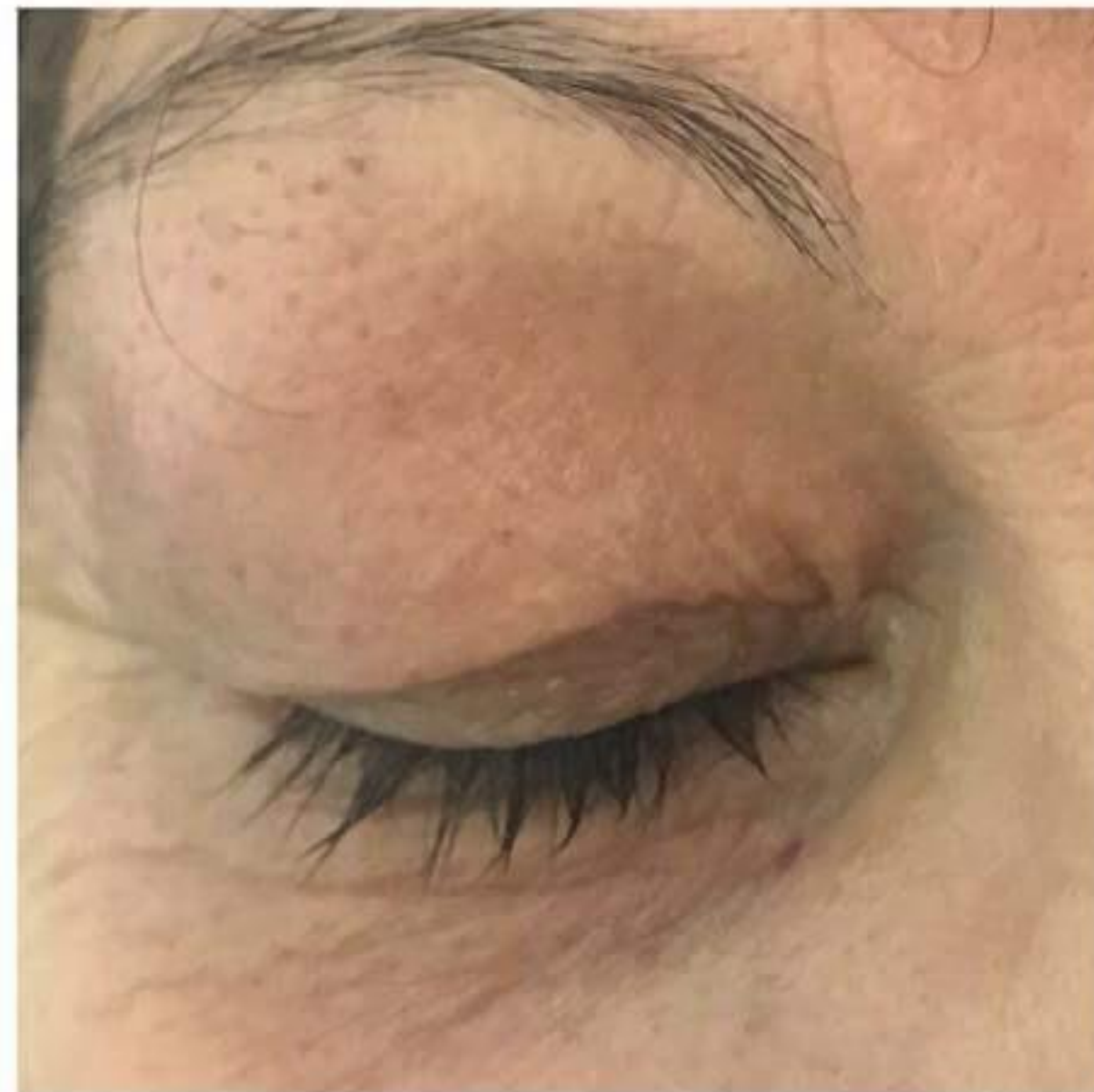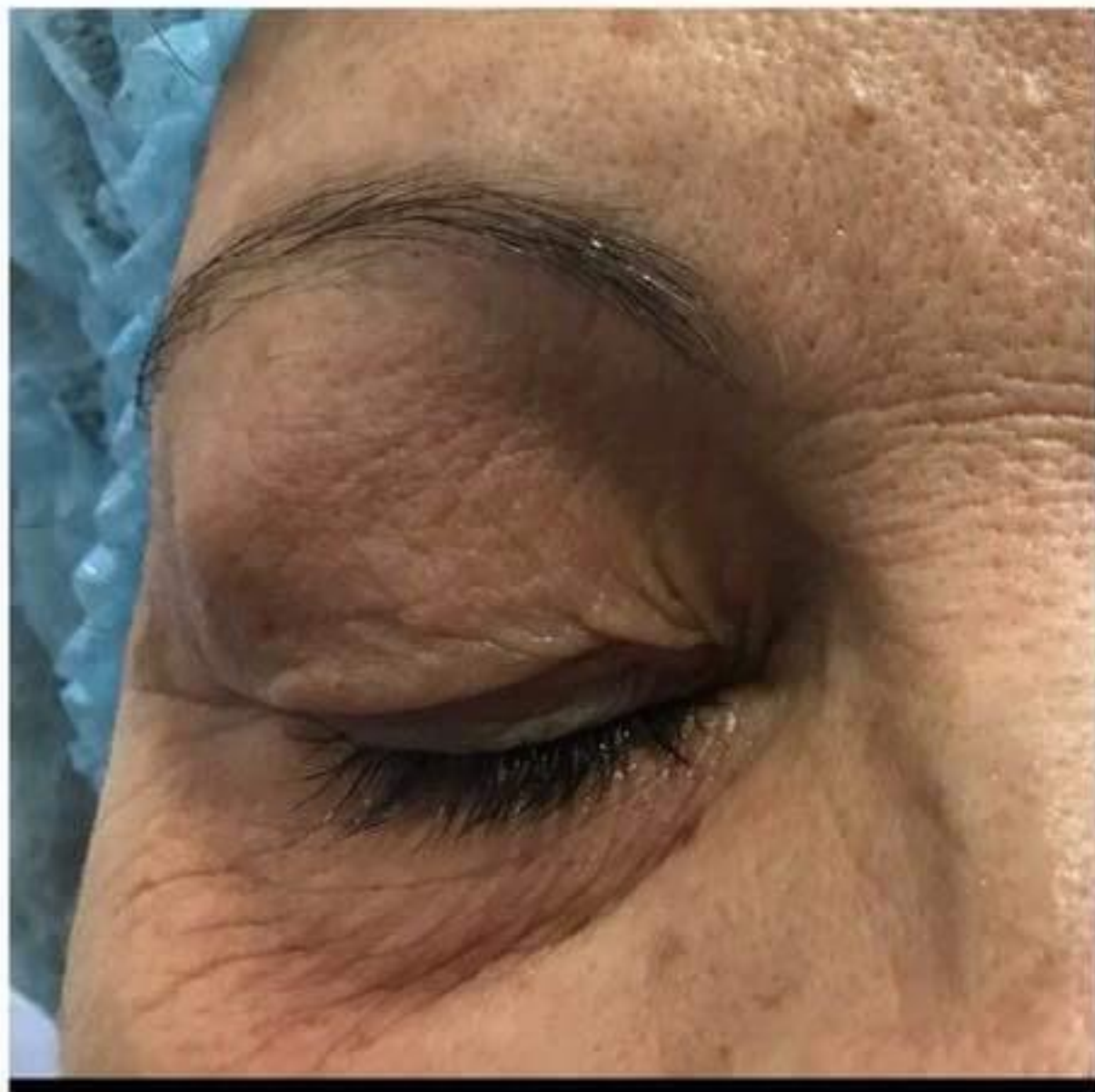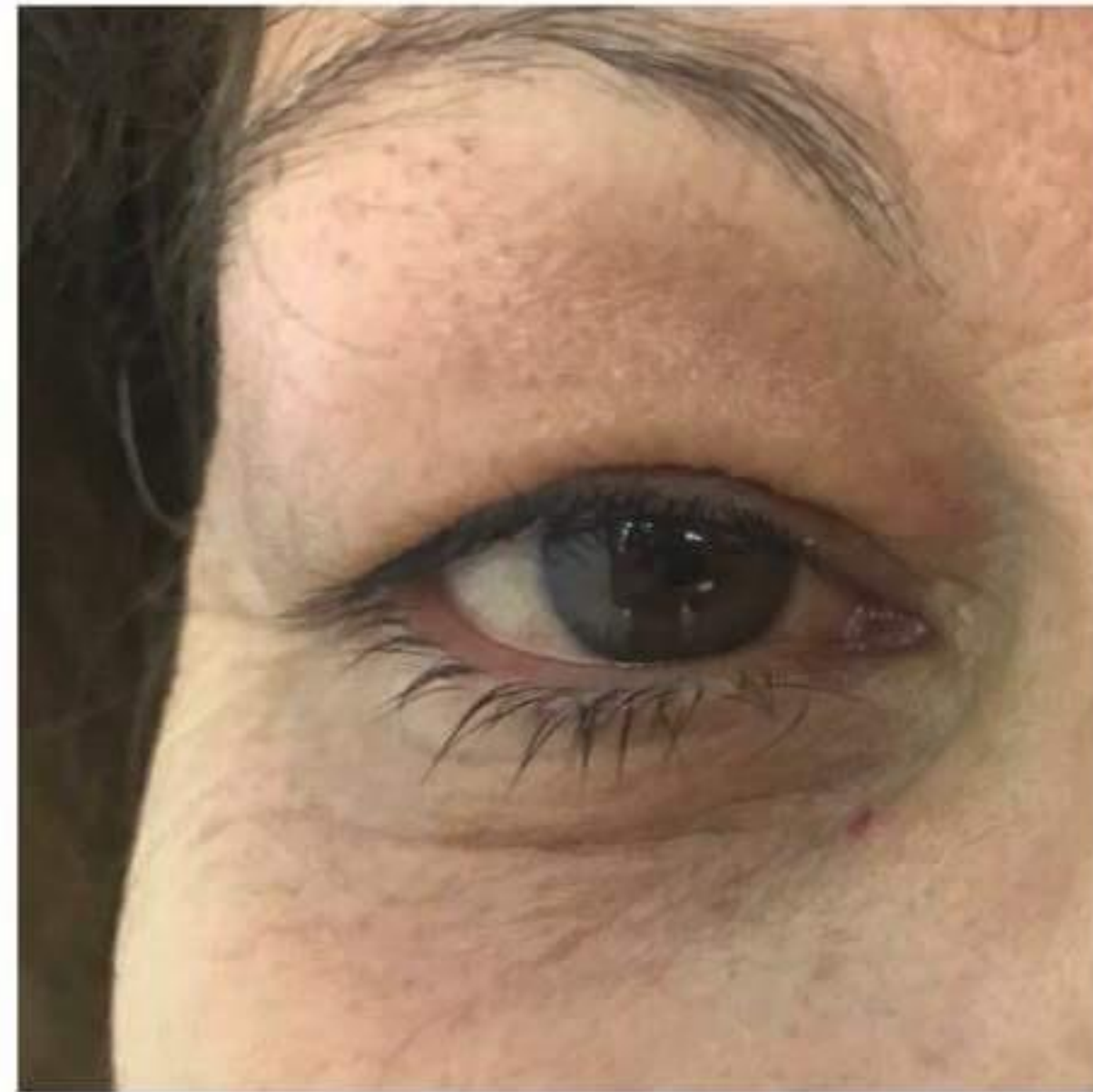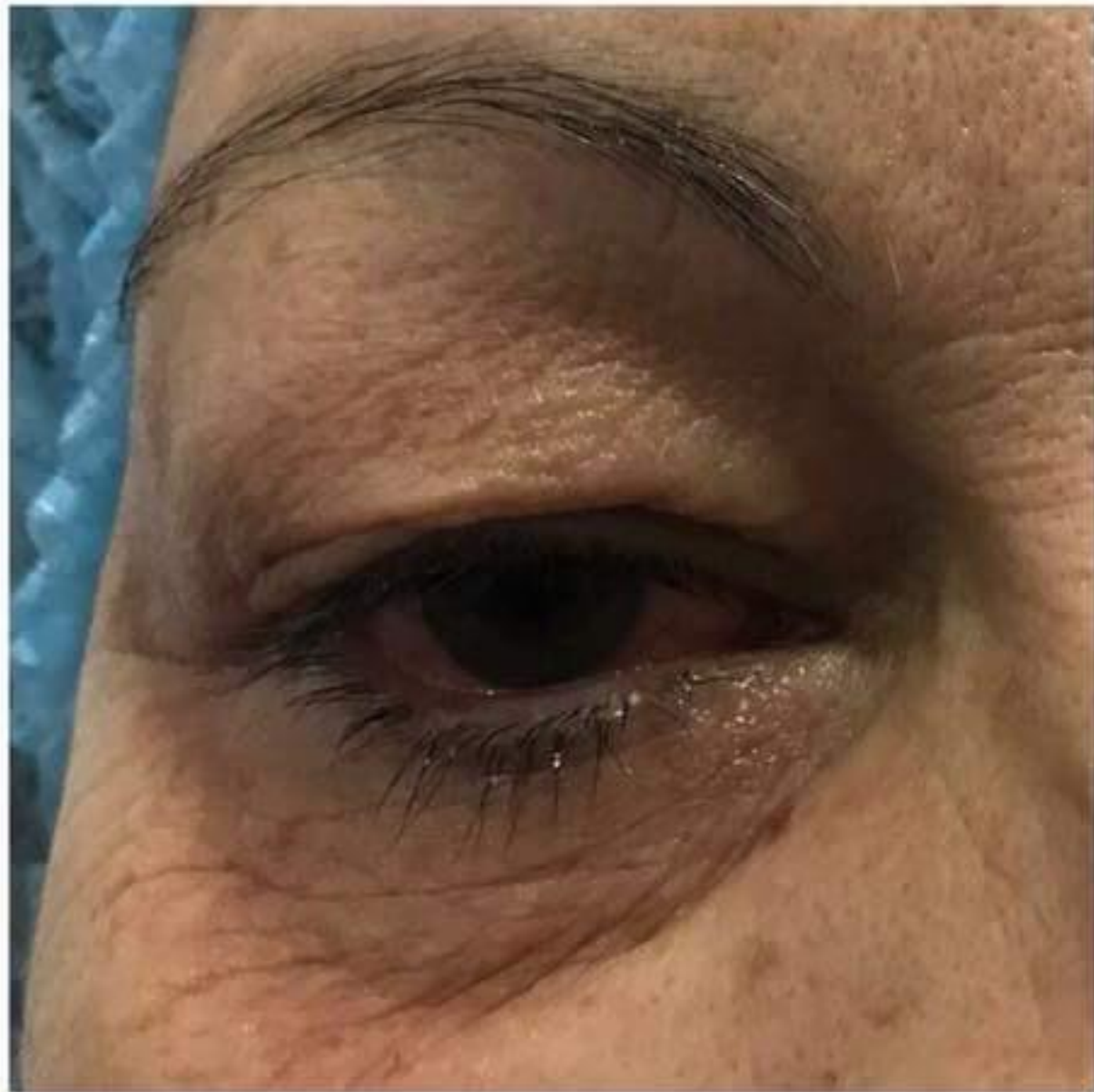- with the courtesy of Dr Eleftheria Gliarmi, Athens, Greece
- before and immediately after with foundation on the eyelids
- the application of mineral dermocosmetical foundation will isolate the skin

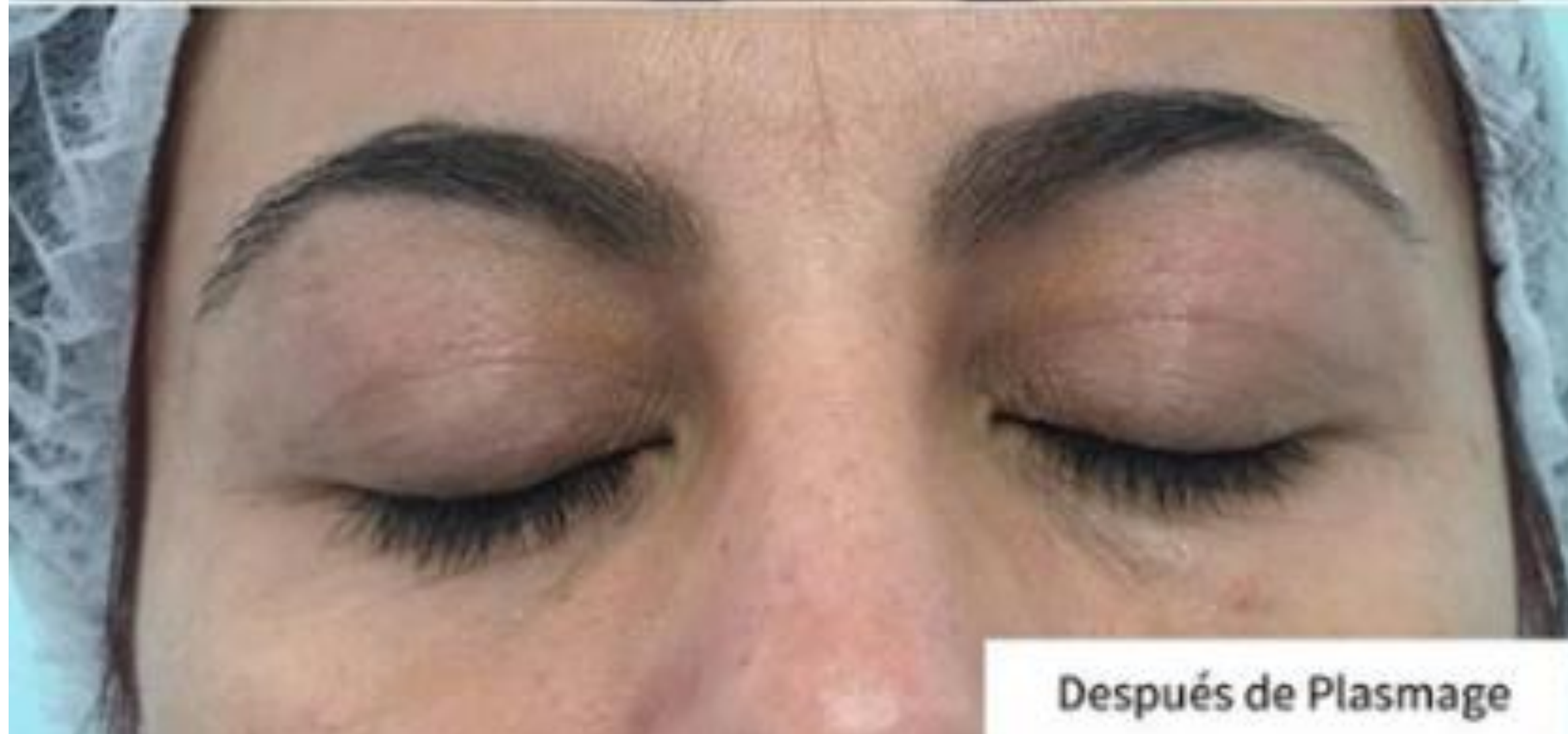
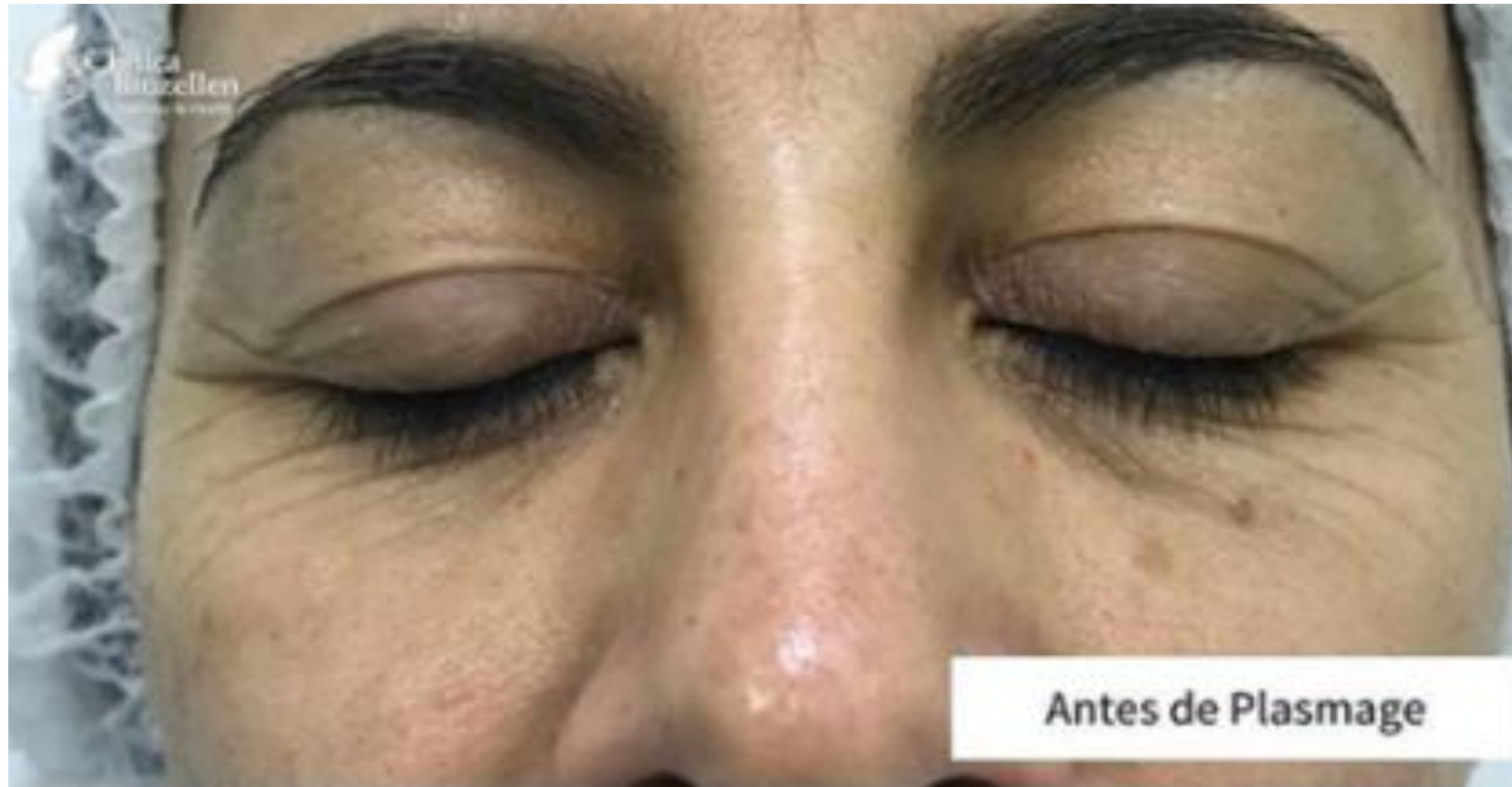
PLASMA[®]

Blefaroplasma[®]

- with the courtesy of Dr Shilan Barzinjy, Erbil Iraq
- 1 session: before and after 1 month

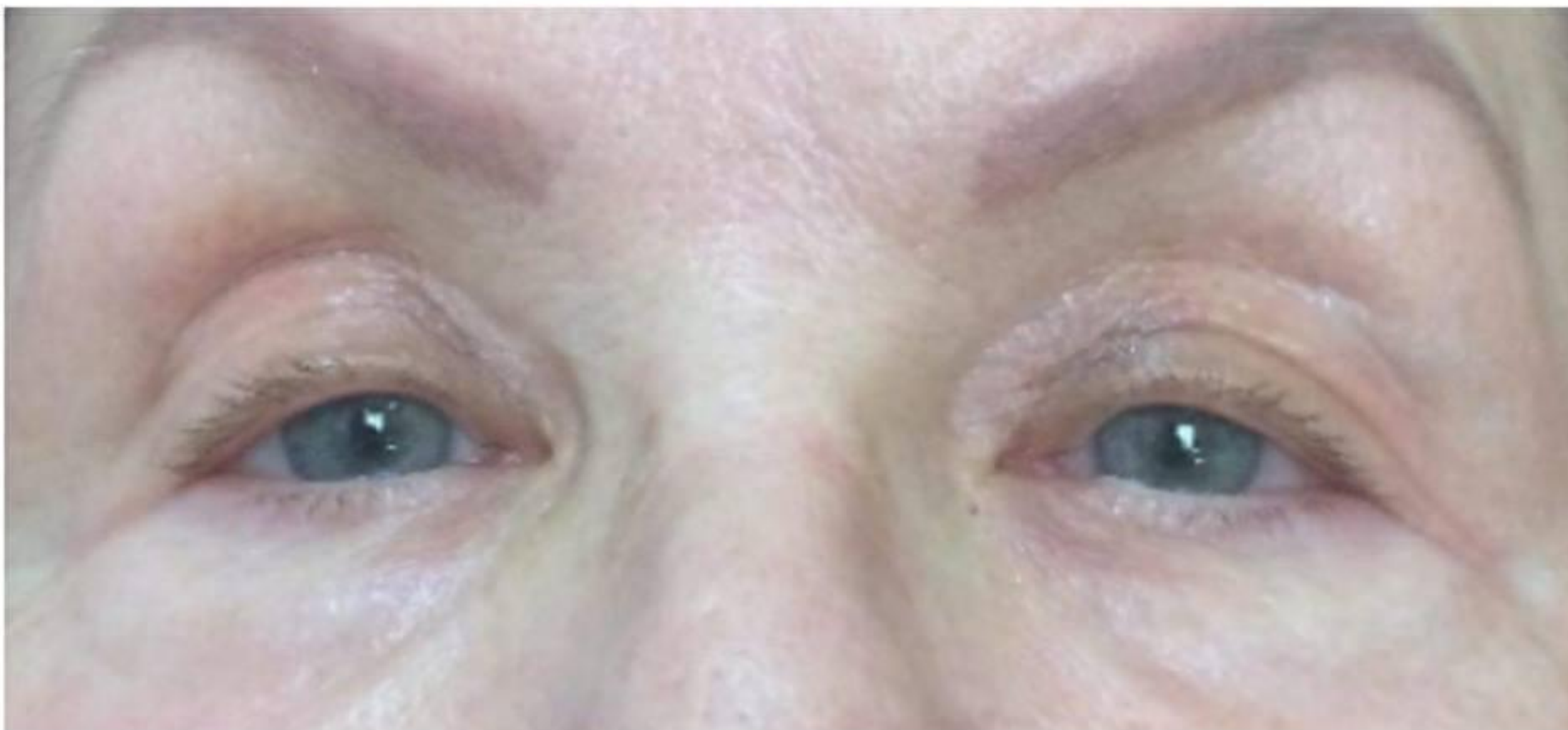
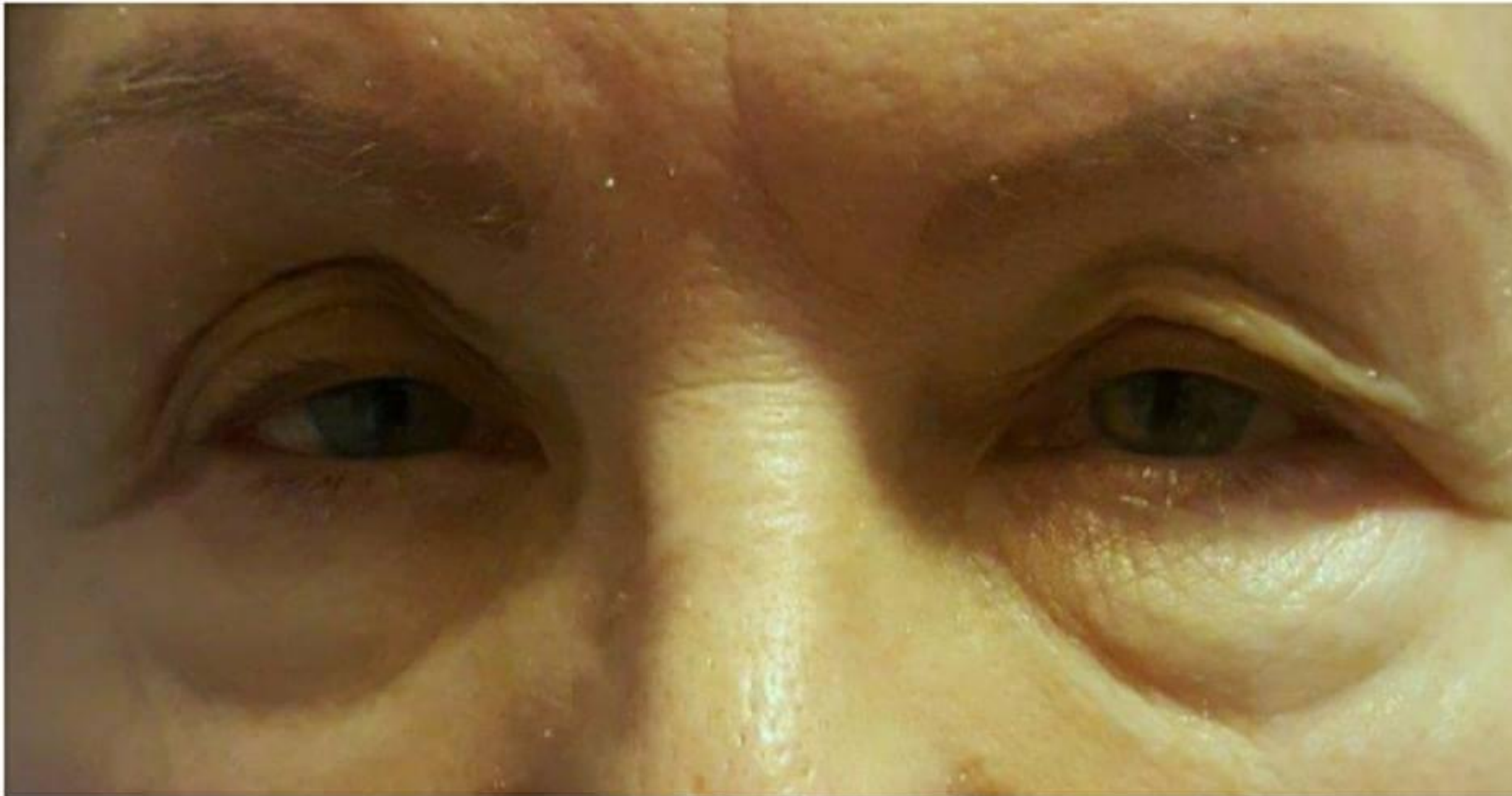


PLASMAGE®

Blefaroplasma®

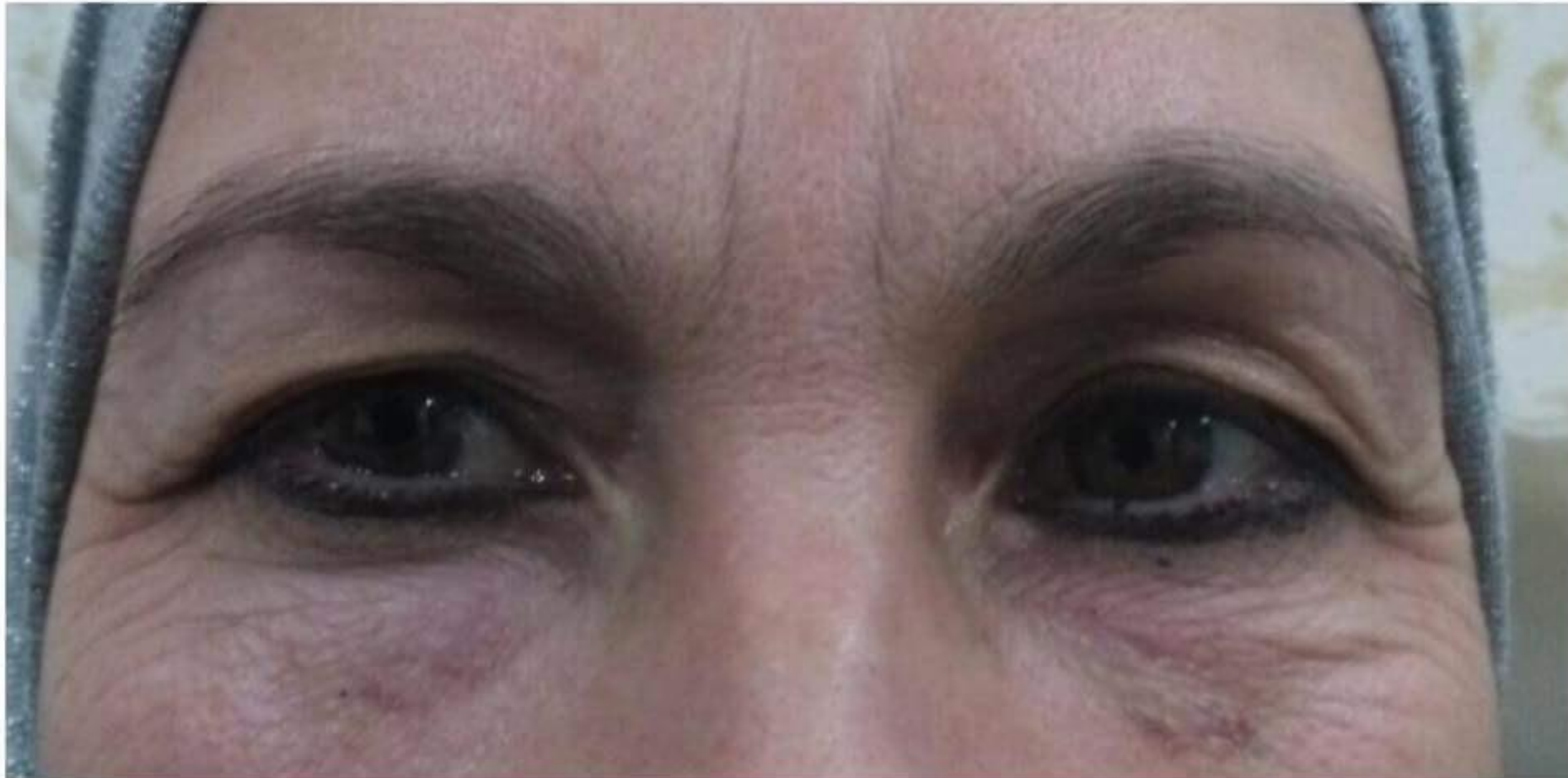- with the courtesy of Dr Jorge Riviera, Santiago Chile
- 1 session: before and after 1 month



PLASMA[®]GE

Blefaroplasma[®]

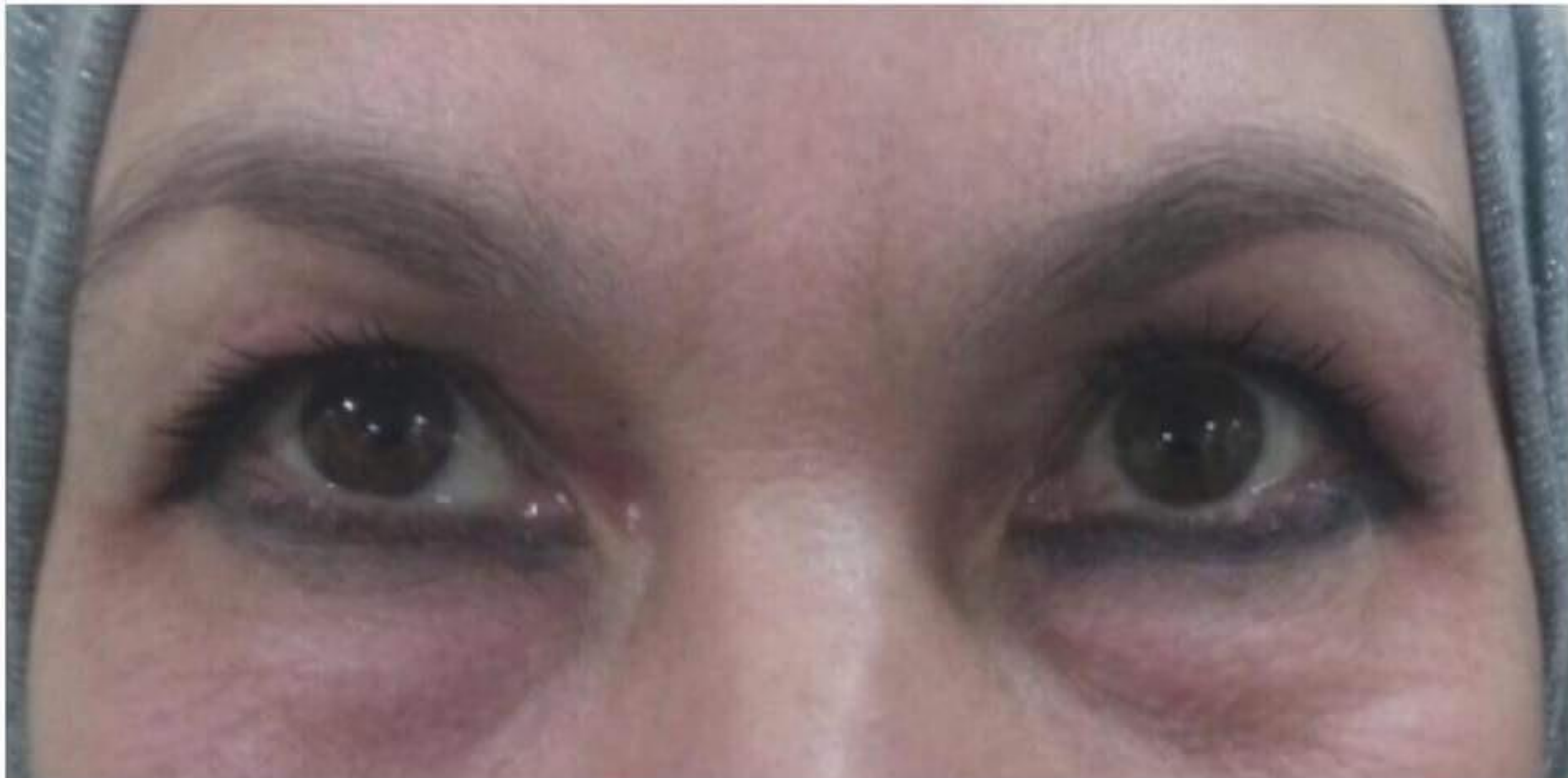- with the courtesy of Oxygen, Tbilissi Georgia
- 1 session: before and after 1 month

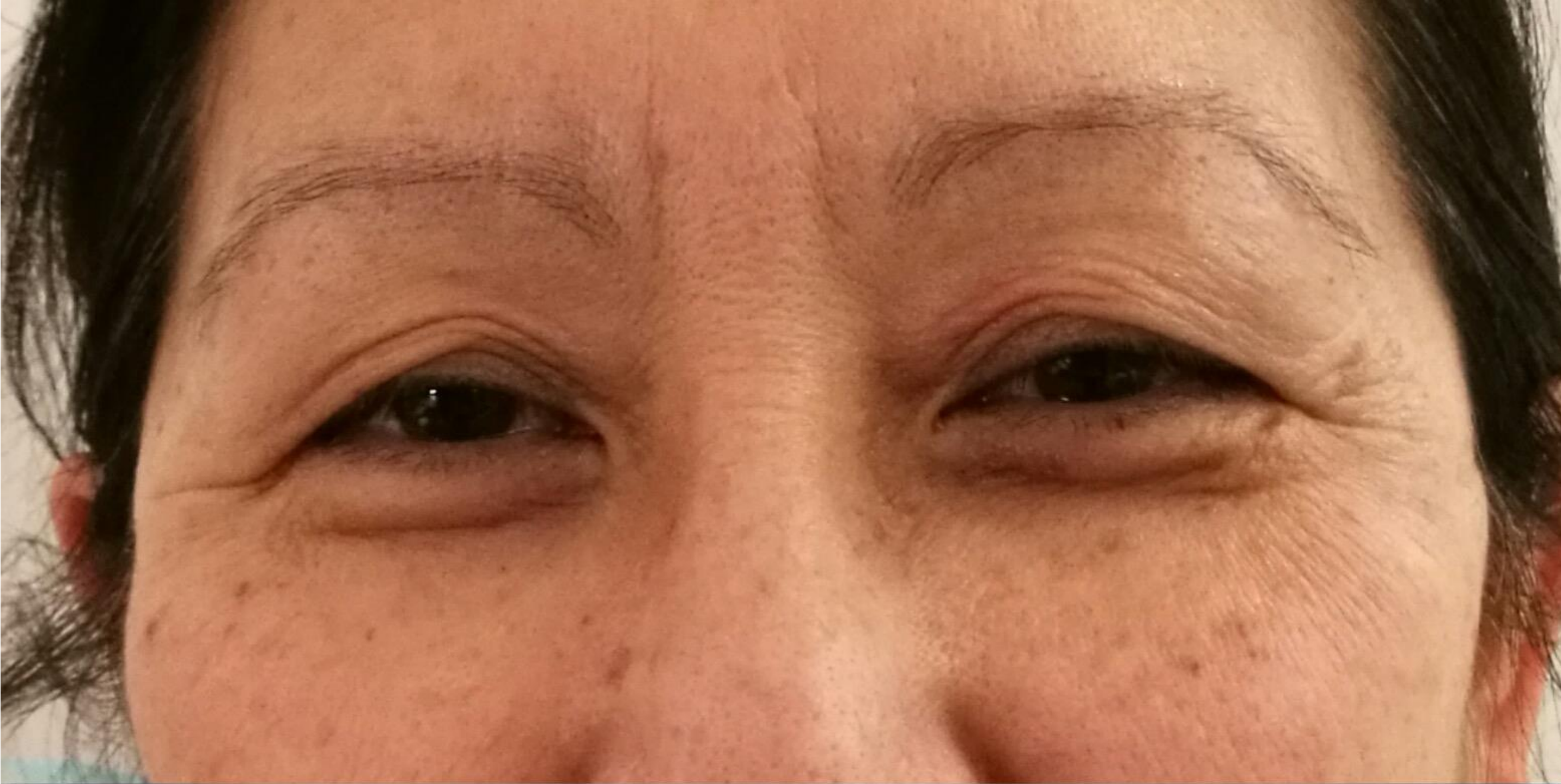

PLASMA[®]GE

Blefaroplastia[®]

- with the courtesy of Stressa Healthcare Egypt
- before and after one month
- one session

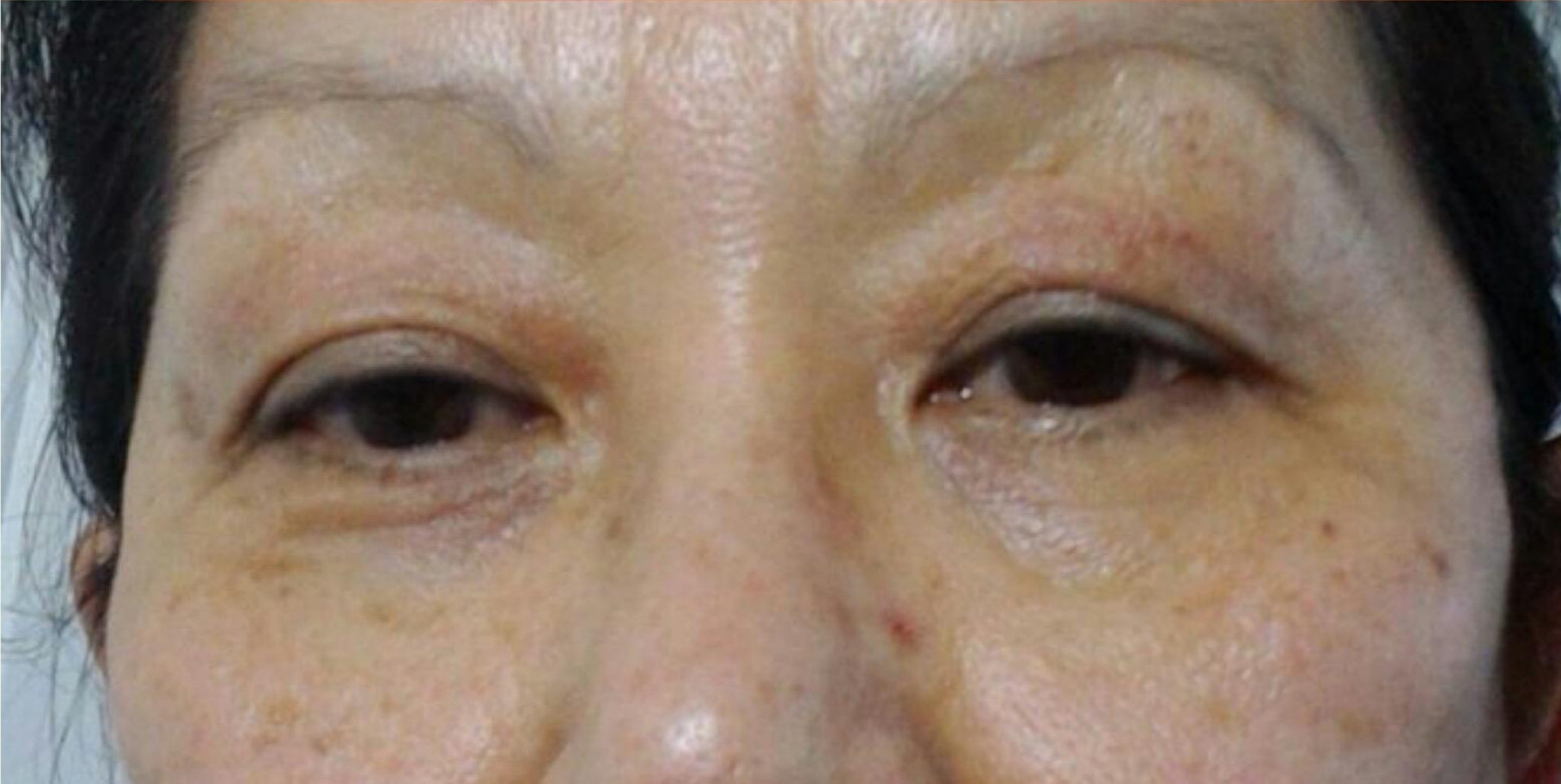


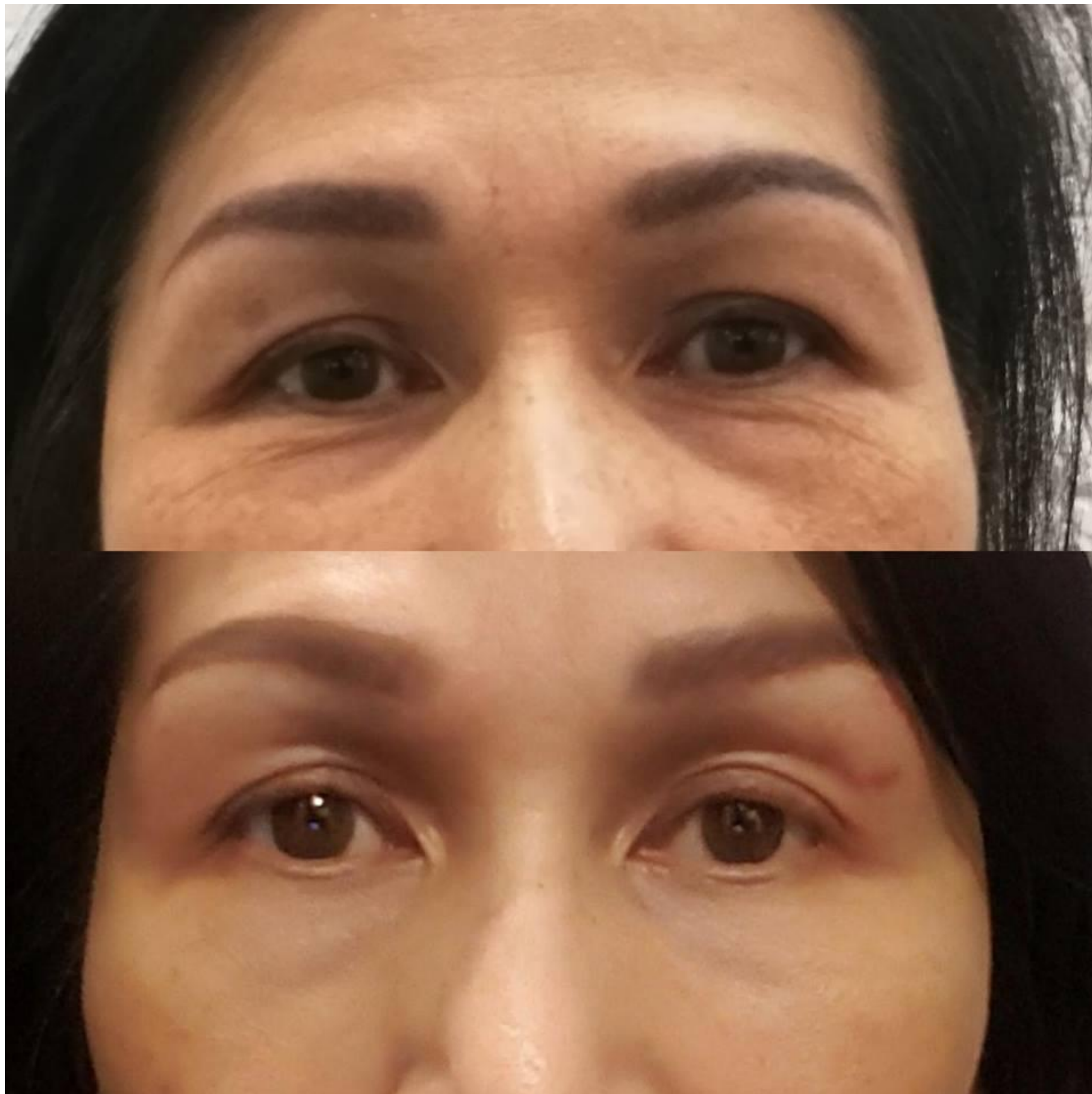
PLASMA[®]GE

Blefaroplasma[®]

- with the courtesy of Dr Jacques André David, Paris France
- before and after 2 weeks
- one session

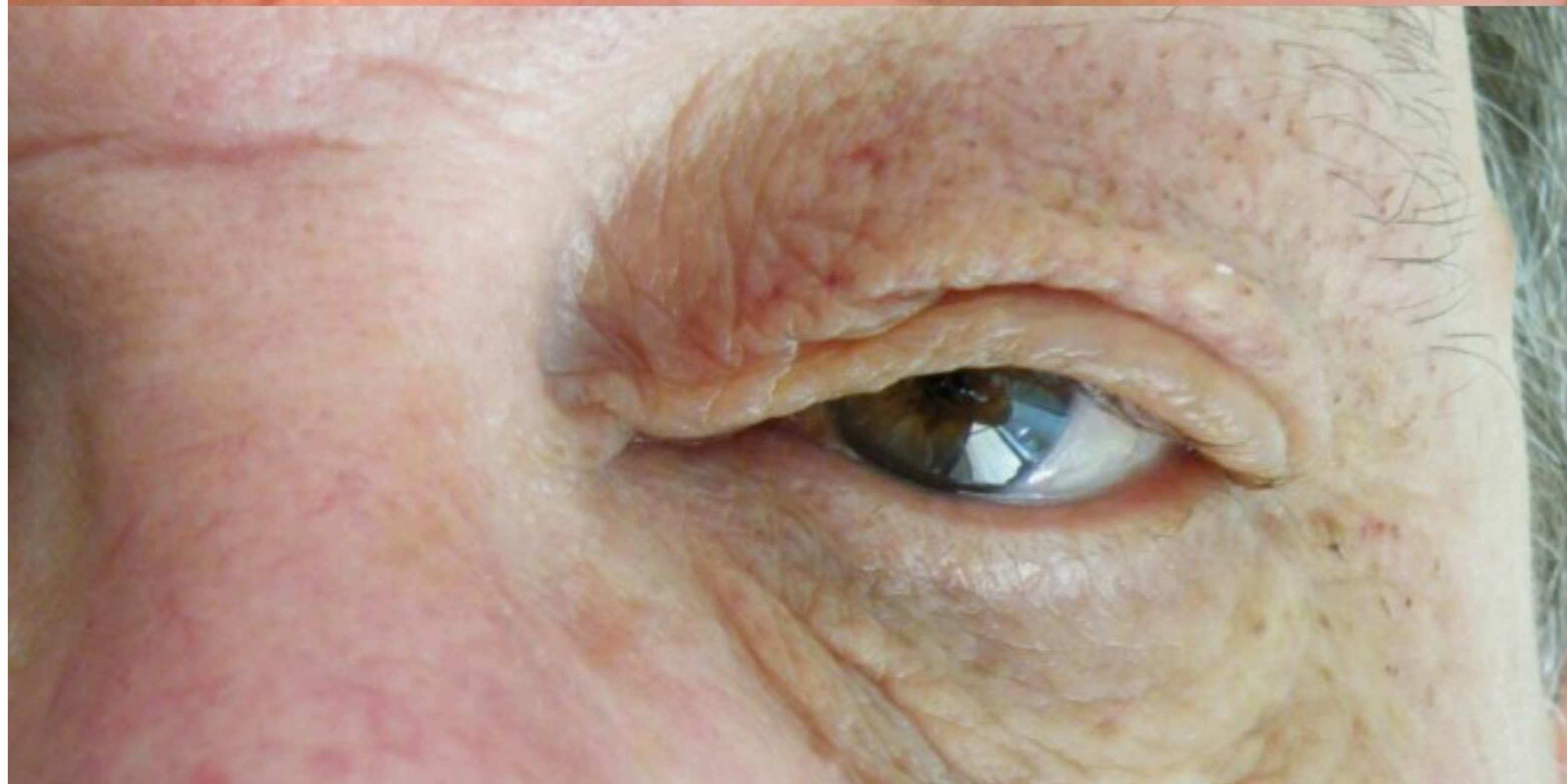
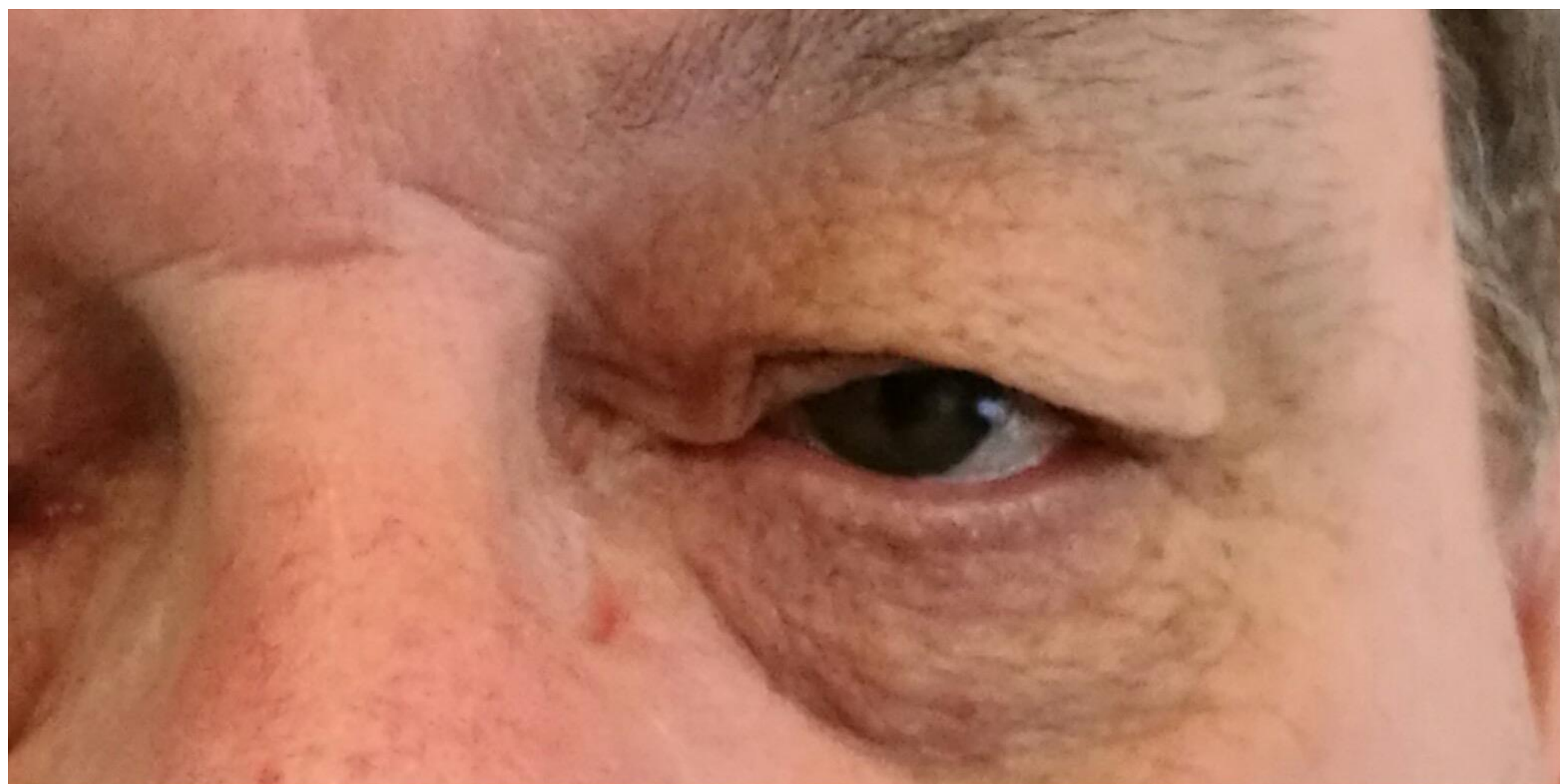


PLASMA[®]GE

Blefaroplastia[®]

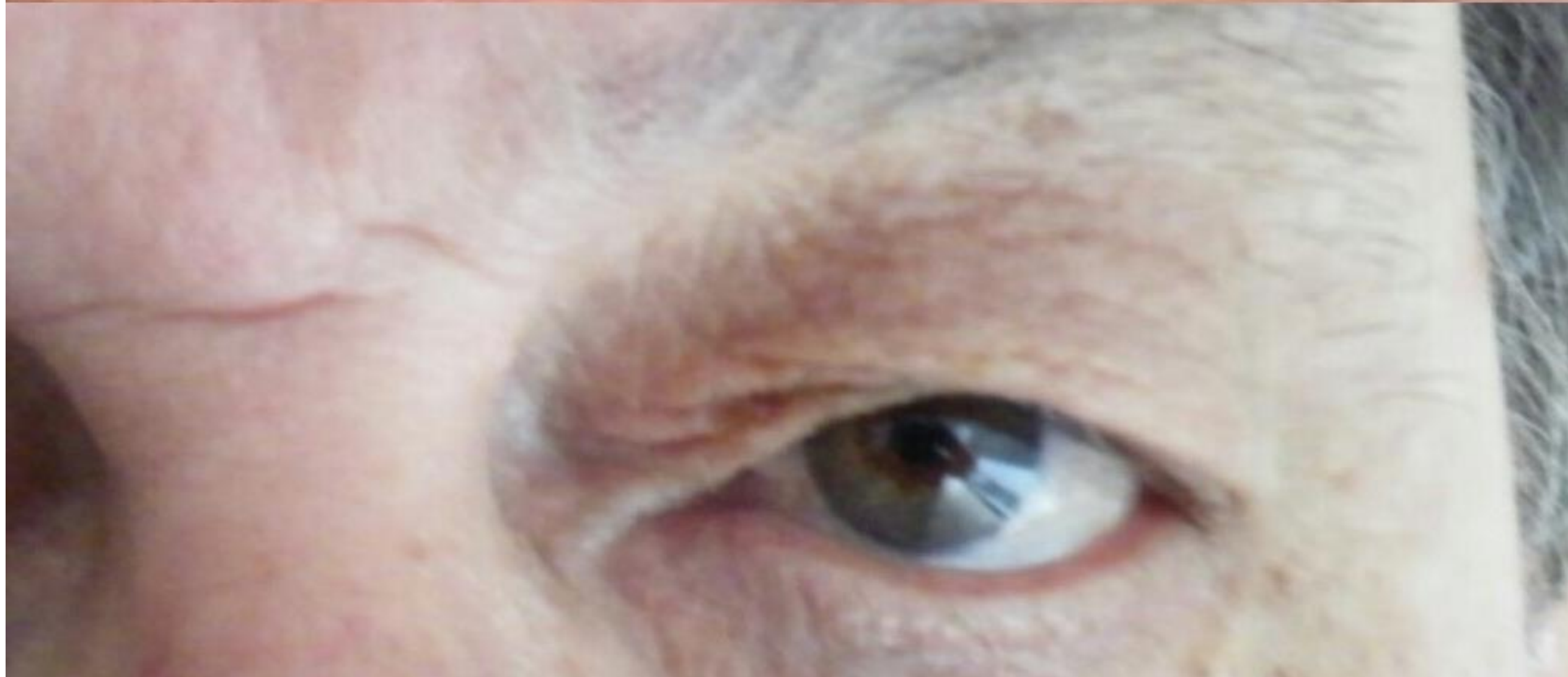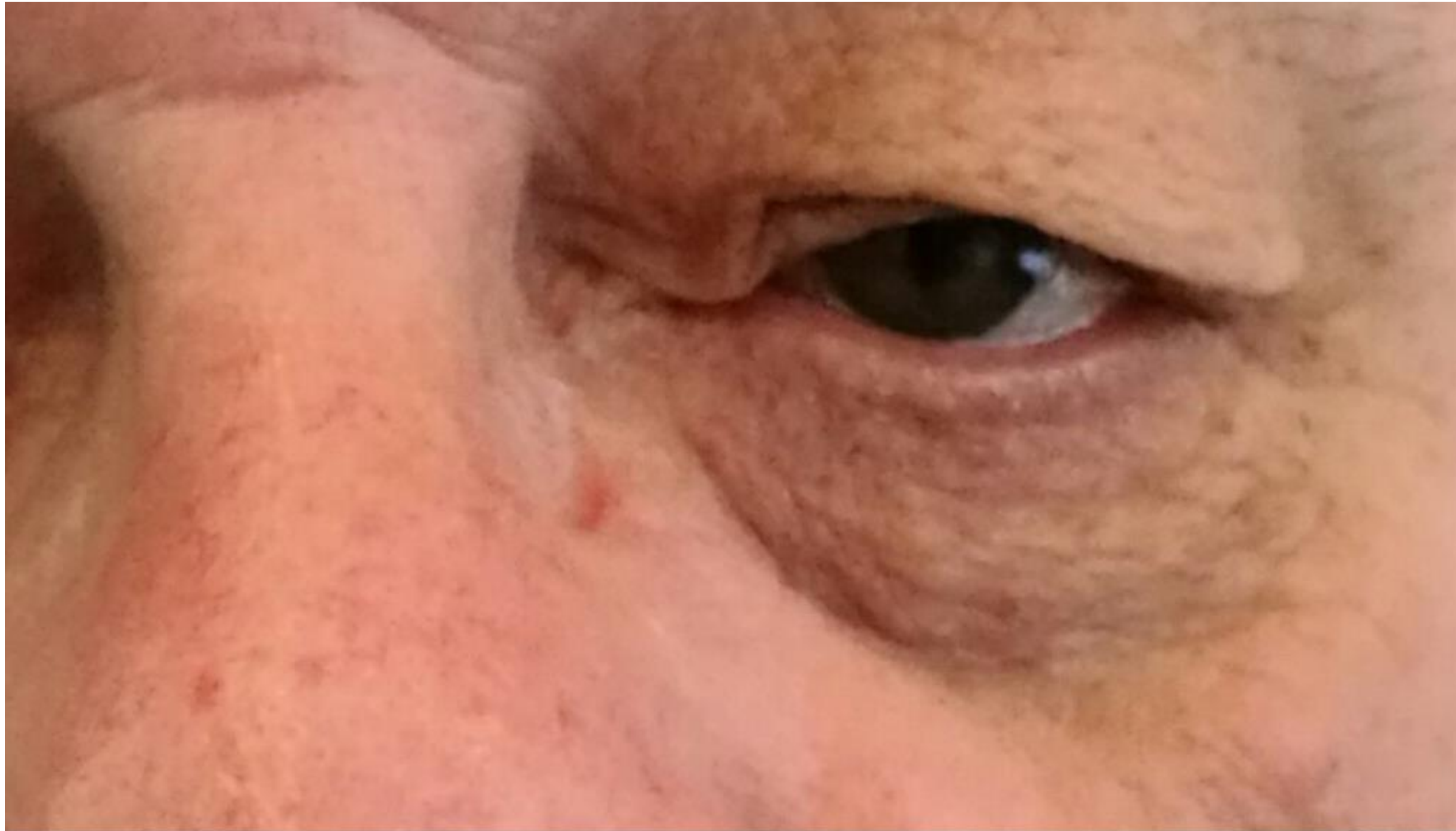- with the courtesy of Dr Jacques André David, Paris France
- before and after 2 weeks



PLASMA[®]GE

Blefaroplastia[®]

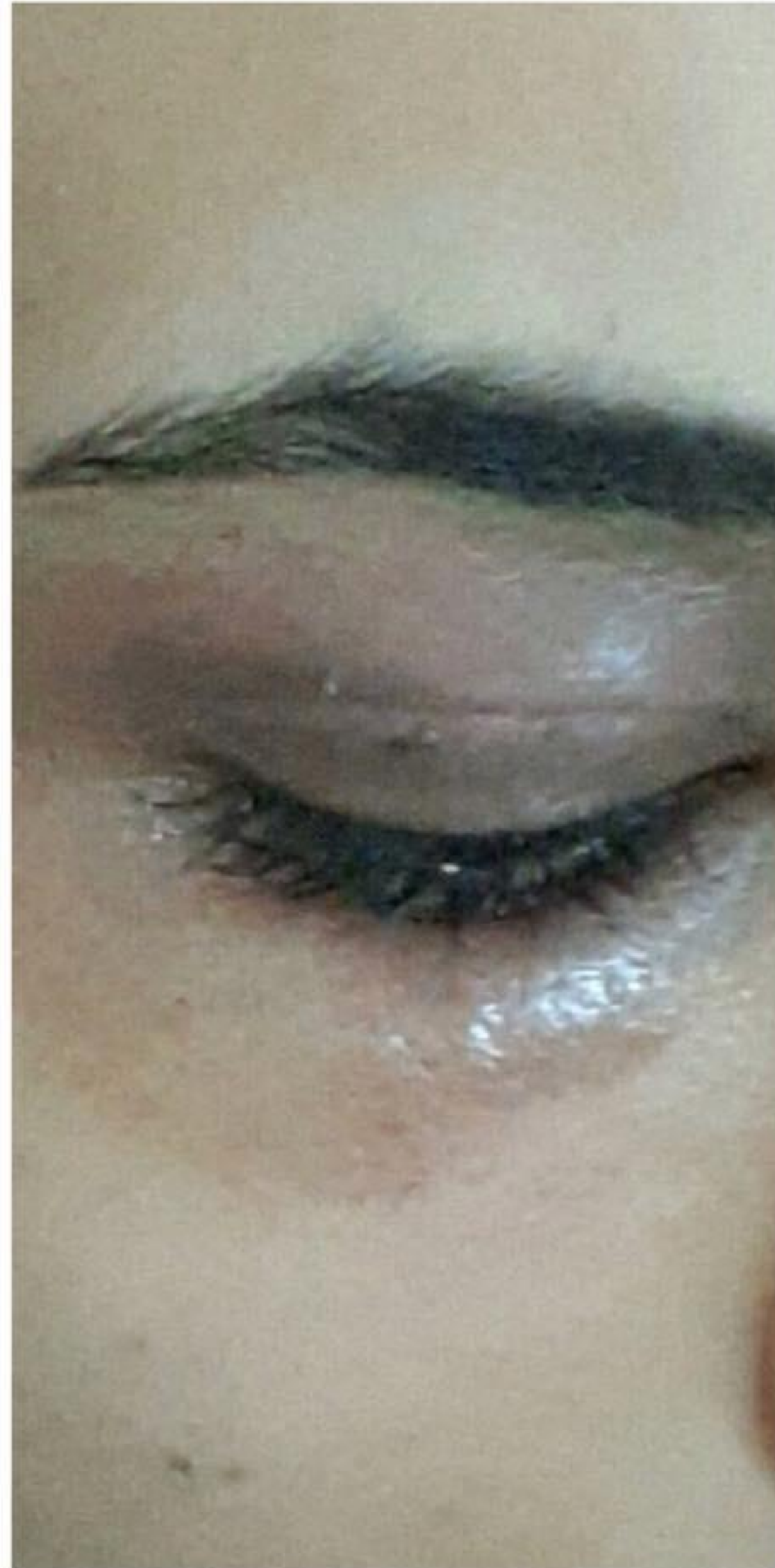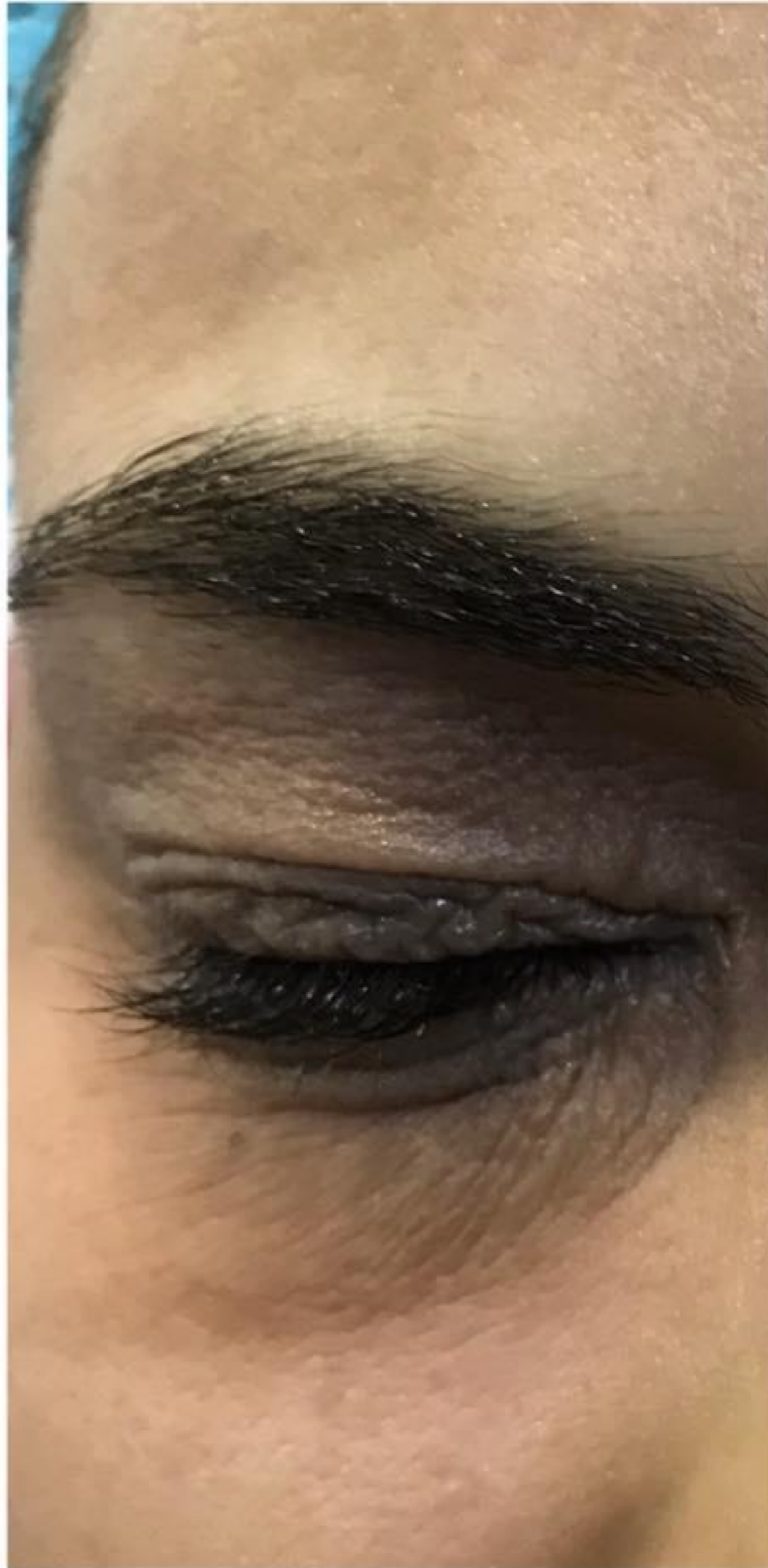- with the courtesy of Dr Jacques André David, Paris France
- before and after 1 week



PLASMA[®]GE

Blefaroplasma[®]

- with the courtesy of Dr Jacques André David, Paris France
- before and after 2 weeks



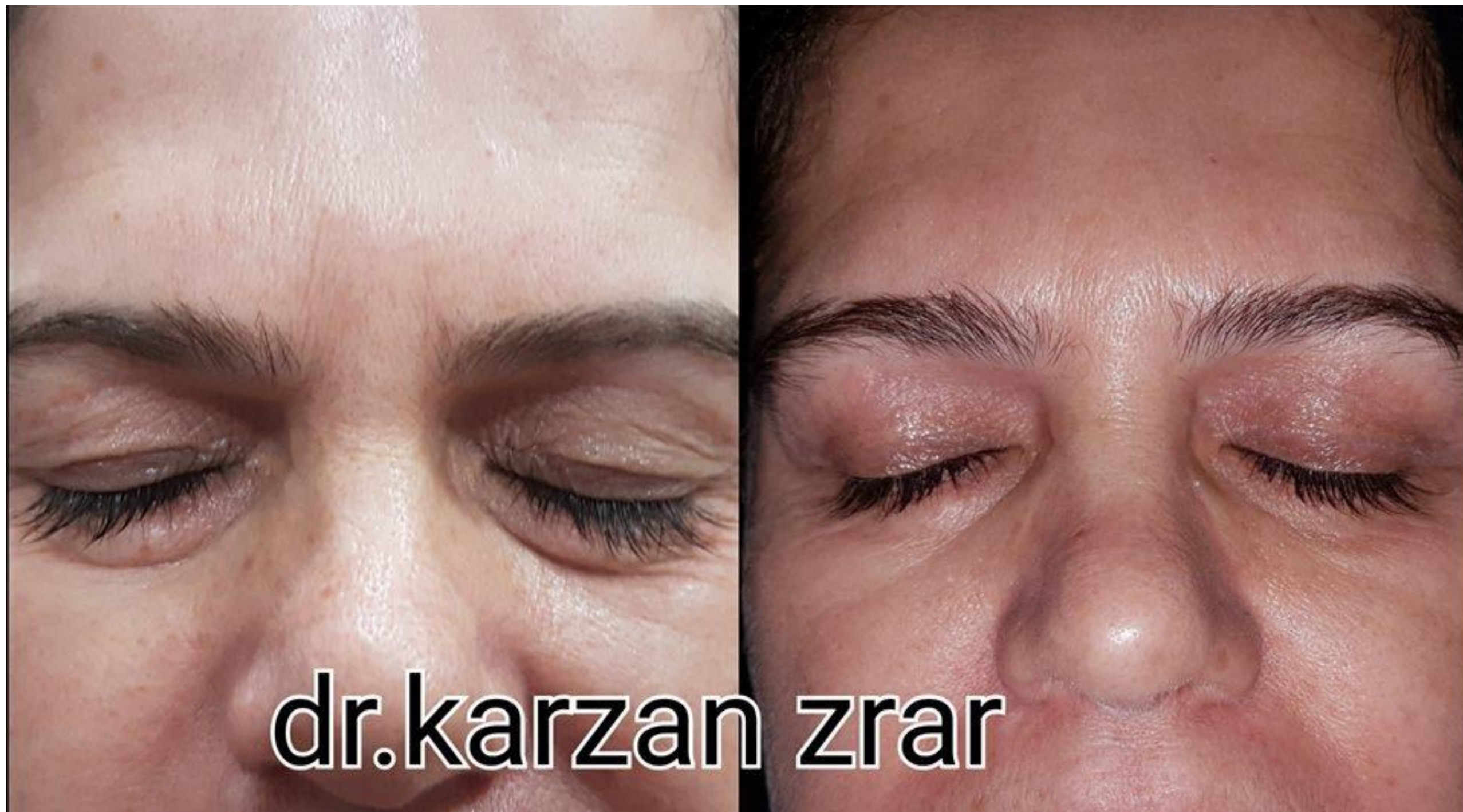PLASMA[®]GE

Blefaroplasma[®]

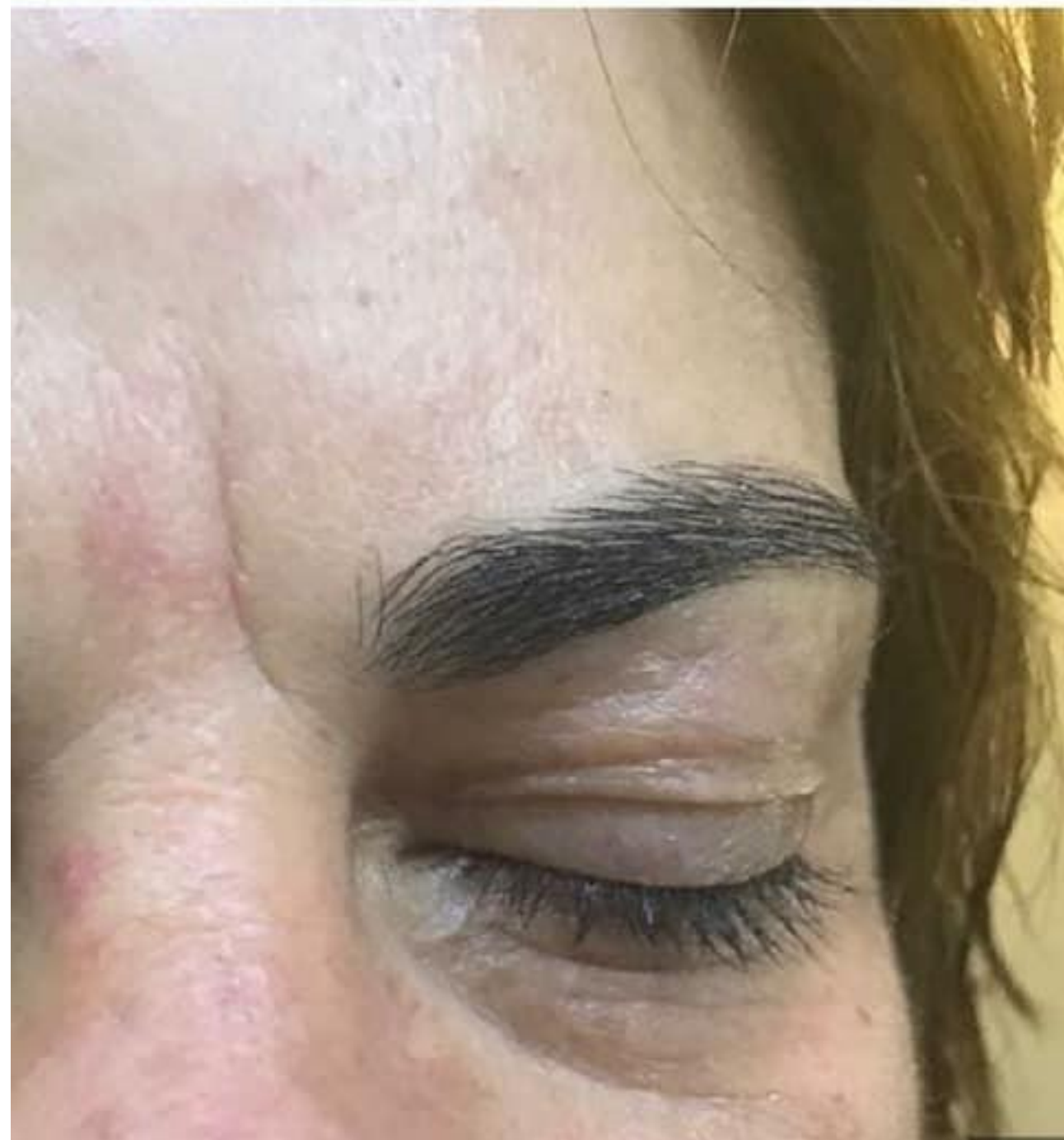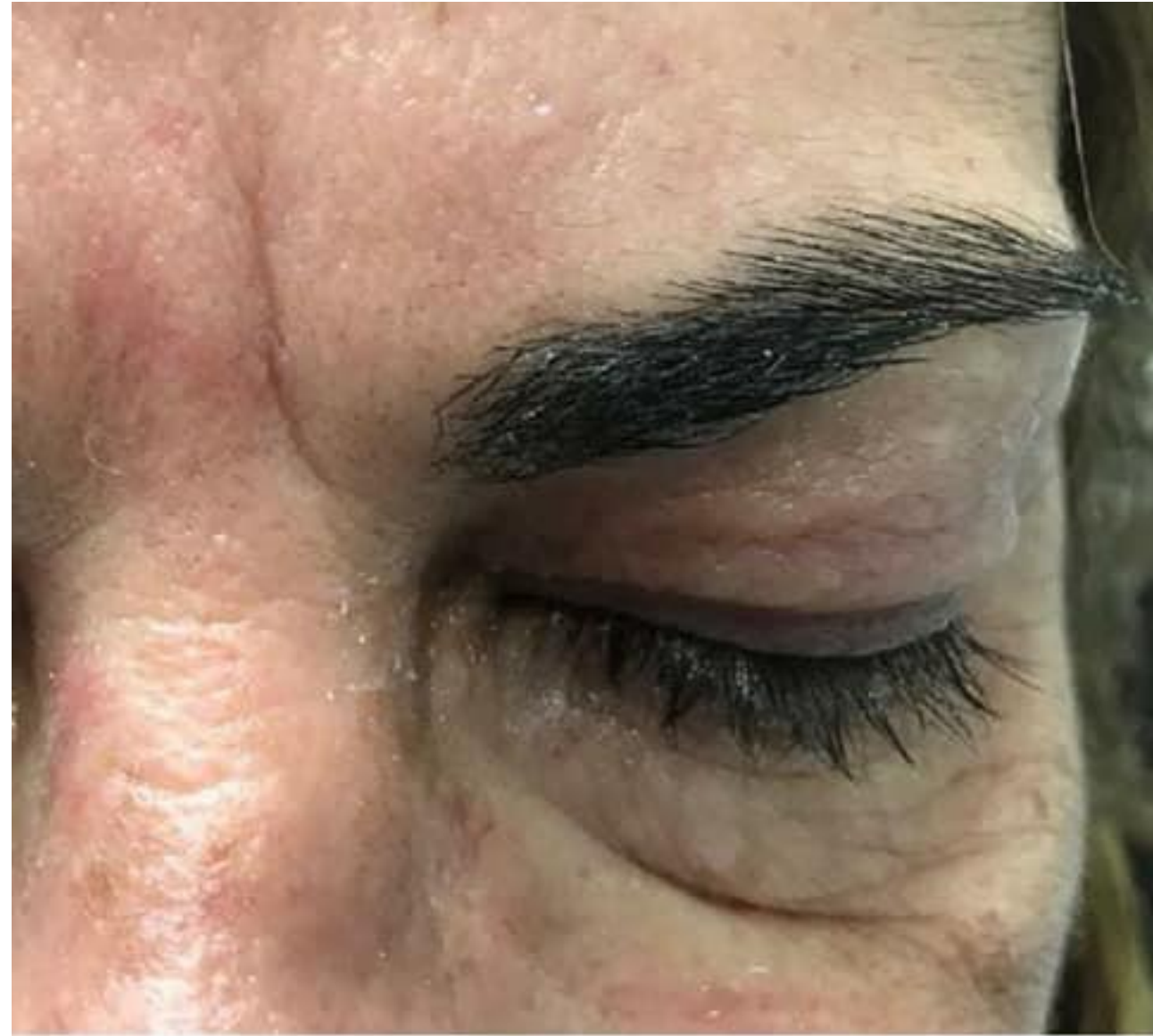- with the courtesy of Dr Shilan Barzinjy, Irbil Iraq
- 1 session: before and after 1 week

PLASMA[®]

Blefaroplasma[®]



- with the courtesy of Dr Karzan Zrar, Slemani Iraq
- 1 session: before and after 1 month



PLASMA[®]

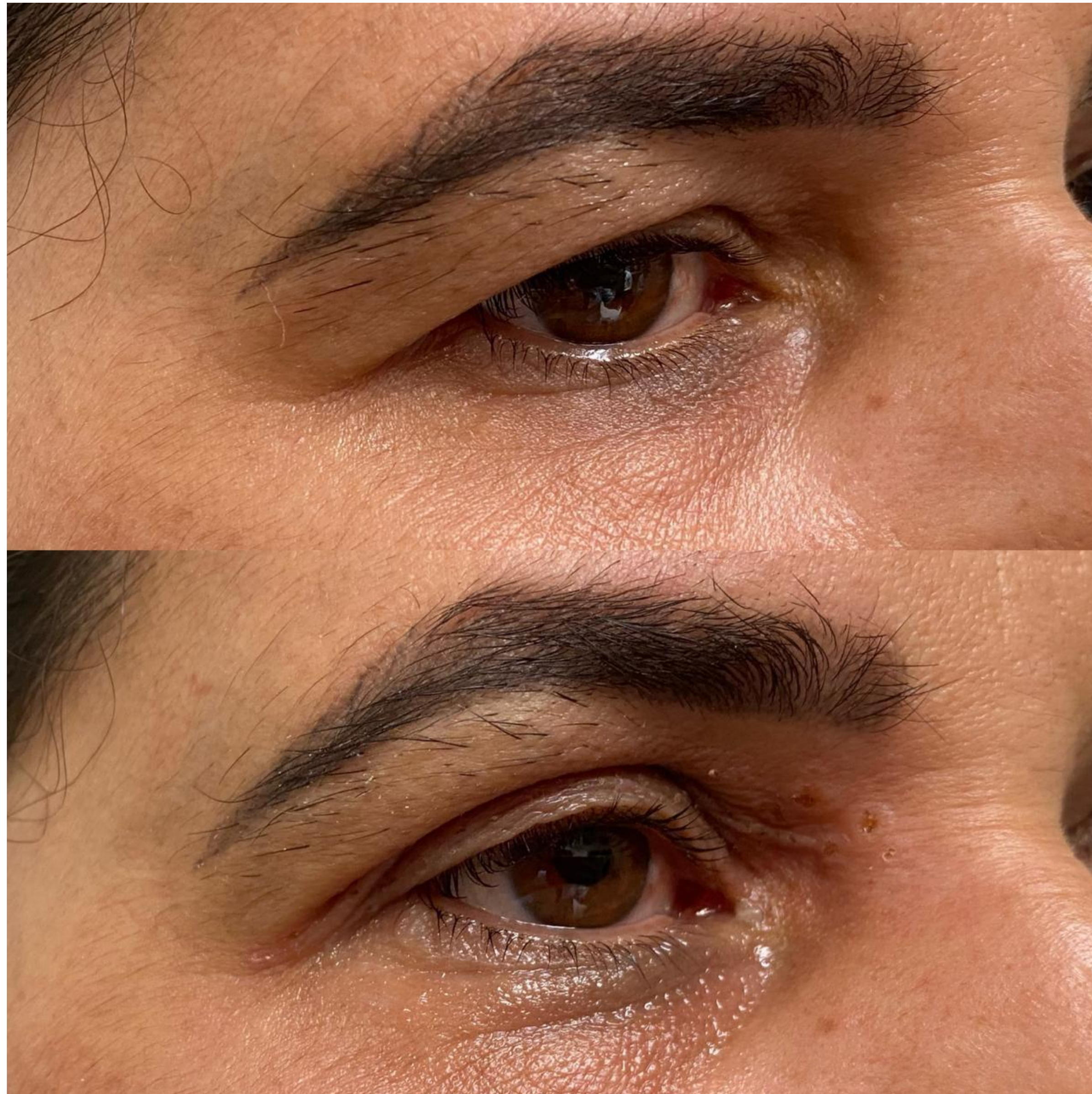Blefaroplasma[®]

- with the courtesy of Dr Raed Rtail, Beyrouth Lebanon
- 1 session: before and after 1 month

PLASMA[®]GE

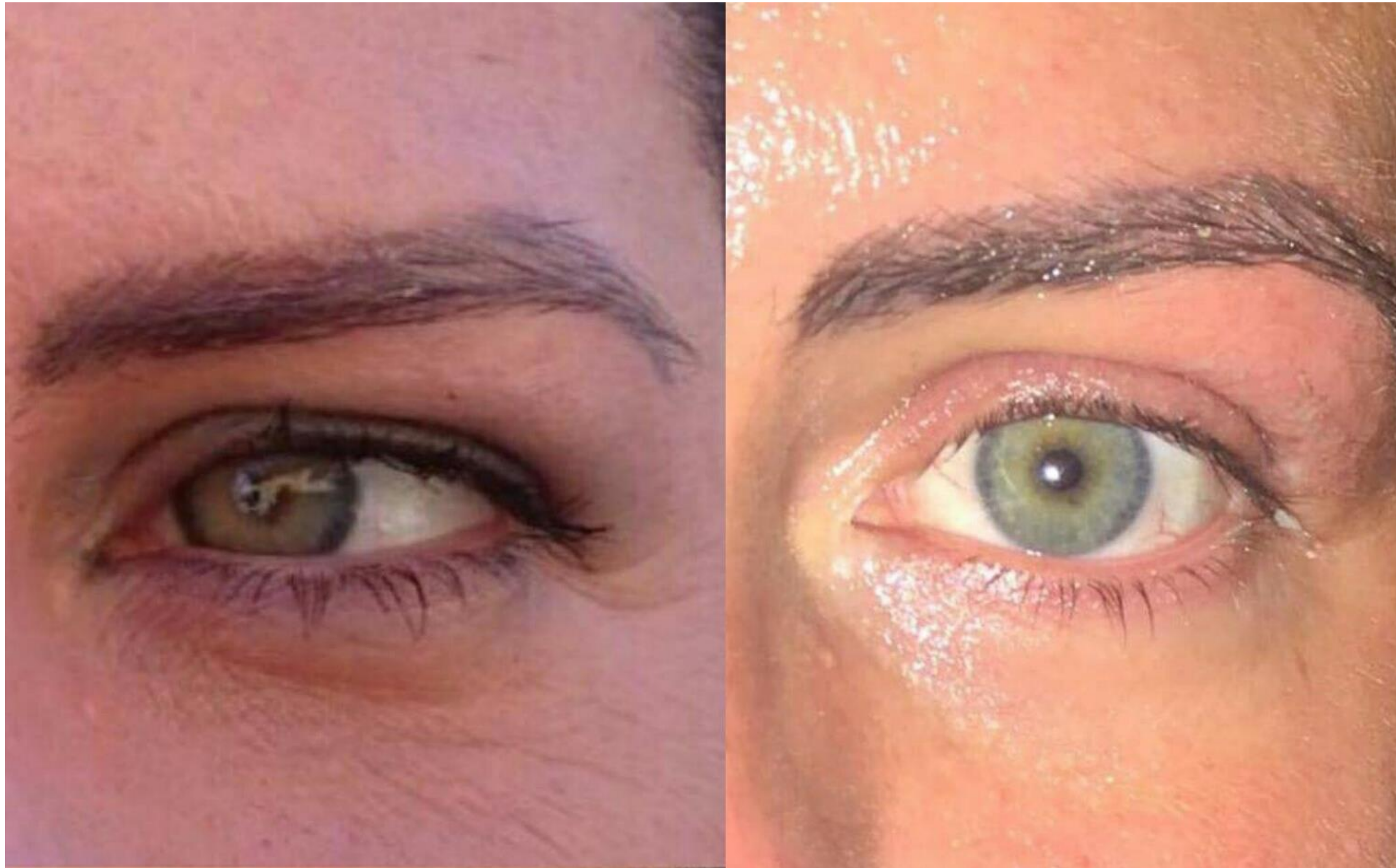Blefaroplasma[®]

- with the courtesy of MEDPRO, Brazil
- 1 session: before and after 1 month

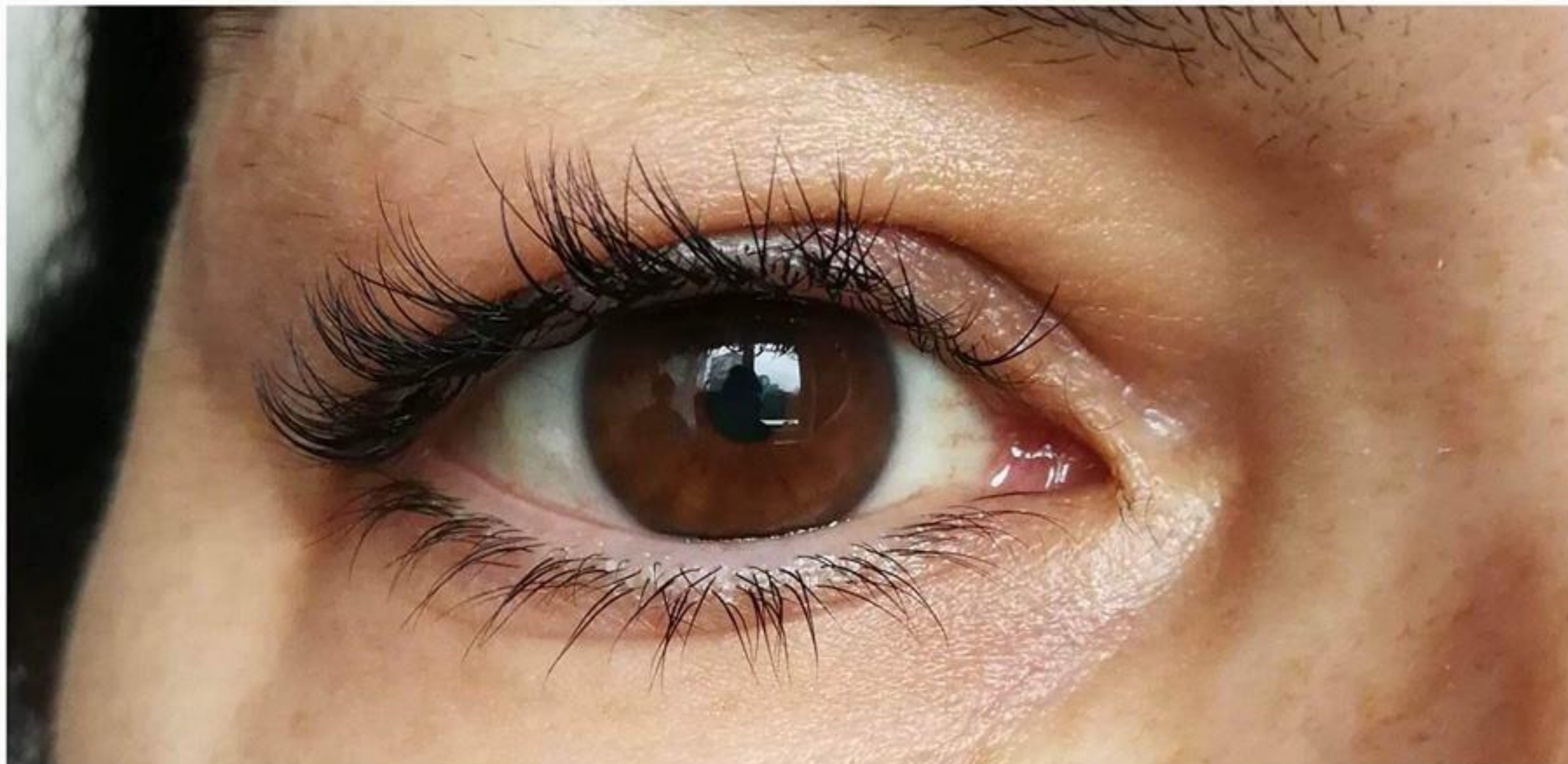
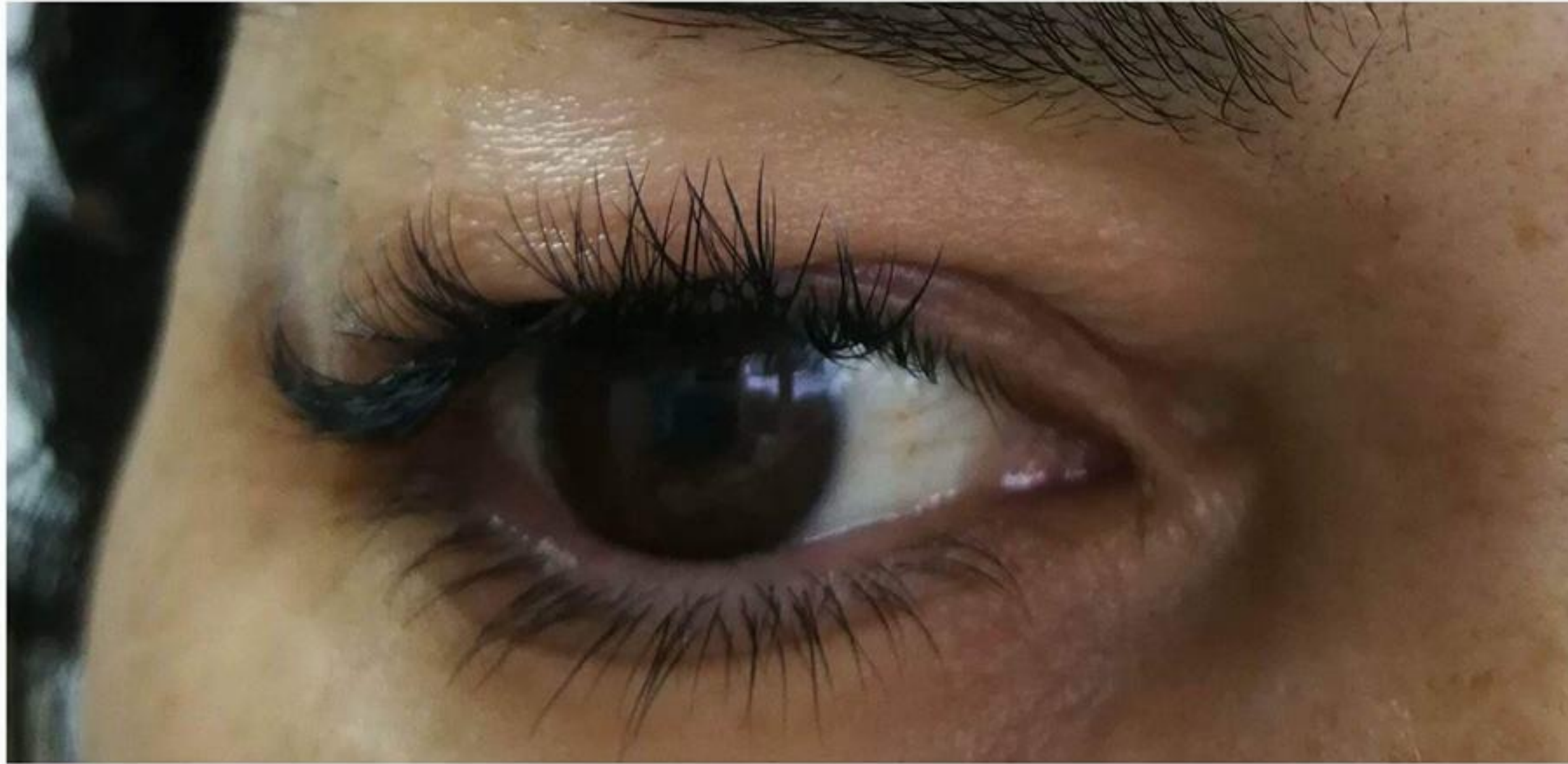
PLASMA[®]GE

Blefaroplasma[®]



- with the courtesy of Dr Nikola Milosevic, Zagreb, Croatia
- before and after 1 month
- one session



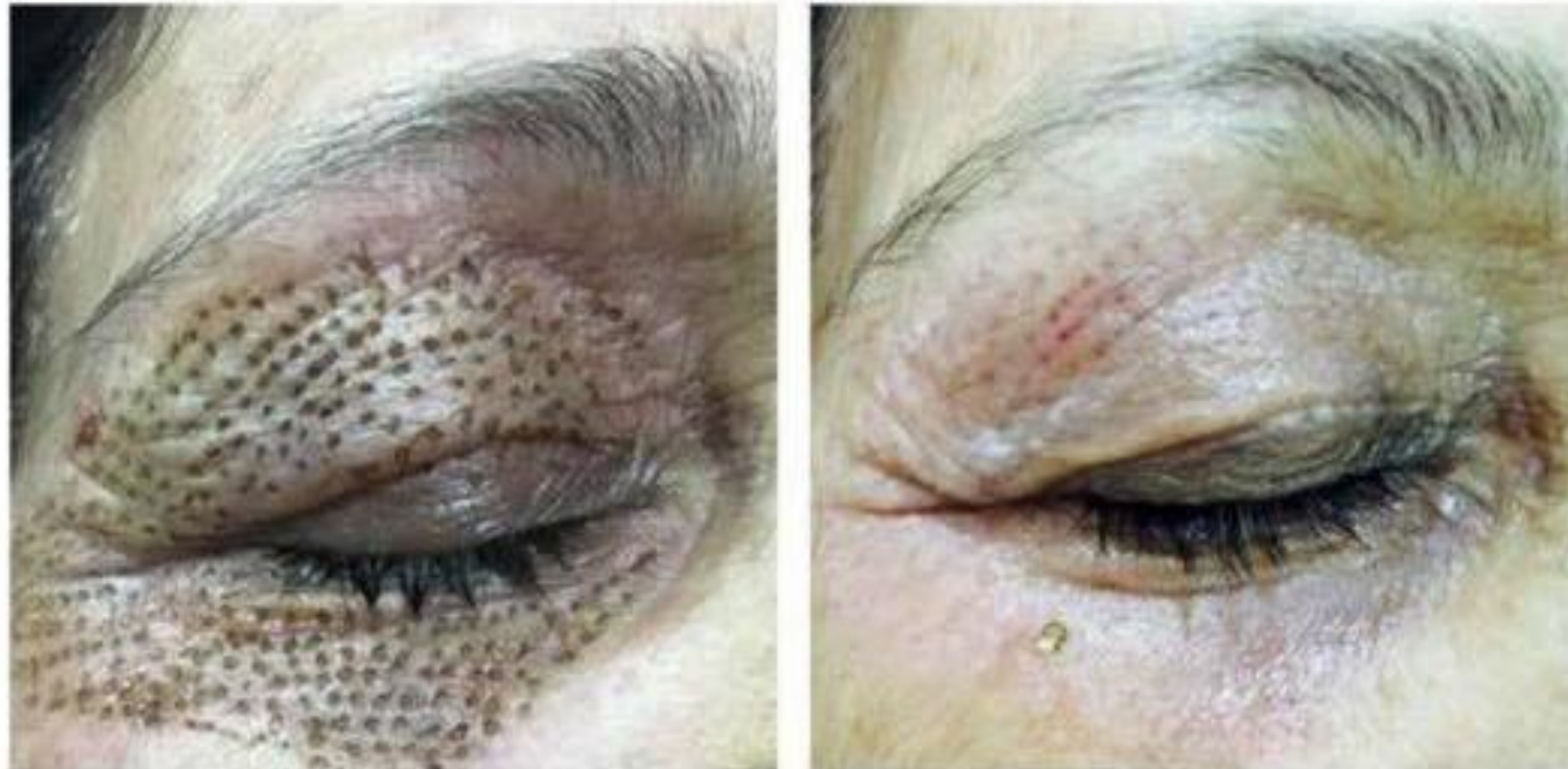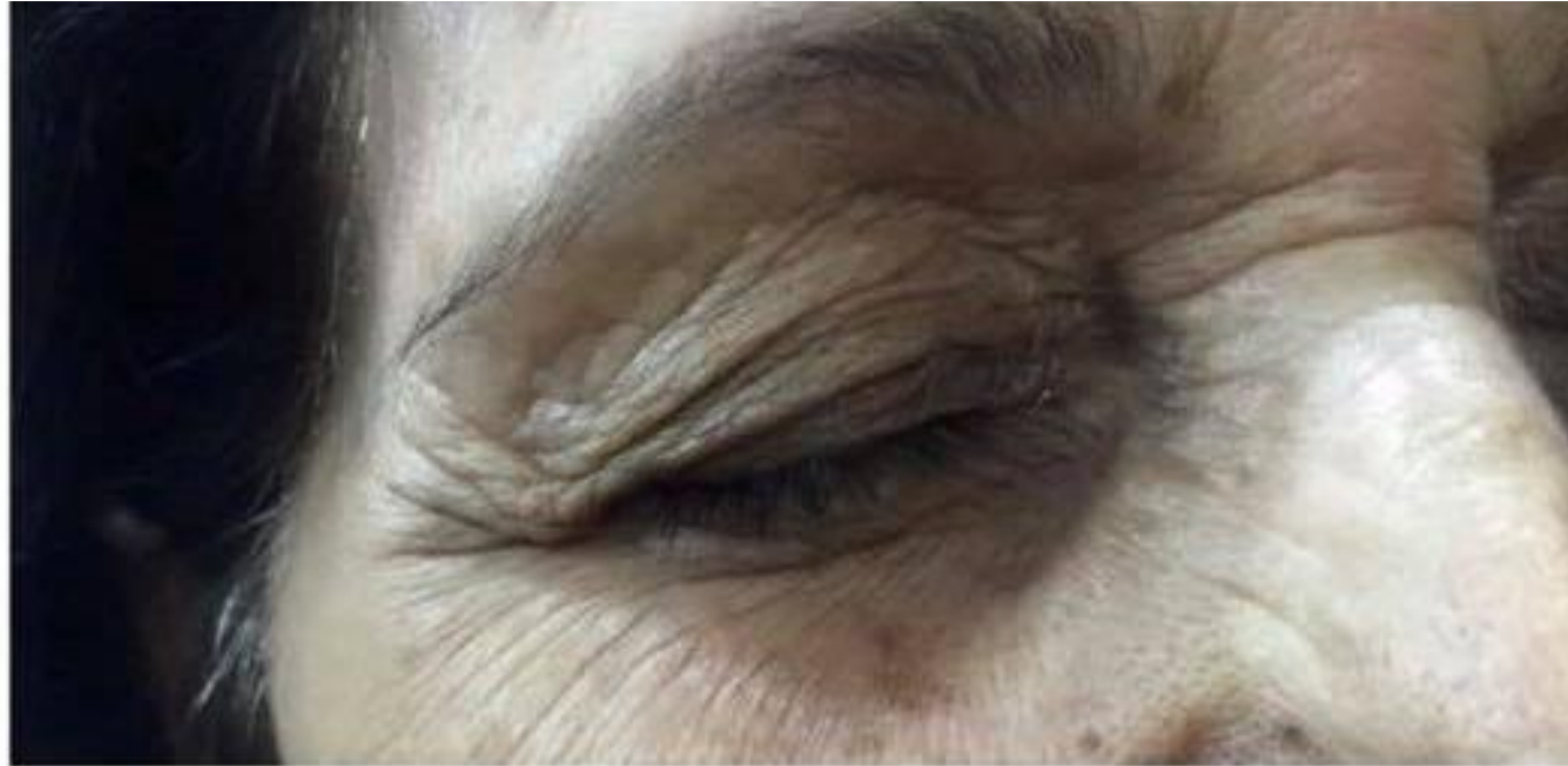PLASMA[®]GE

Blefaroplasma[®]

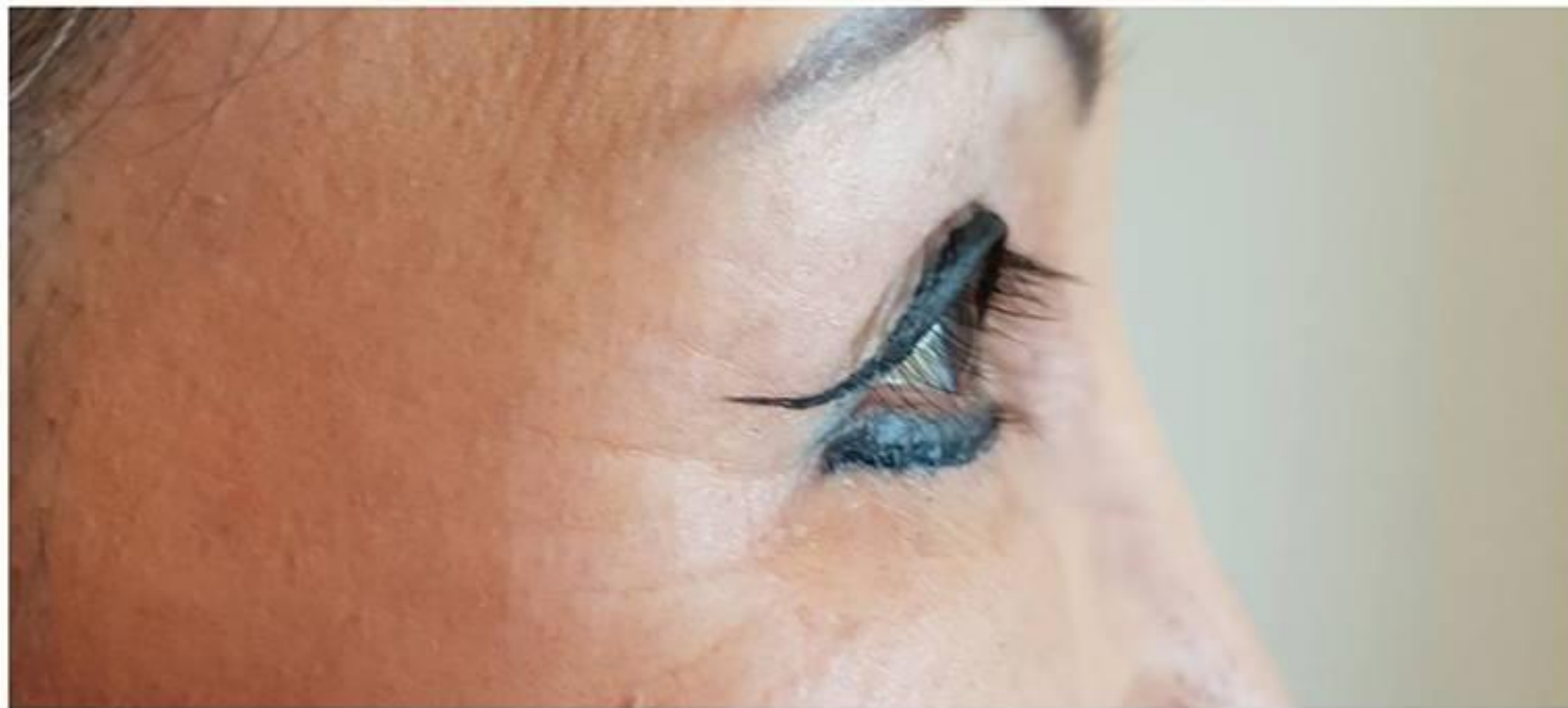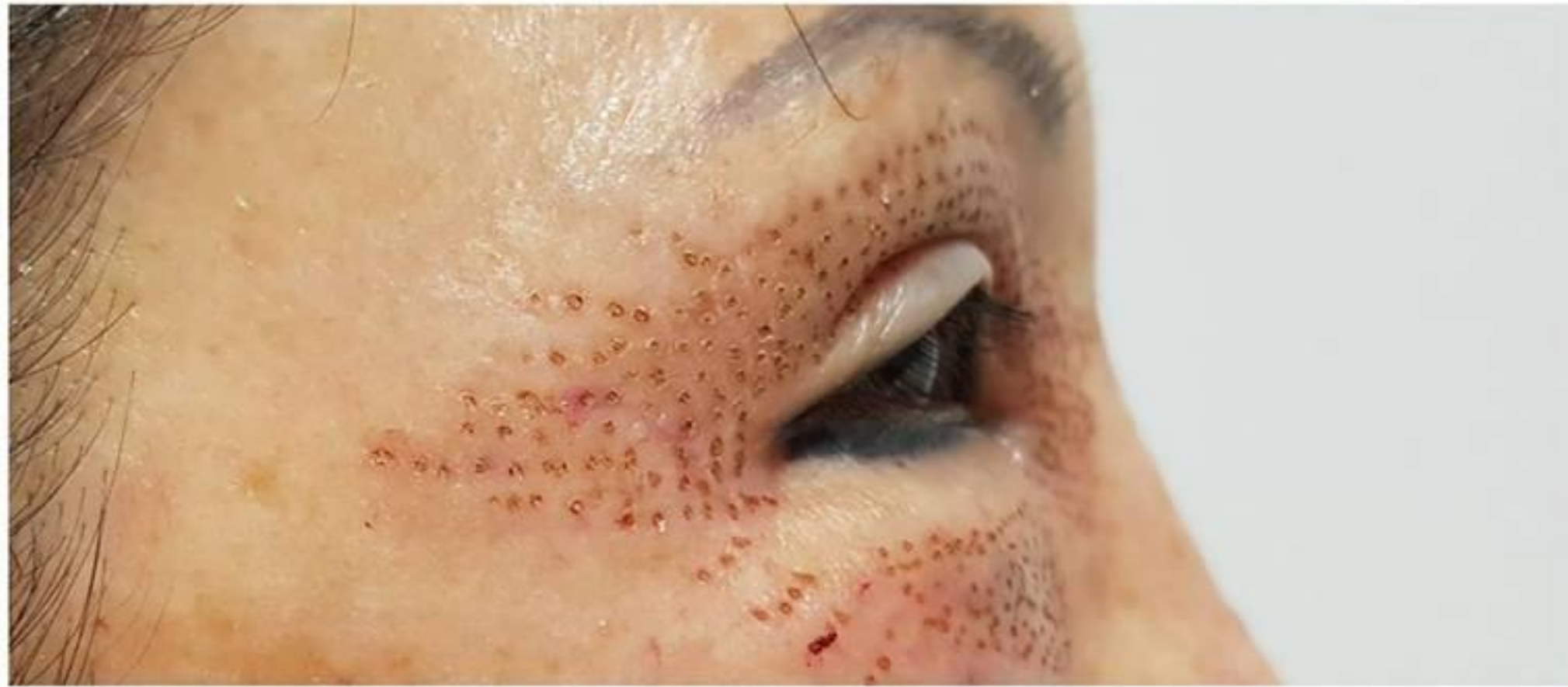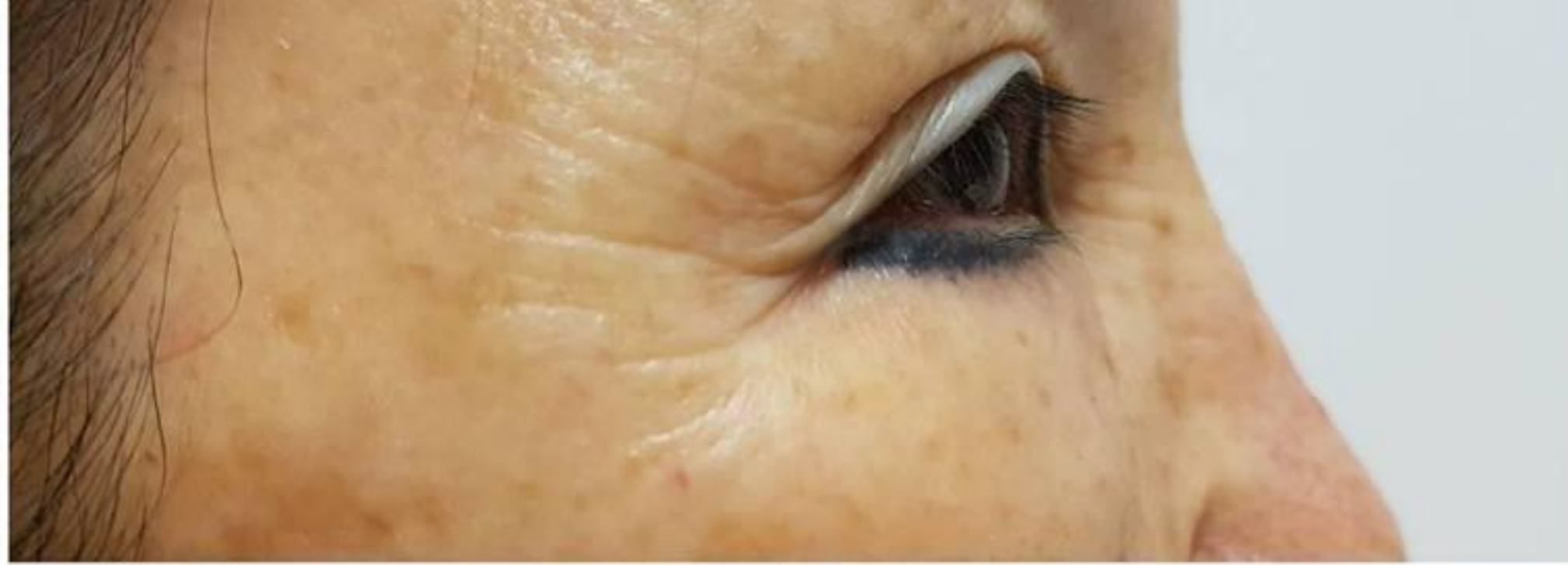- with the courtesy of Dr Daniela Taher, Bucharest Romania
- 1 session: before and after 1 month

PLASMA[®]GE

Blefaroplasma[®]



- with the courtesy of Dr Ara Yousif, Sulaimani Iraq
- 1 session: before, right after the session and after 10 days



PLASMA[®]GE

Blefaroplasma[®]

- with the courtesy of Dr Hanna Sheu, Linz Austria
- 1 session: before and after 1 month



PLASMA[®]GE

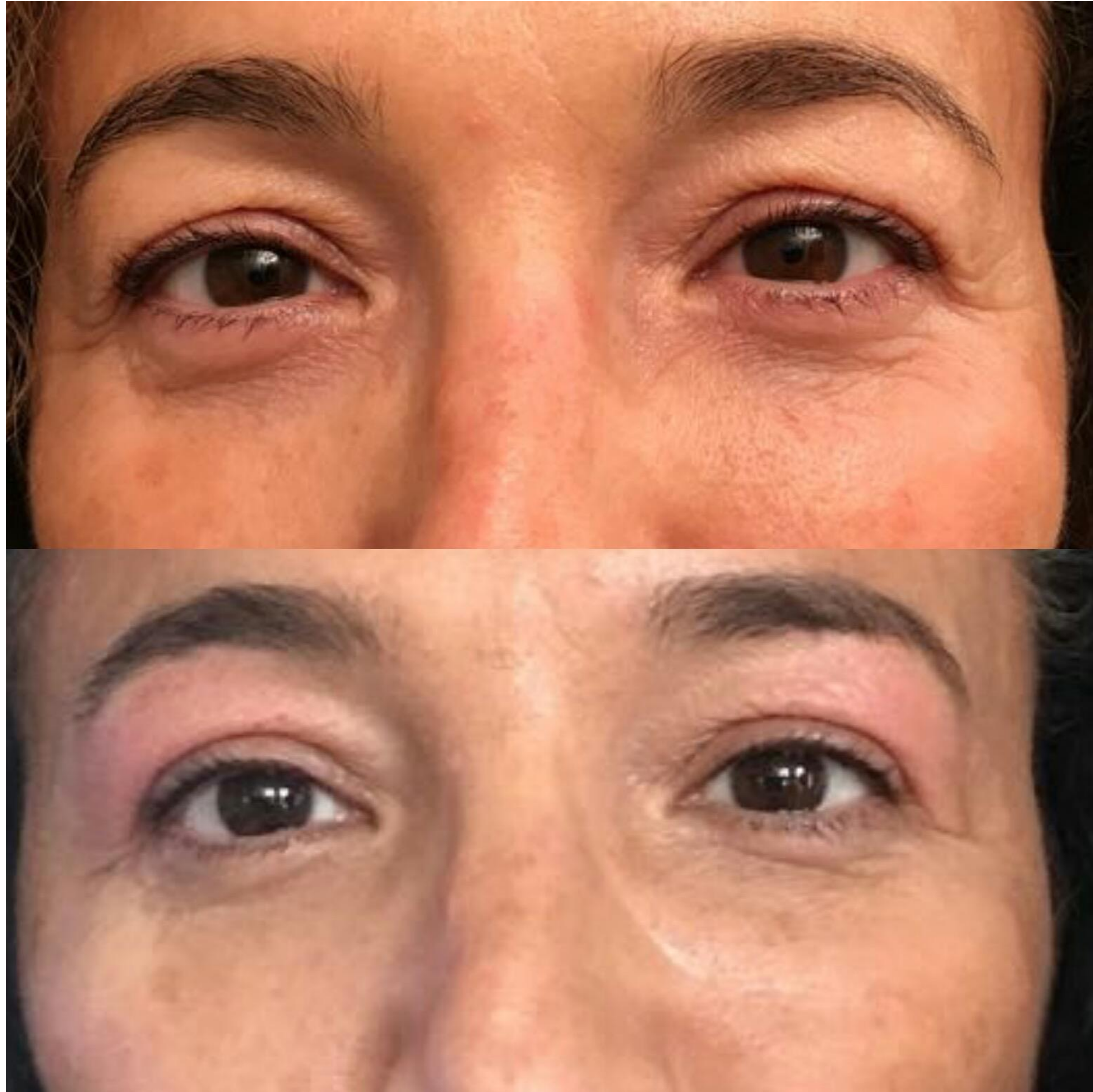Blefaroplasma[®]

- with the courtesy of Nikola Milojevic, Zagreb Croatia
- before and after 3 weeks

PLASMA[®]GE

Blefaroplastia[®]

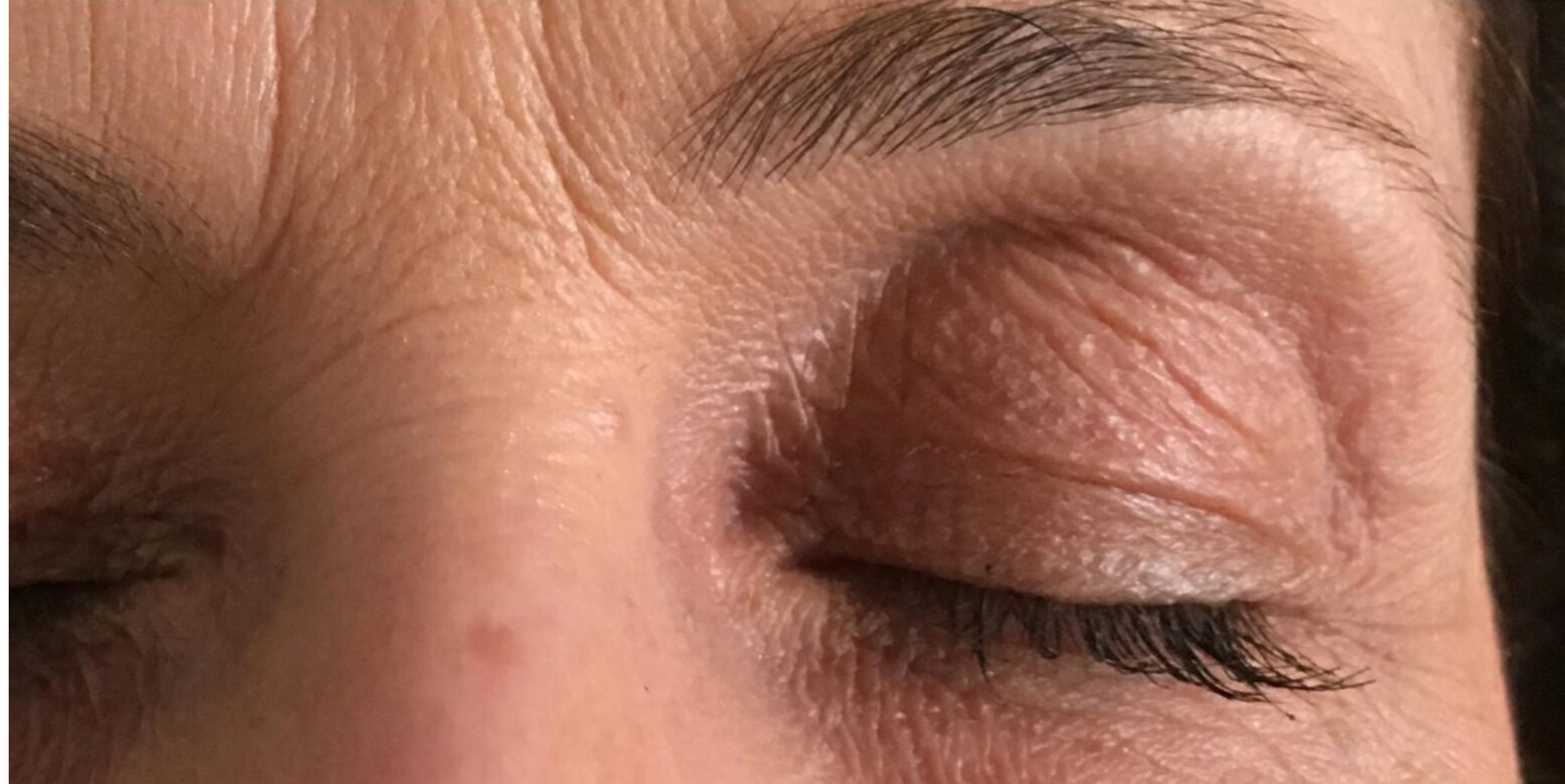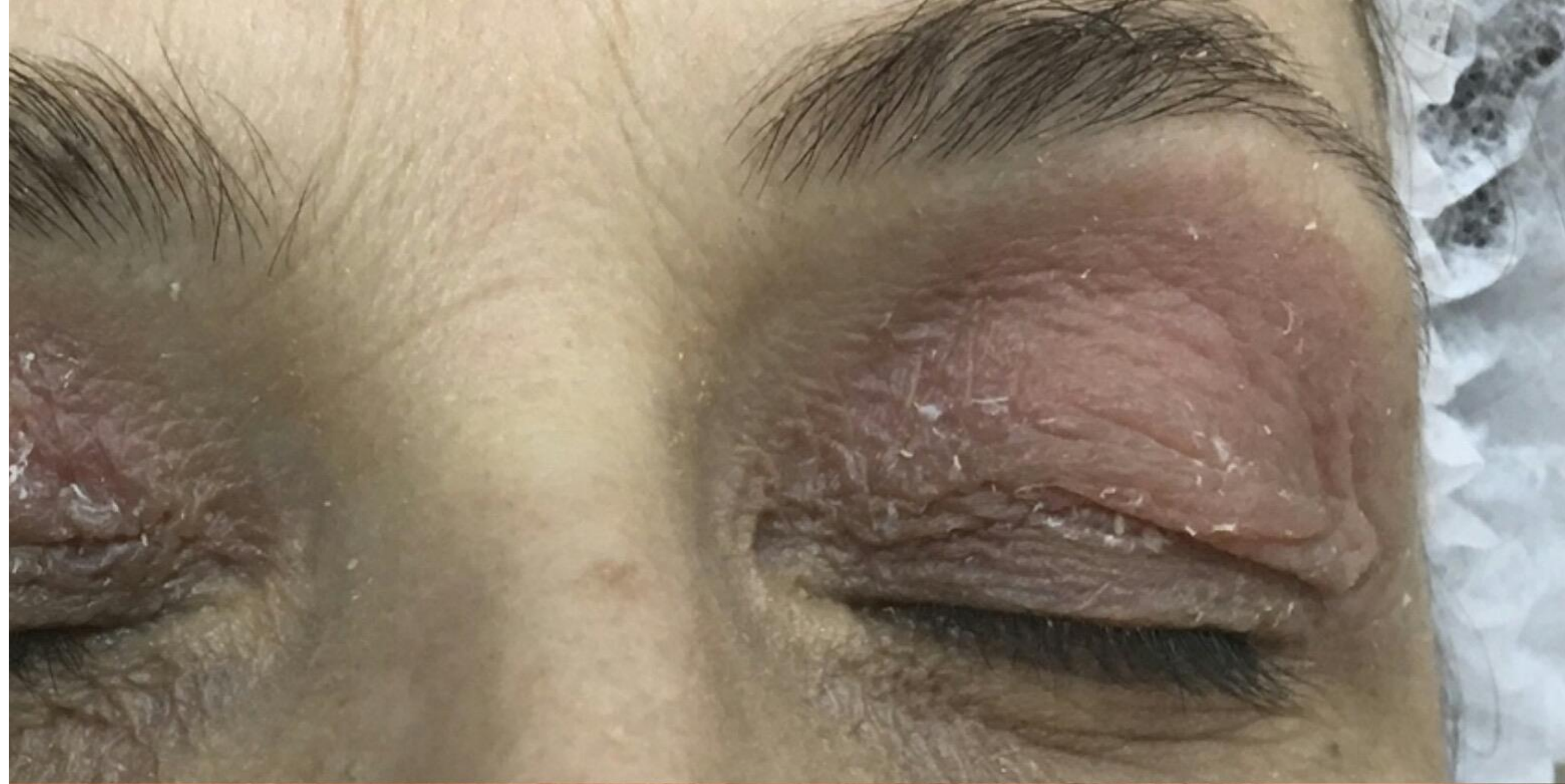- before and after 10 days with the courtesy of Dr Jacques André David, France
- one session



PLASMA[®]GE

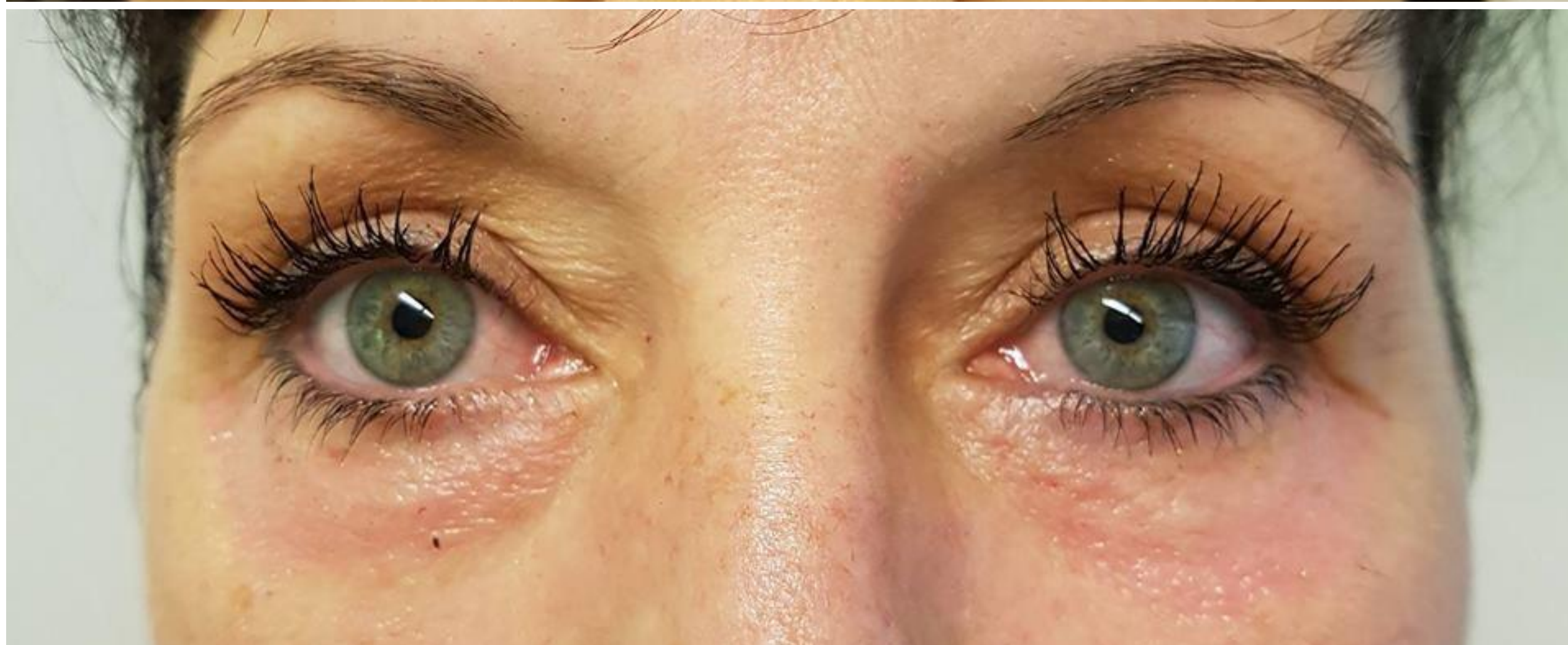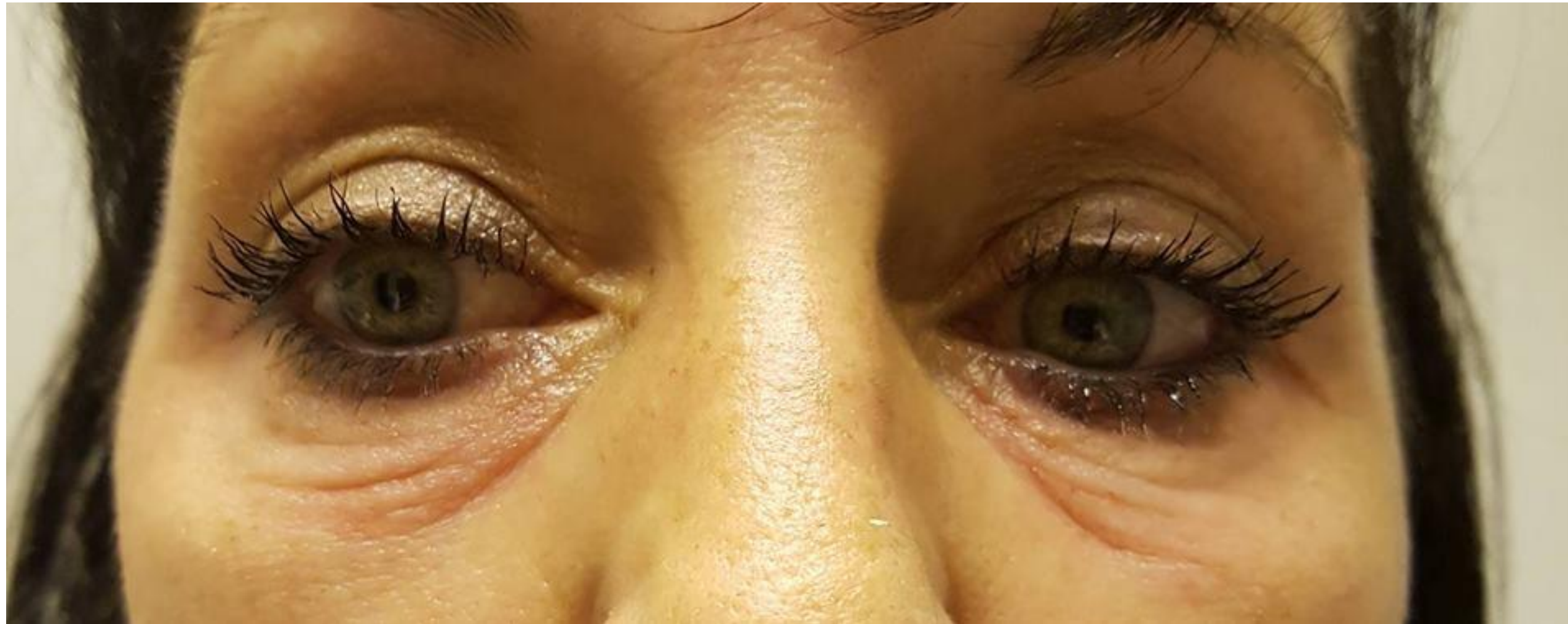
Blefaroplastia[®]

- before and after 3 weeks with the courtesy of Dr Ana Maria D'Ardis
- one session



PLASMA[®]GE

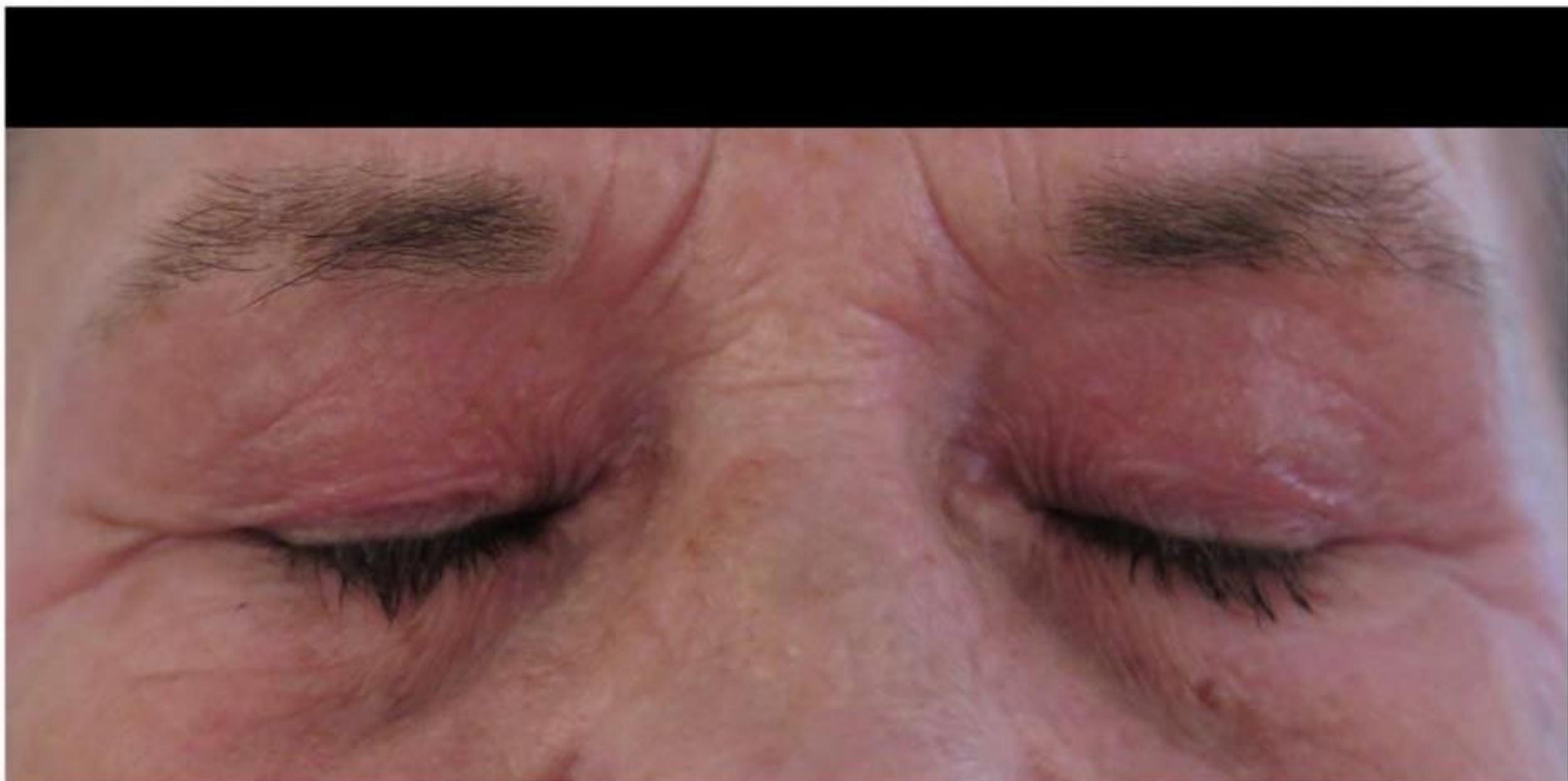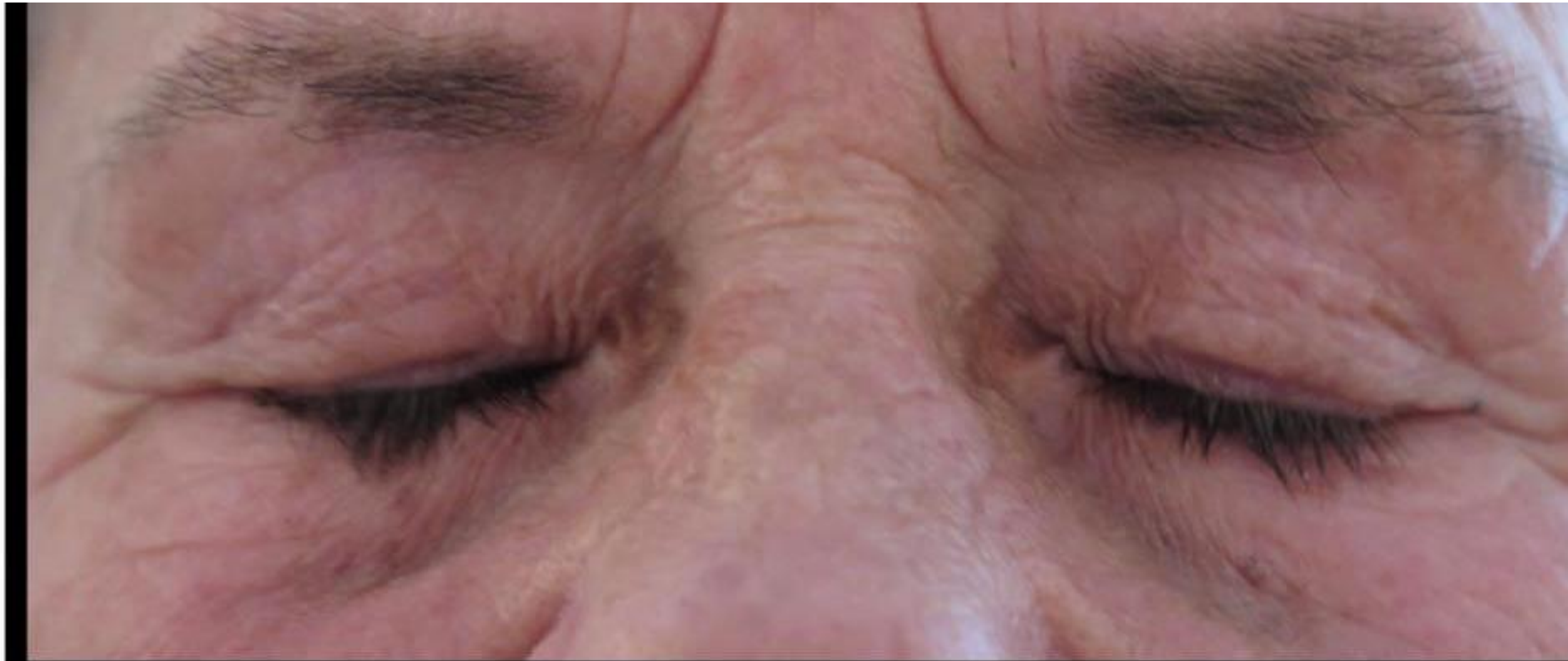Blefaroplasma[®]



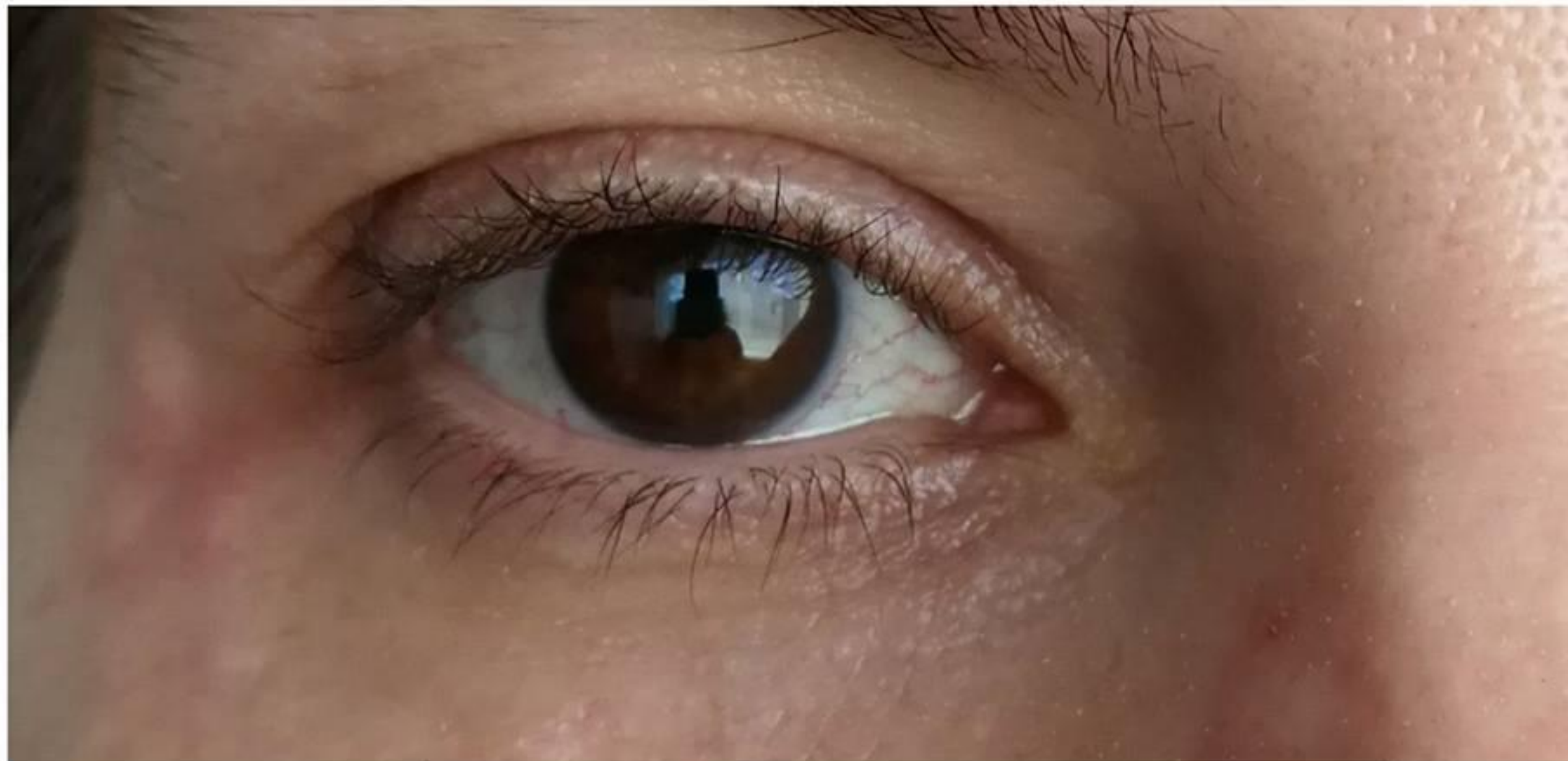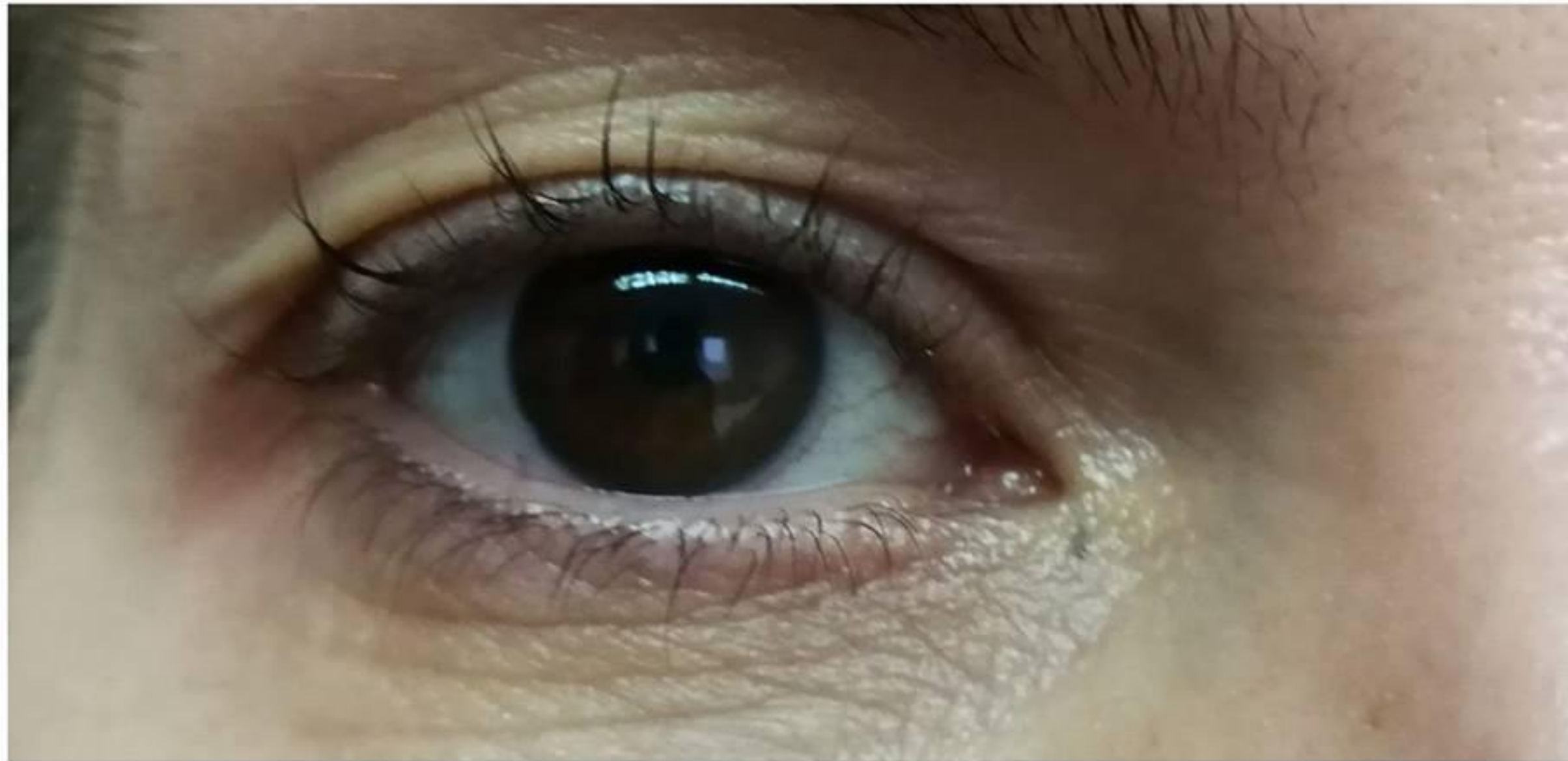- with the courtesy of Dr Ruth Weissberg, Munich Germany
- 1 session: before and after 7 days

PLASMA[®]GE

Blefaroplasma[®]



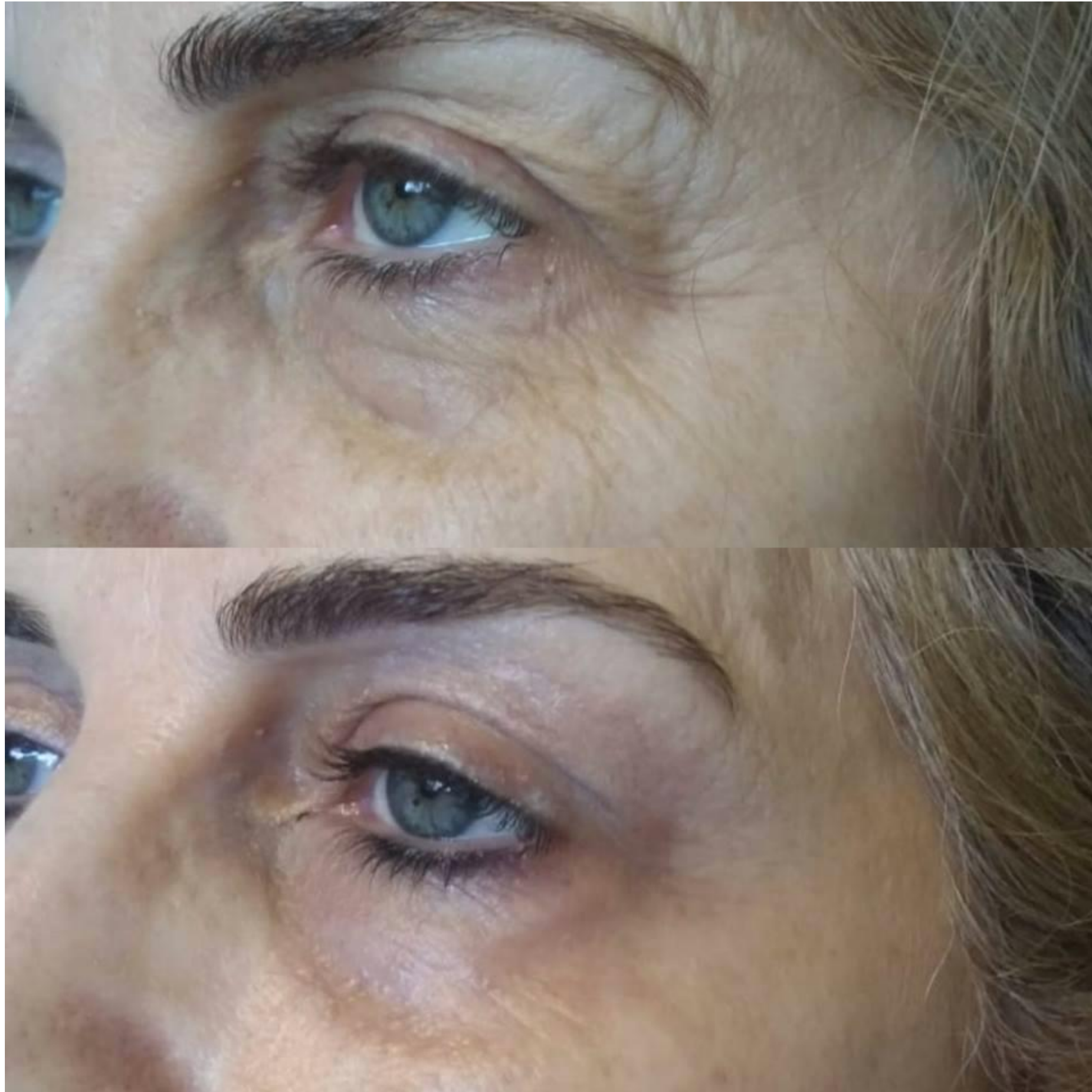- with the courtesy of Dr Frank Zipprich, Aschaffenburg Germany
- 1 session: before and after 14 days



PLASMA[®]GE

Blefaroplasma[®]

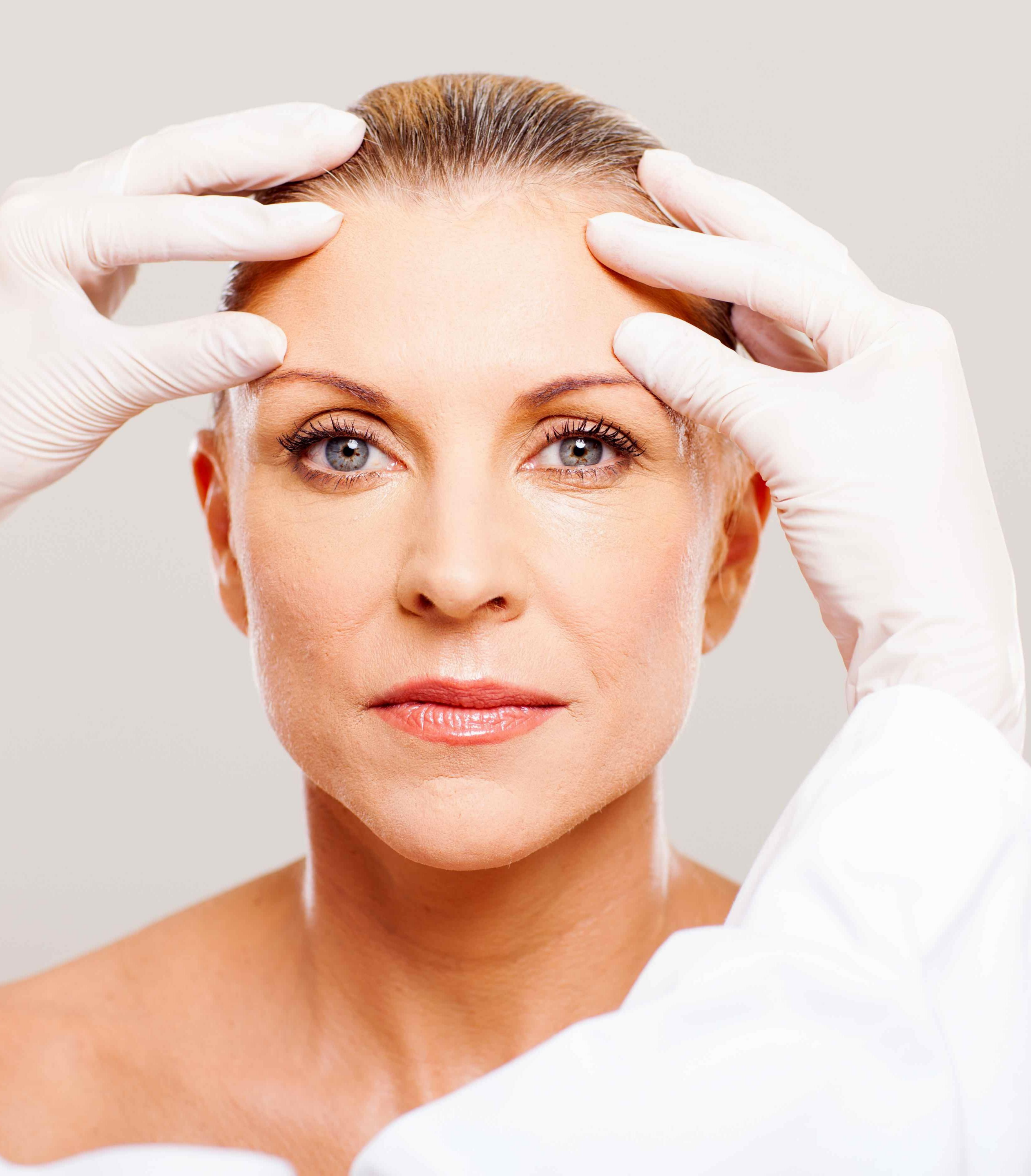- with the courtesy of Dr Daniela Taher, Bucharest Romania
- 1 session: before and after 1 month



PLASMA[®]GE

Blefaroplasma[®]

- with the courtesy of Dr Silvia Weber, Beyrouth Lebanon
- 1 session: before and after 2 weeks



PLASMA[®]GE

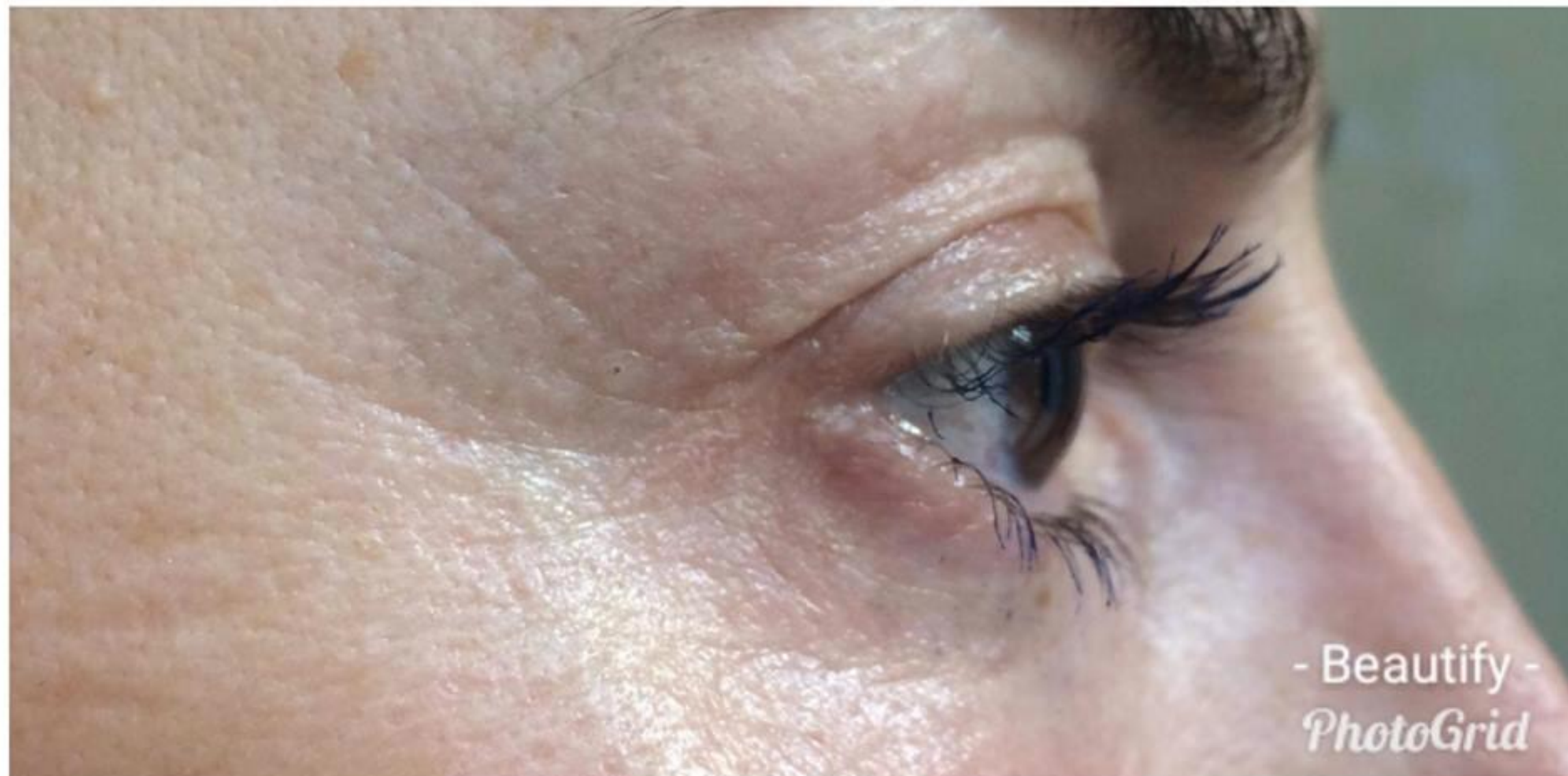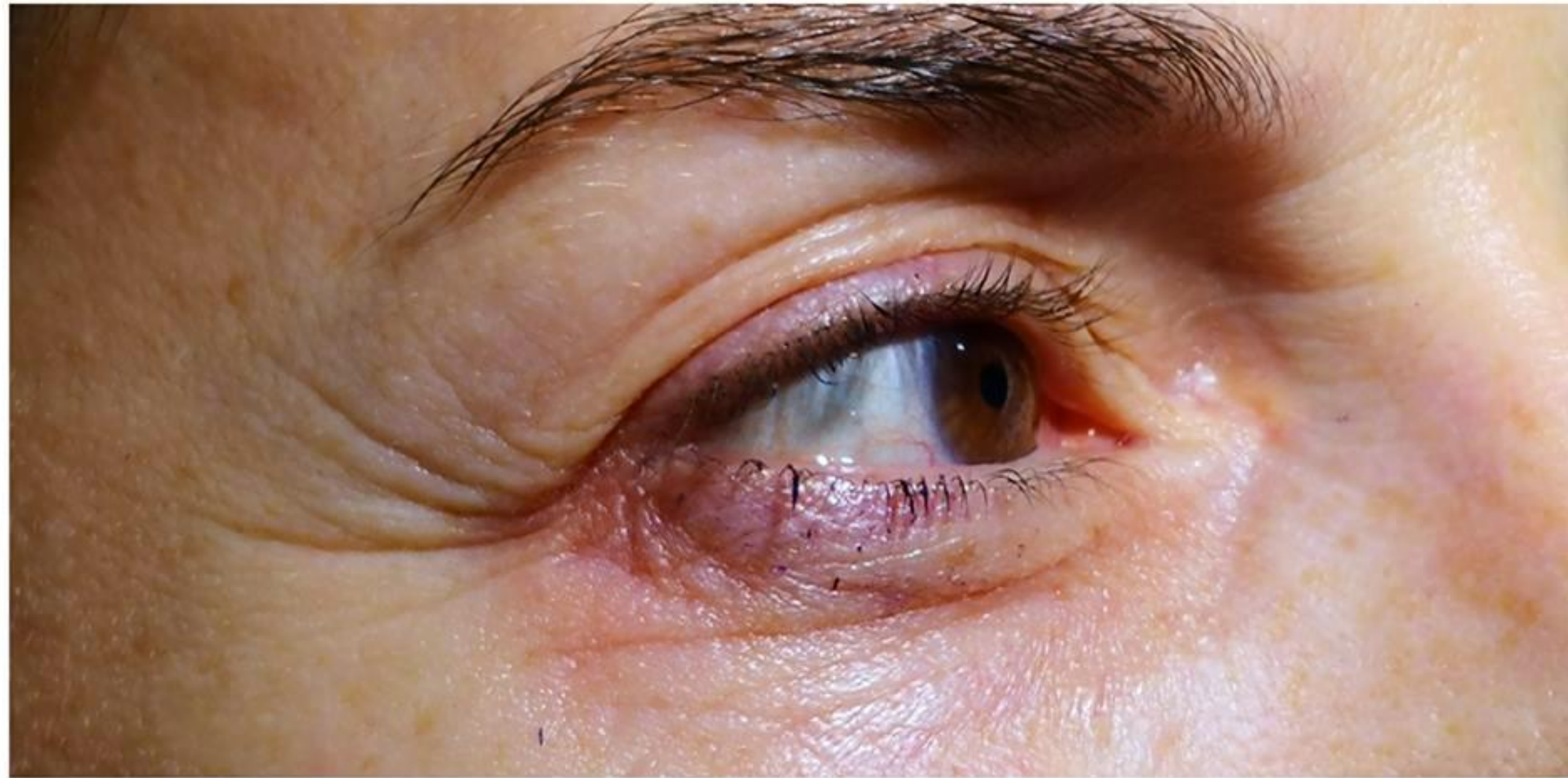Wrinkles and fine lines

- Localized zones
- Precise tool
- Skin retraction

PLASMA[®]GE

Blefaroplasma and fine lines

- with the courtesy of Dr. Annamaria D'Ardis, Napoli, Italy
- Crows feet wrinkles.
- after 1 session



PLASMAGE[®]

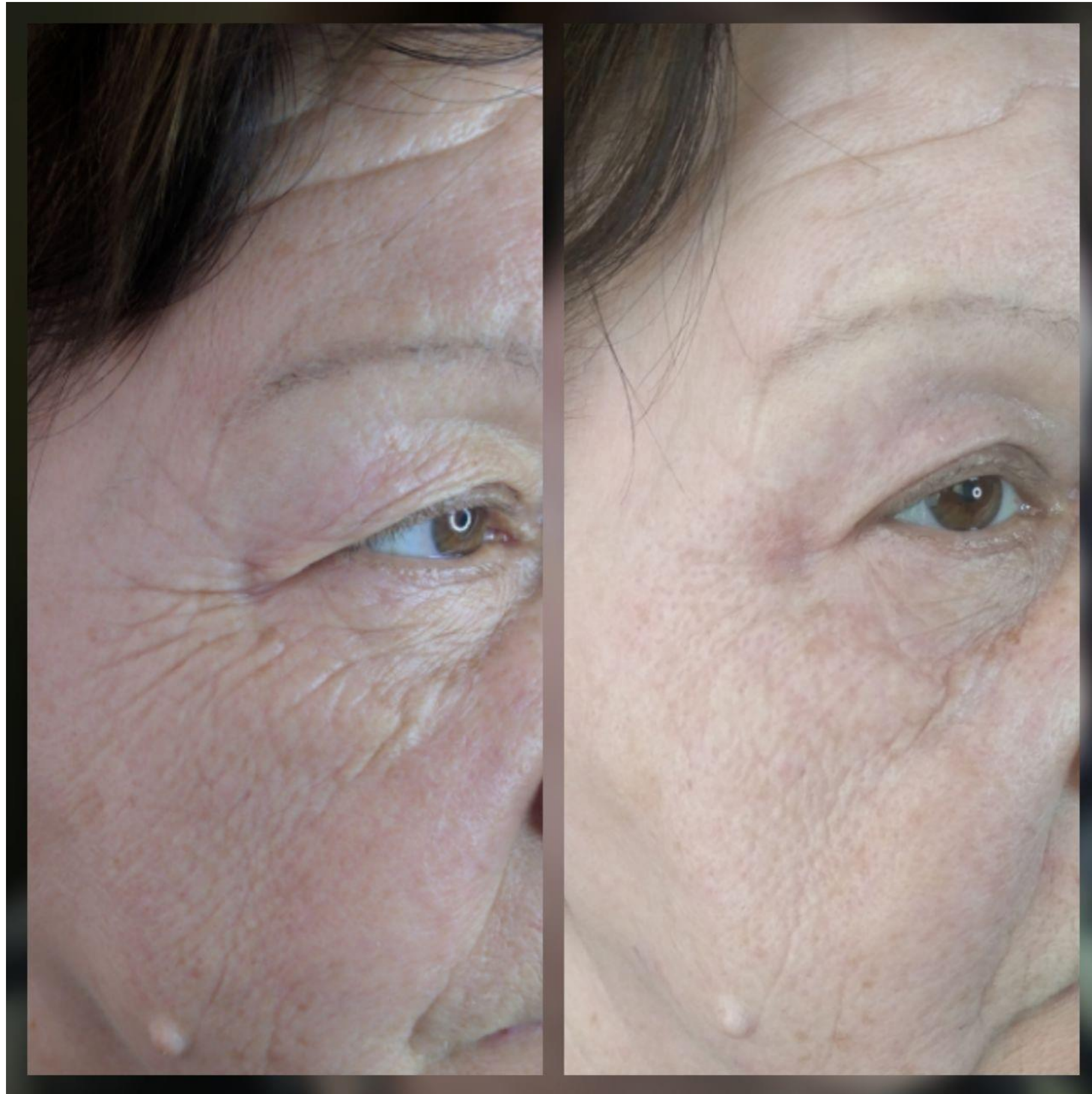Blefaroplasma and fine lines

- with the courtesy of Oxygen, Tbilissi Georgia
- Crows feet
- after 1 session, 3 weeks later

PLASMA[®]GE

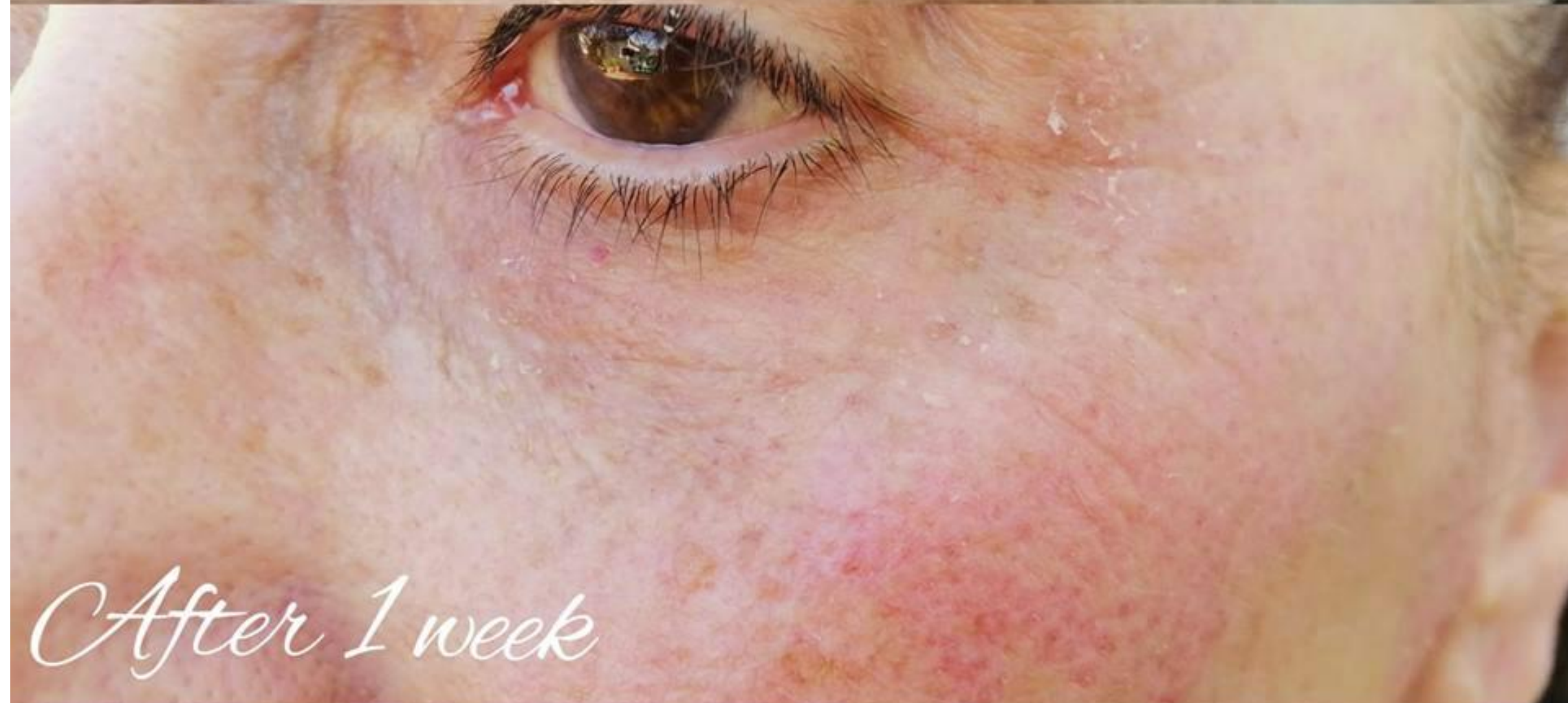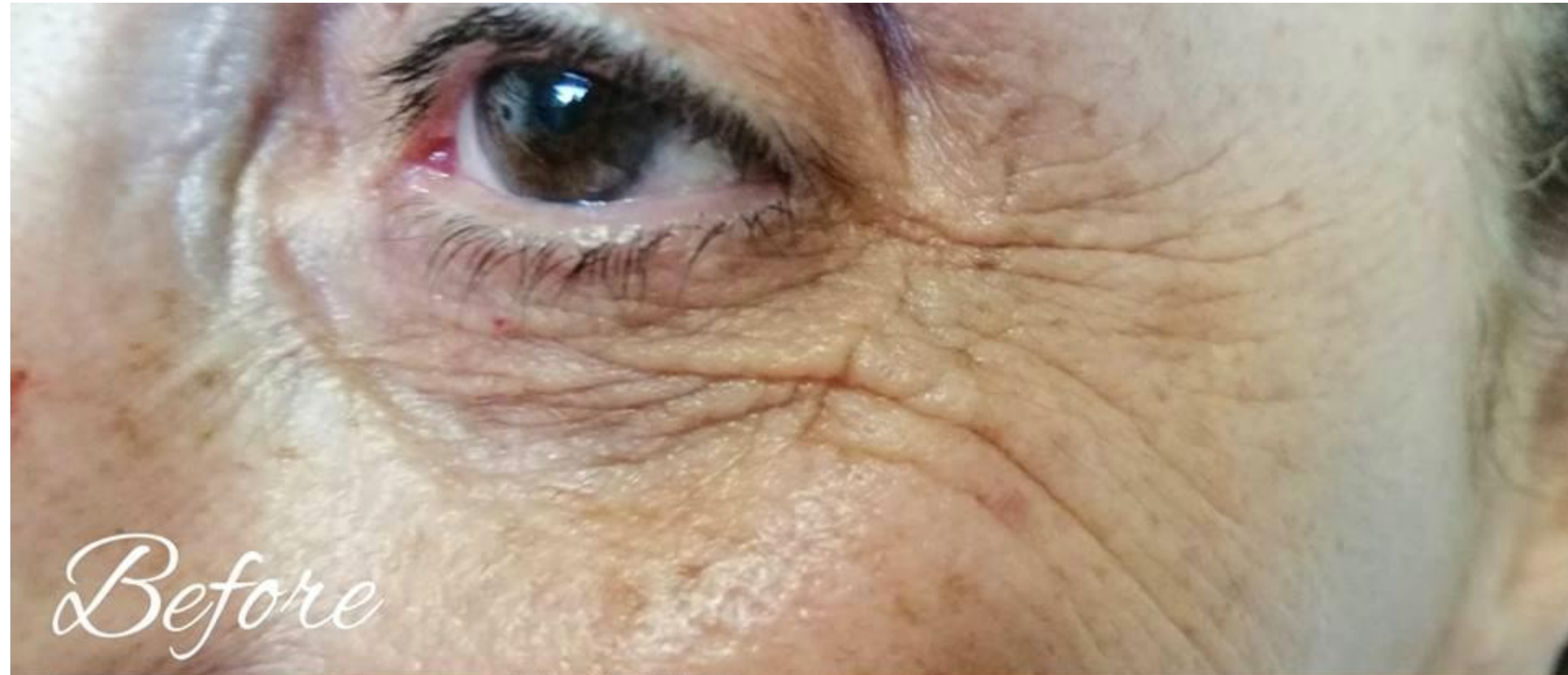Blefaroplasma and fine lines

- with the courtesy of Beauty Studio Clinic, Tbilissi Georgia
- Crows feet
- after 1 session, 1 month later



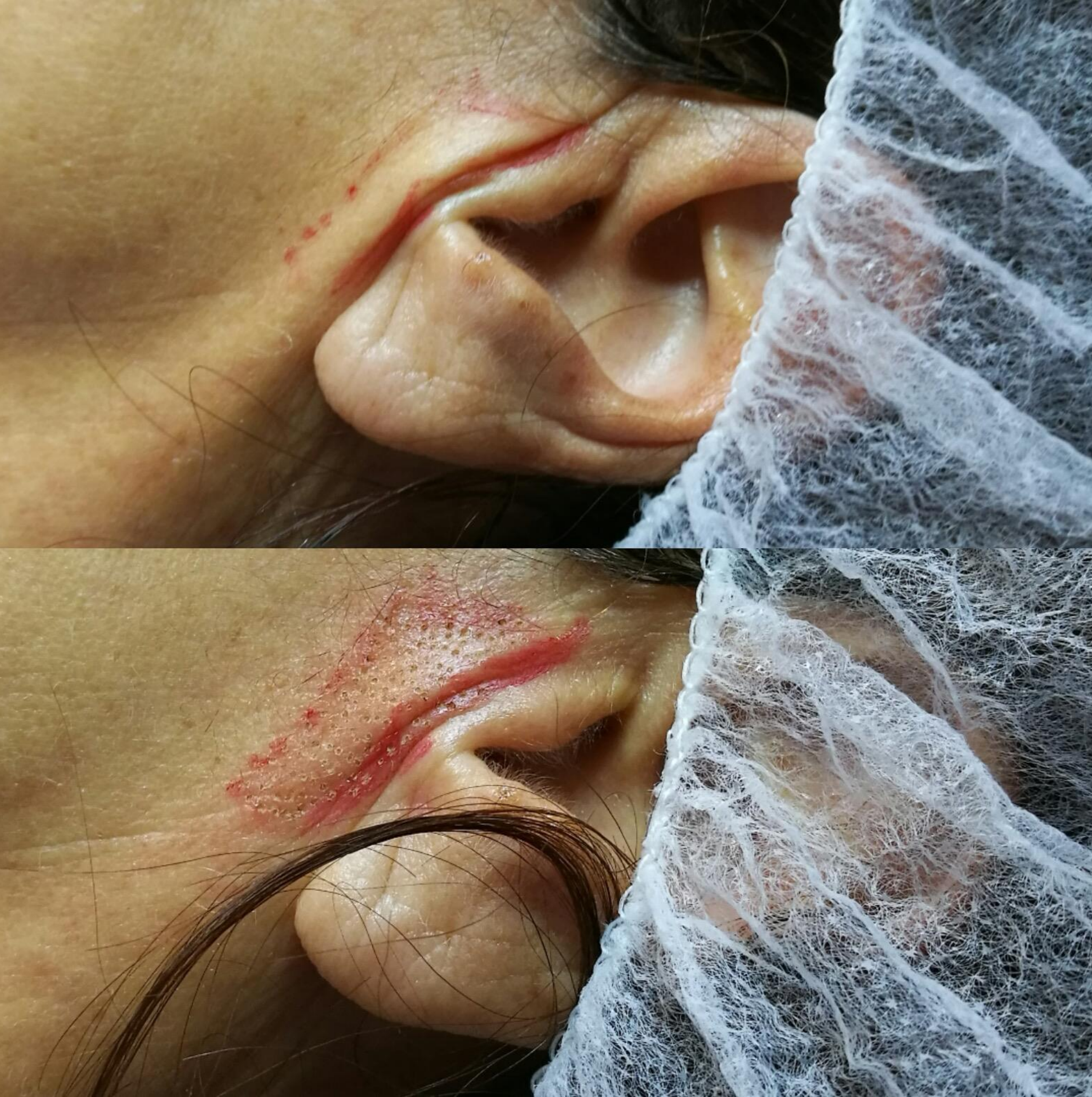PLASMA[®]

Blefaroplasma[®]



- with the courtesy of Dr Silvia Weber, Beyrouth Lebanon
- 1 session: before and after one month

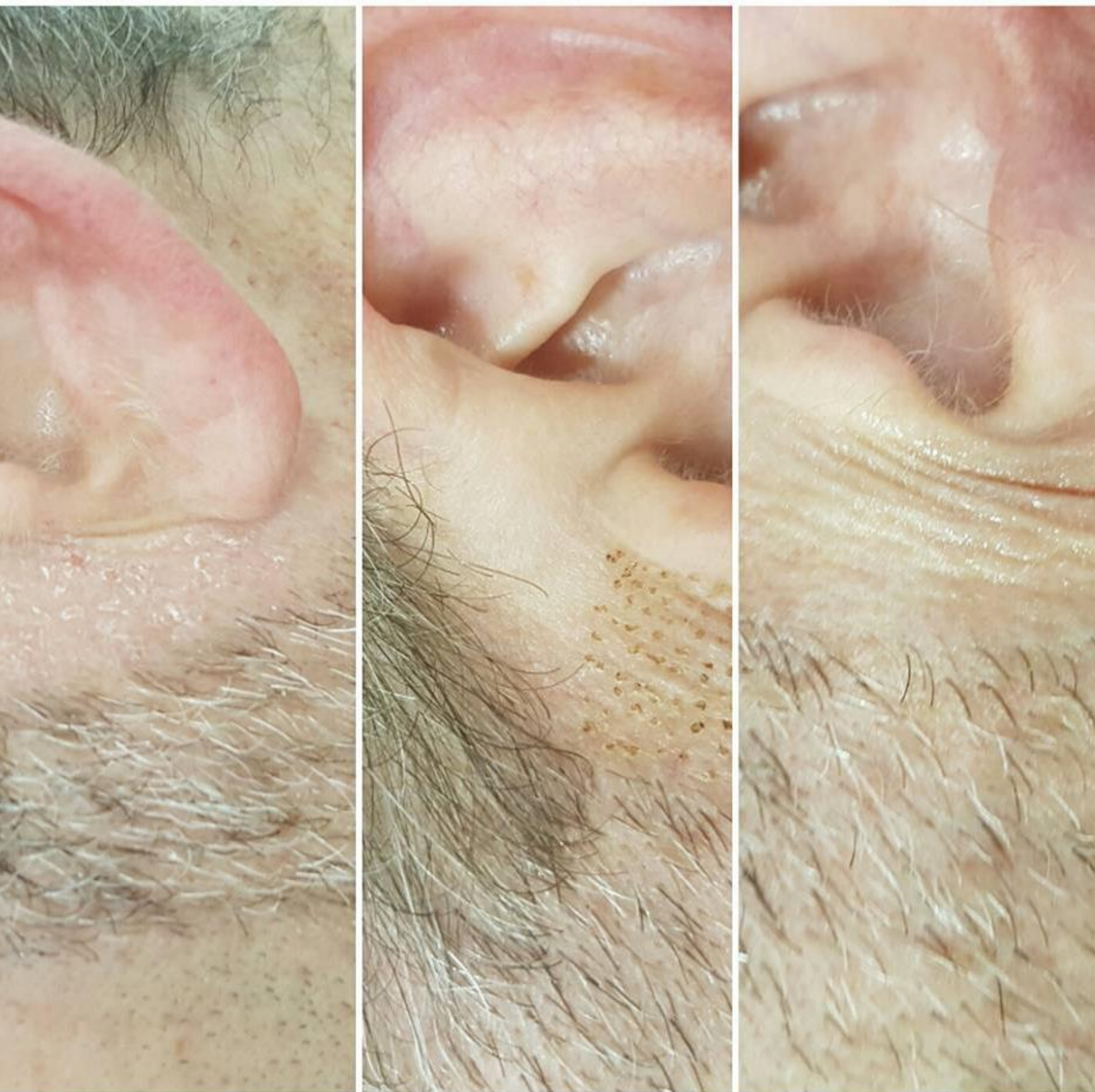brera[®]
medical technologies



PLASMA[®]GE

Lifting

- with the courtesy of Dr. Jose Condreras, Madrid, Spain
- 1 session: before, right after the treatment
- Purpose of plasma: skin retraction



PLASMAGE®

wrinkles

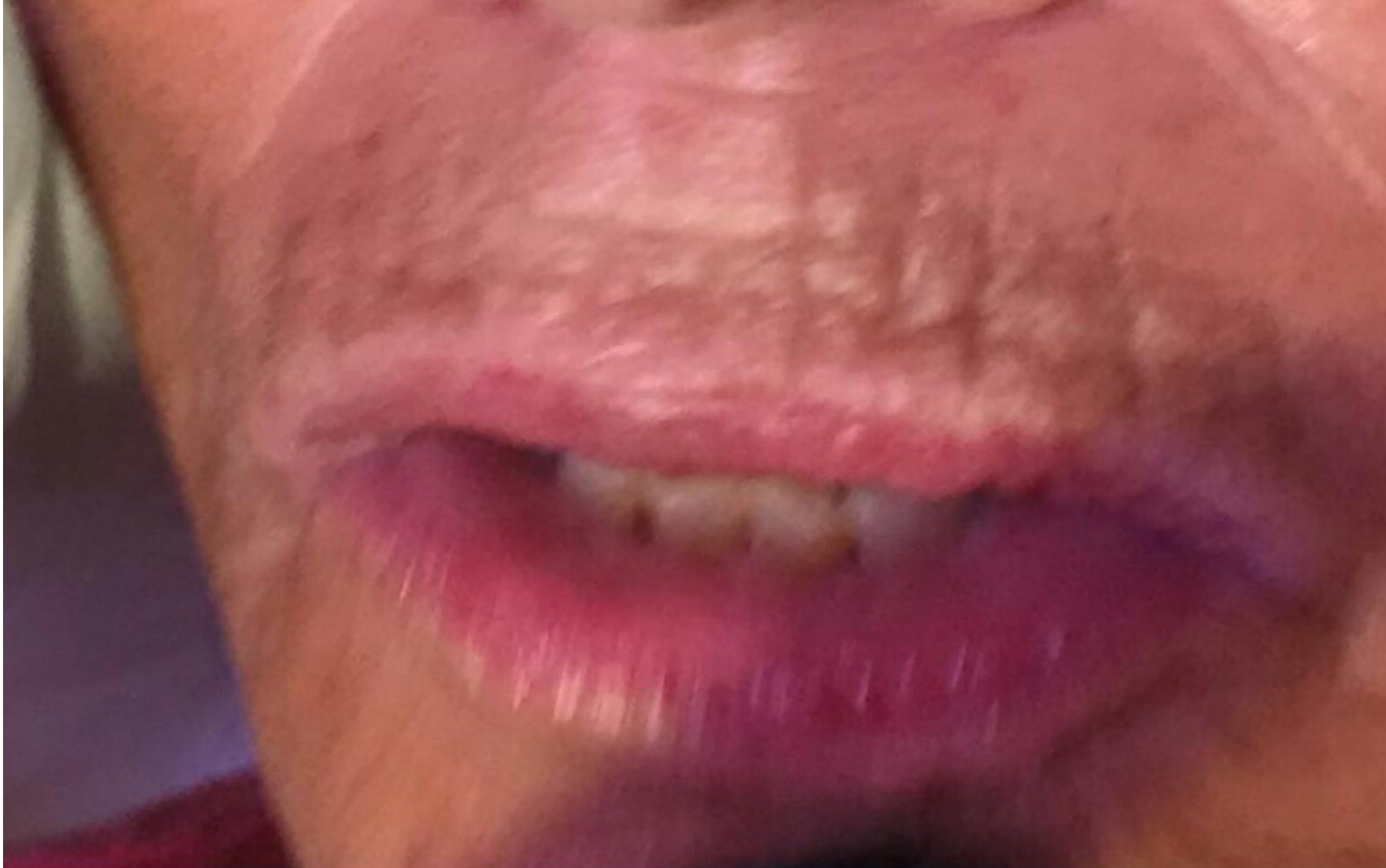- with the courtesy of Dr. Eyal Kramer, Tel Aviv Israel
- 1 session: after, right after the treatment, before
- wrinkles treatment



PLASMA[®]GE

Perioral area / lip lift

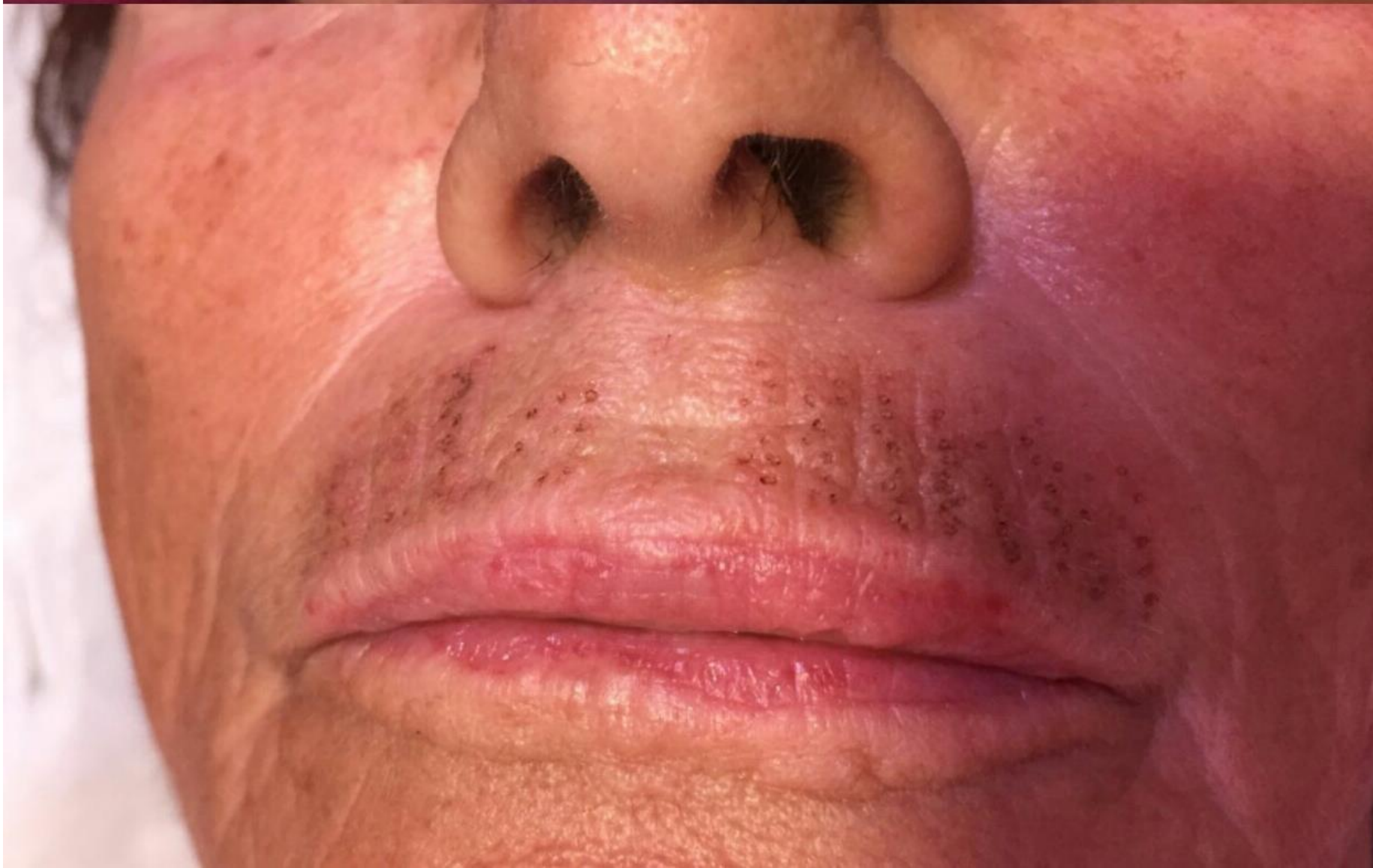brera[®]
medical technologies



PLASMAGE®

Wrinkles,
barcode

- with the courtesy of Dr. Jose Condreras, Madrid, Spain
- 1 session: before, right after the treatment



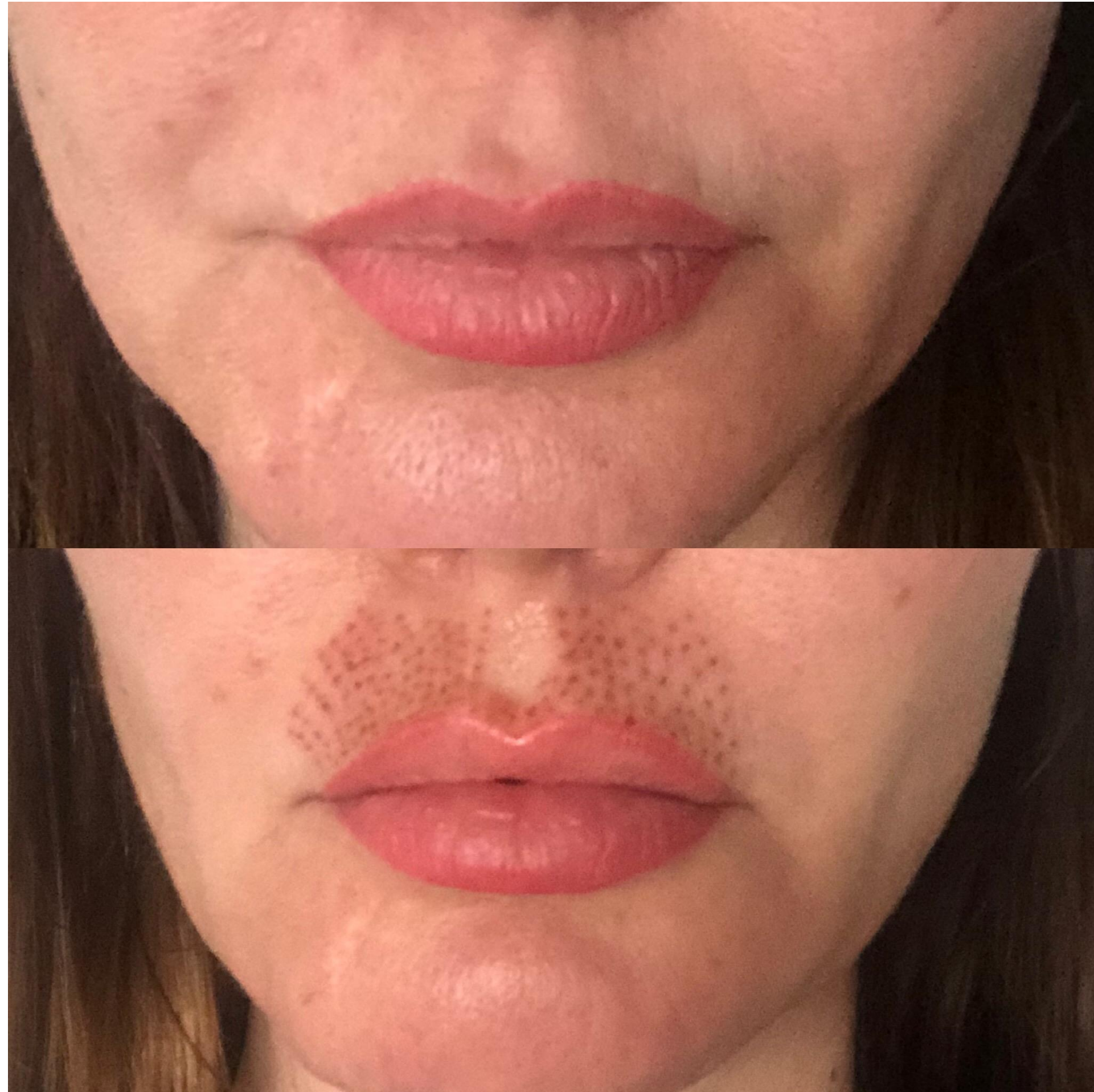

PLASMA^{AGE}

Wrinkles,
barcode

- with the courtesy of Dr. Shirin Samimi Fard, Gladbeck Germany
- 1 session: before and one month later. Upper lips with fraxel repair and chin treated with blepharoplasma settings

PLASMA^{AGE}

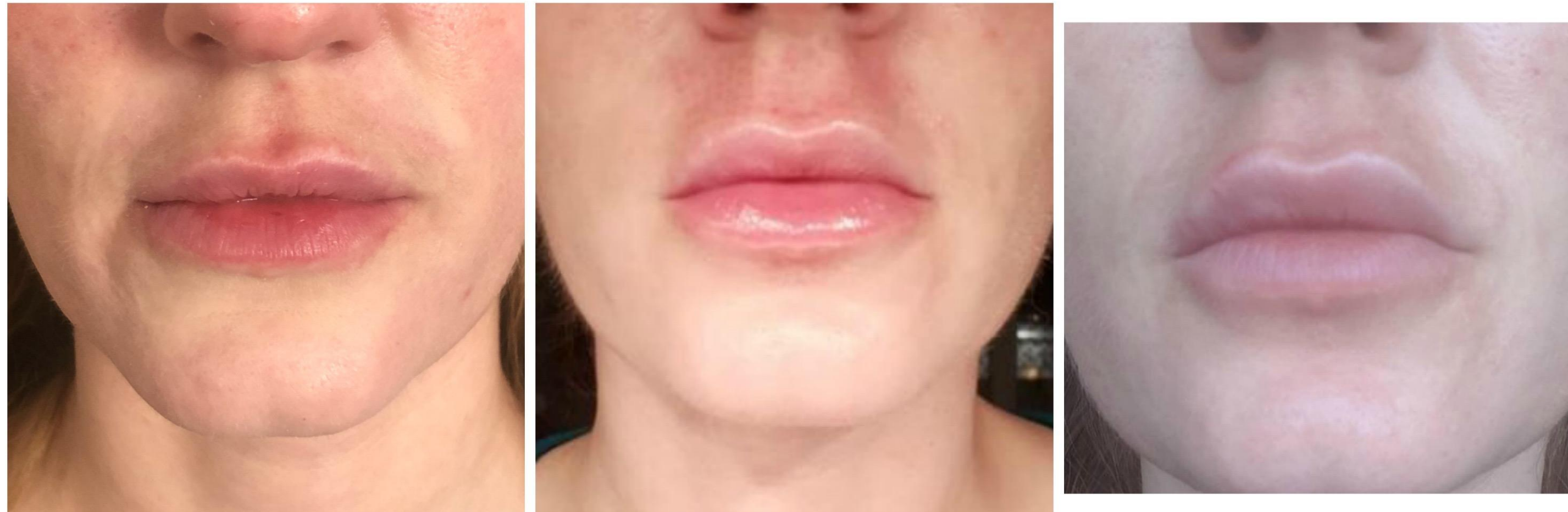


Wrinkles,
barcode

- with the courtesy of Keri Ann Eik, Norway
- immediate lip lift

PLASMA[®]GE

Wrinkles,
barcode



- with the courtesy of Keri Ann Eik, Norway
- 1 session, before, one week and three weeks later

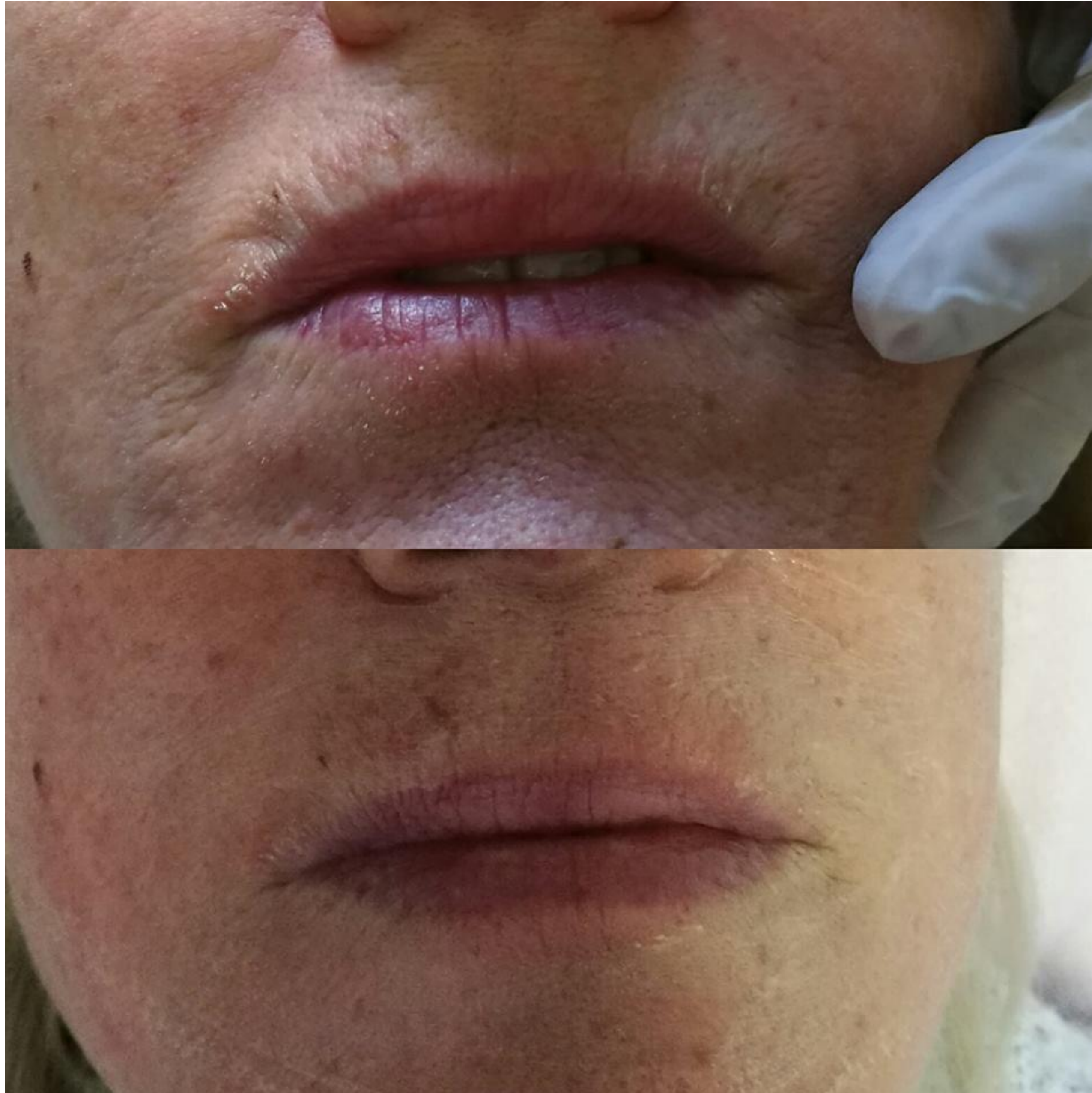

PLASMA[®]GE

Resurfacing with plasma peel

No anesthesia needed

Suitable for every skin type

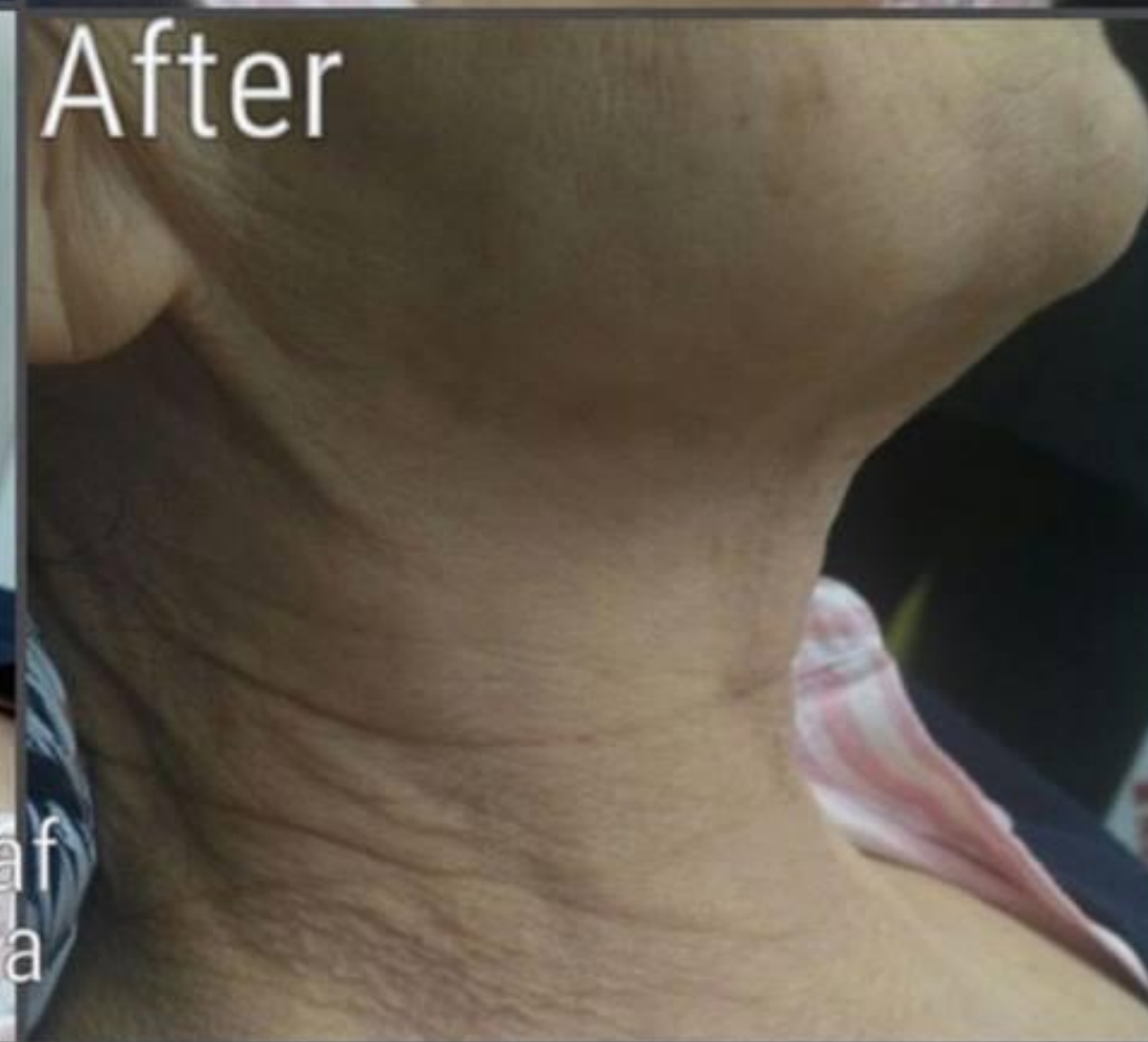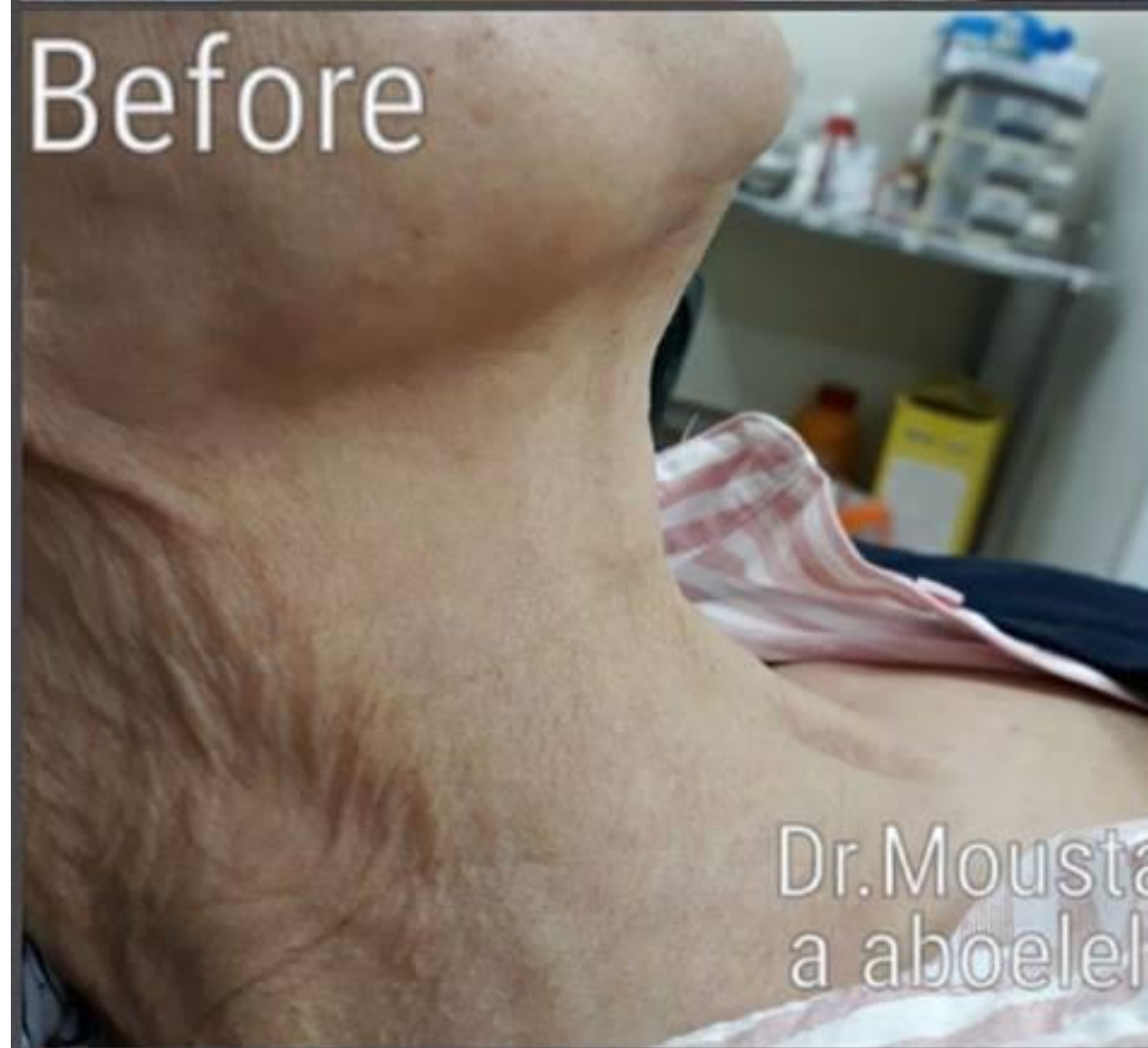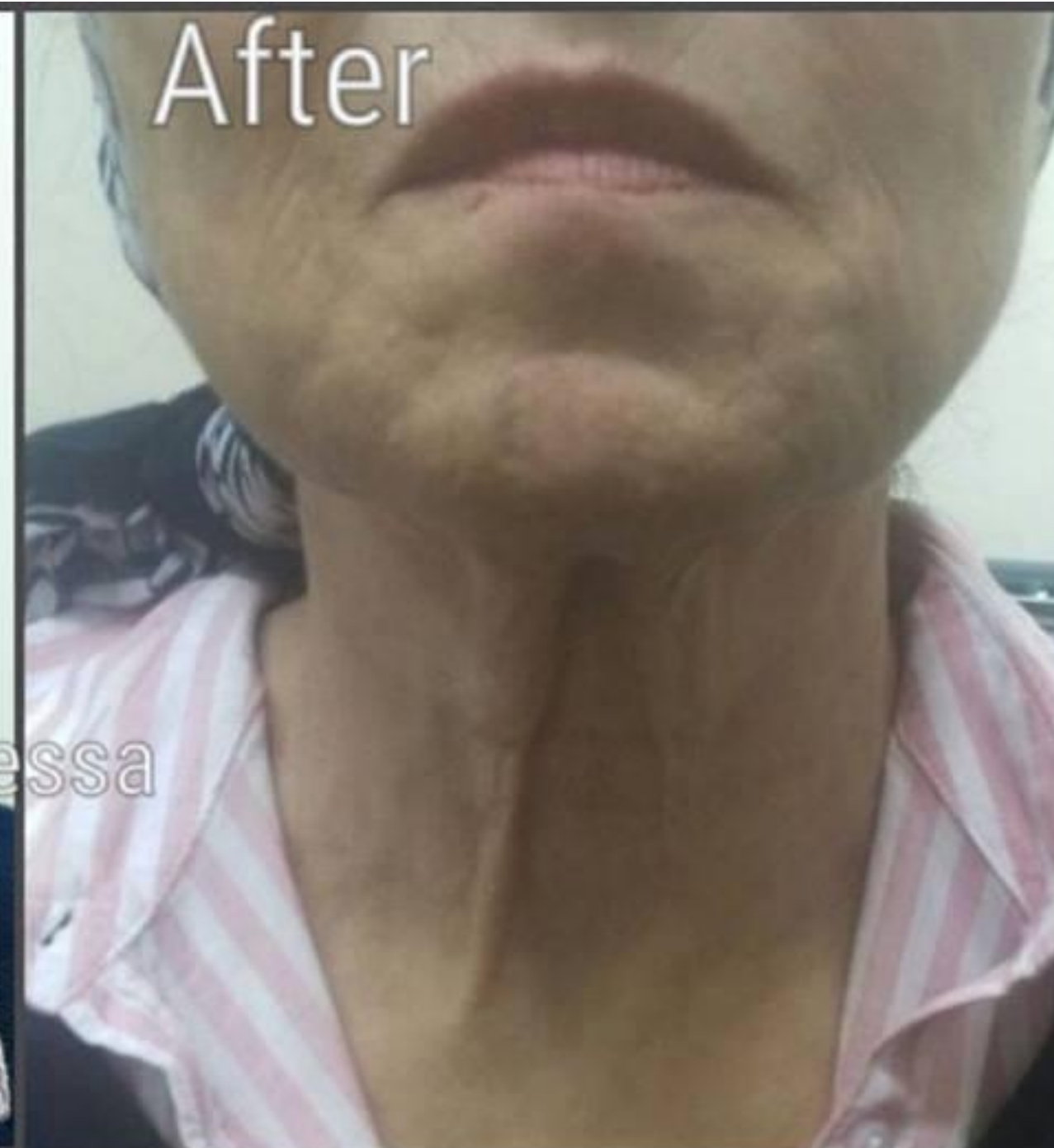


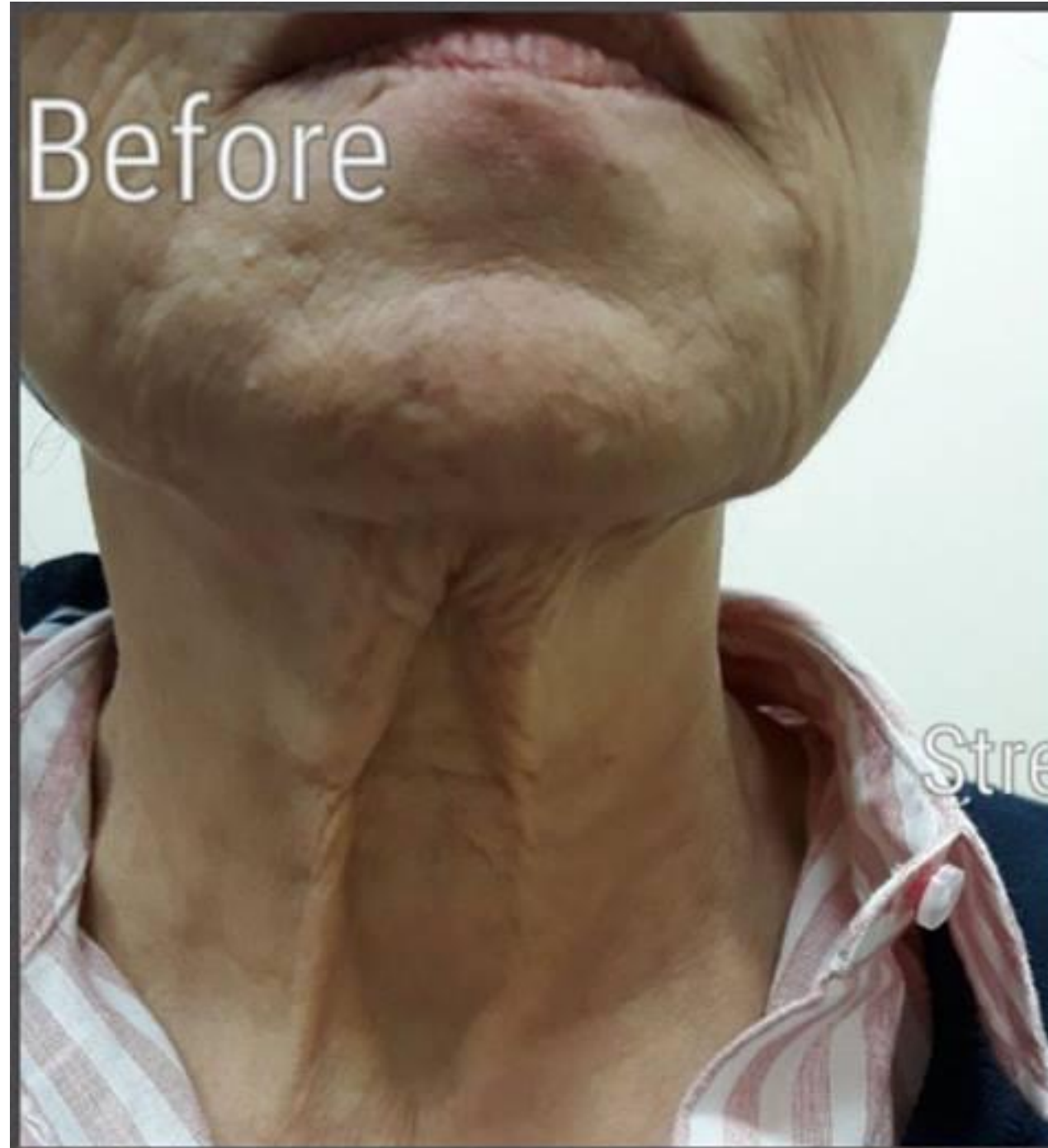PLASMA[®]GE

Smoker lines with resurfacing

- with the courtesy of Dr Eleftheria Gliarmi, Athens, Greece

- 1 session: before, right after with resurfacing, 15 minutes treatment



PLASMA[®]GE

Neck with resurfacing

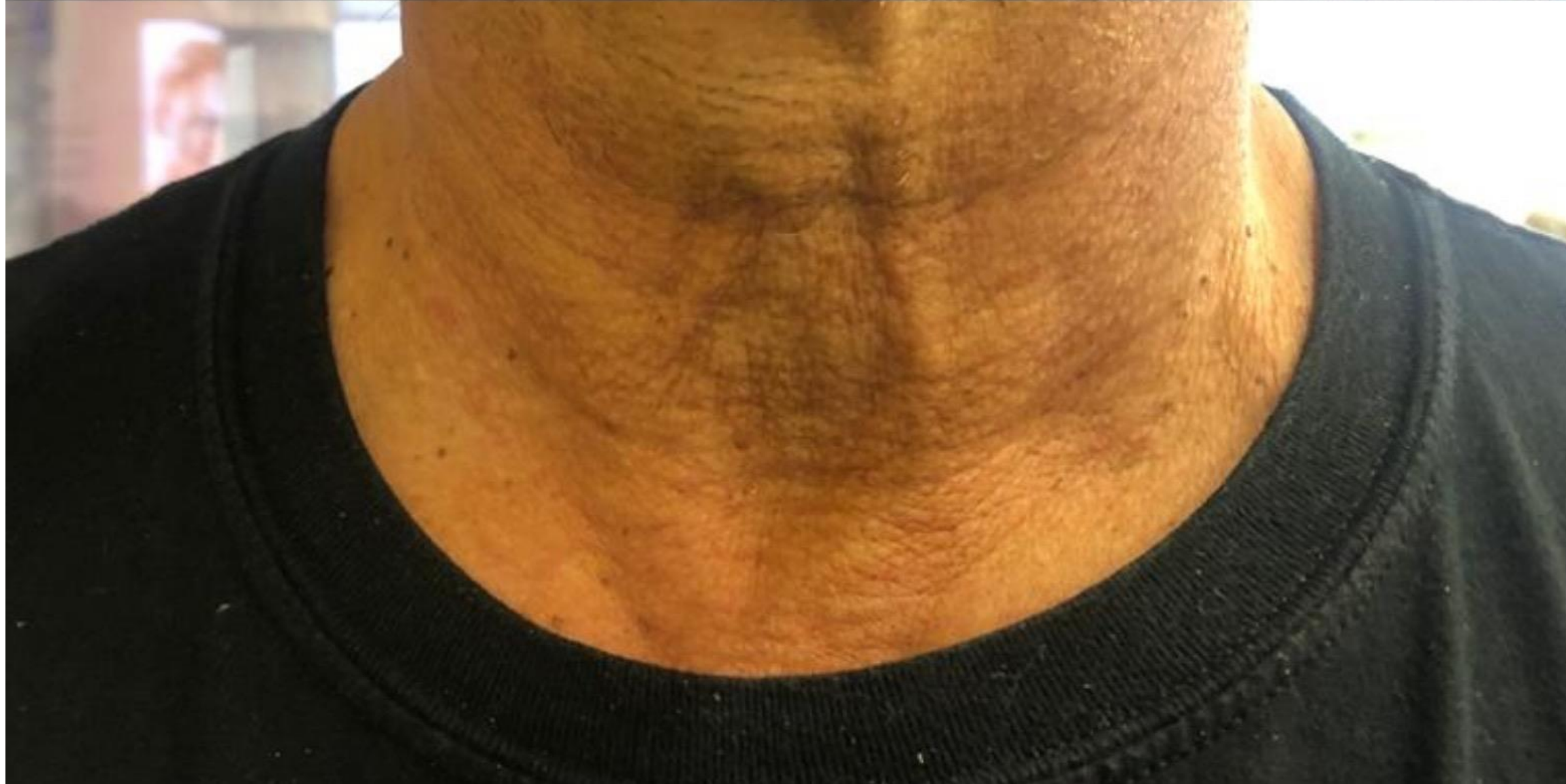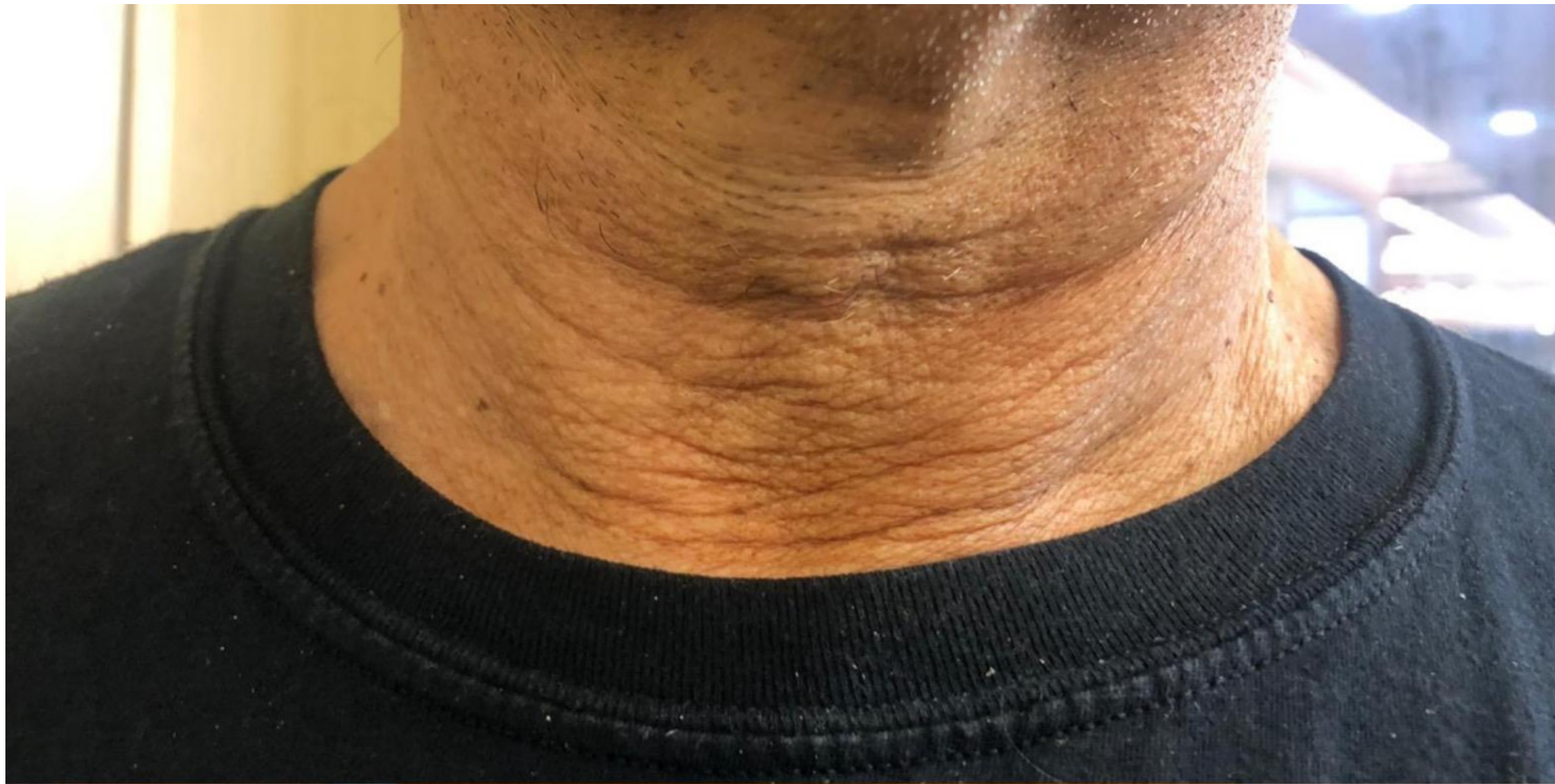- with the courtesy of Stressa Healthcare, Egypt
- 5 sessions: before after

PLASMA[®]GE

Neck with resurfacing

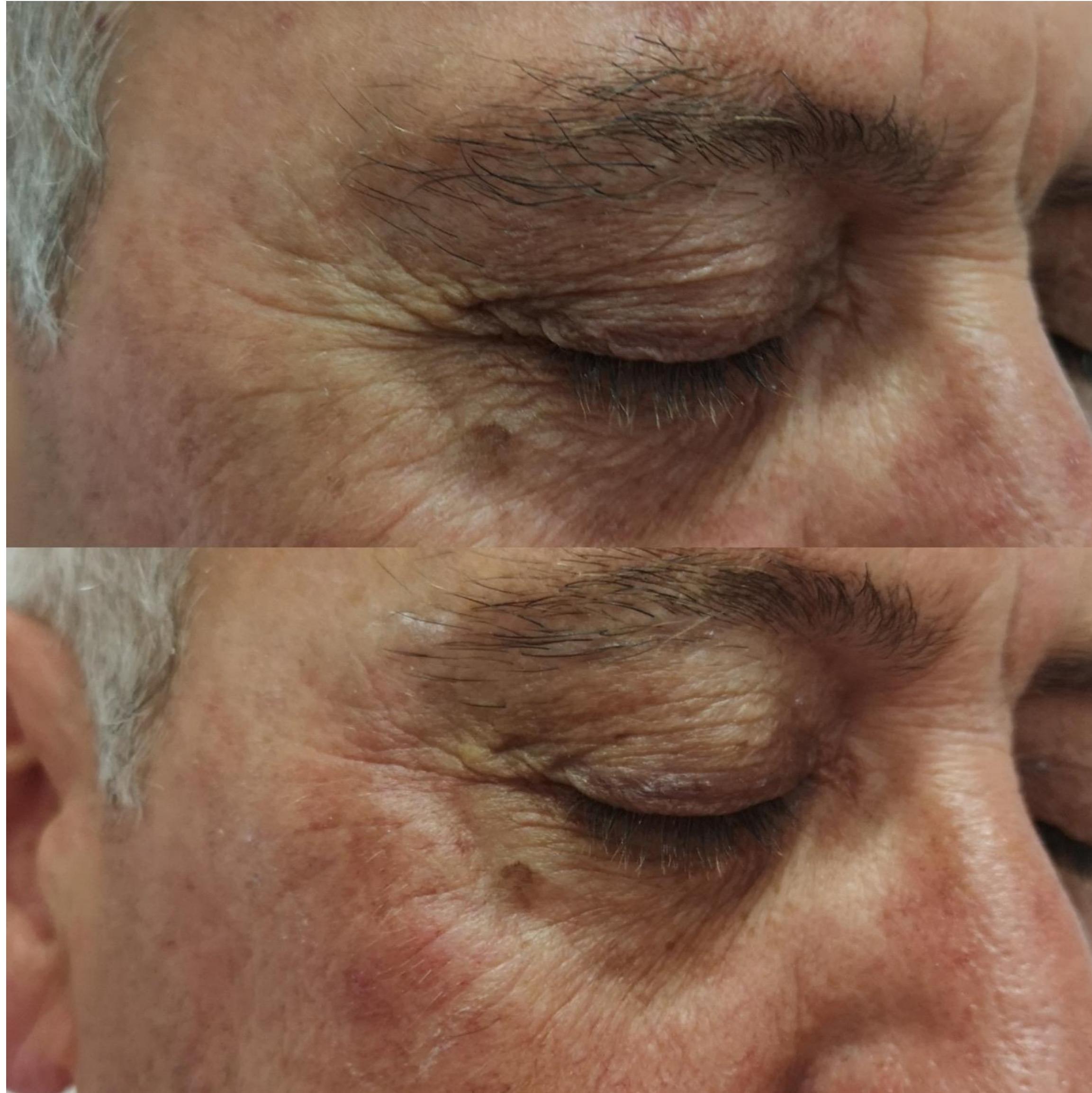- with the courtesy of Soling, Russia

- 1 session, right after the treatment



PLASMA^{AGE}

lower eyelid and crows feet with resurfacing



- with the courtesy of Medpro, Brazil
- 1 session, right after the treatment of 5 minutes



PLASMA[®]GE

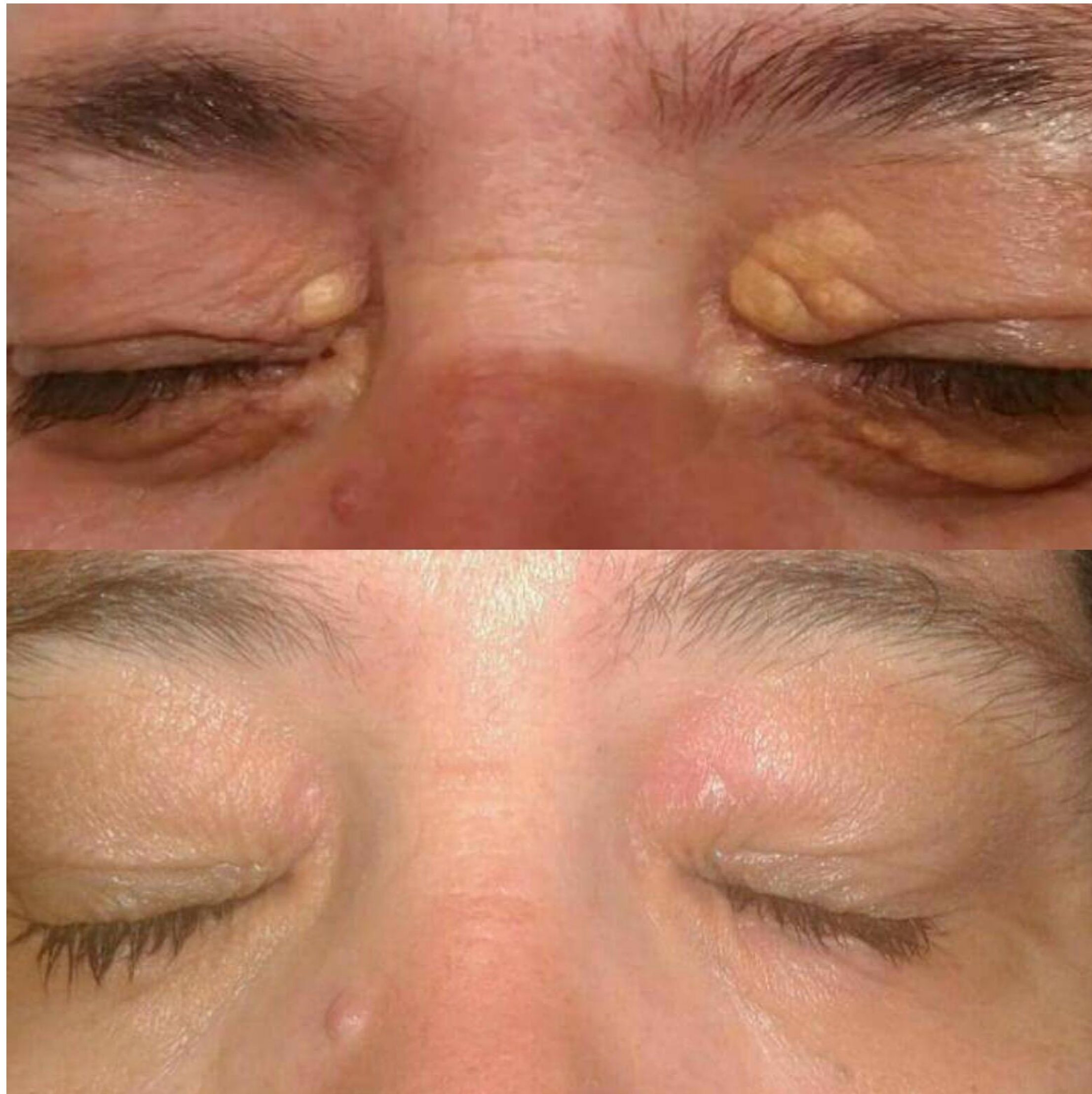The new tool for dermatology
and aesthetic medicine:

- Fibromas
- Xanthelasma, siringomas
- Warts
- Benign lesions

PLASMA[®]GE

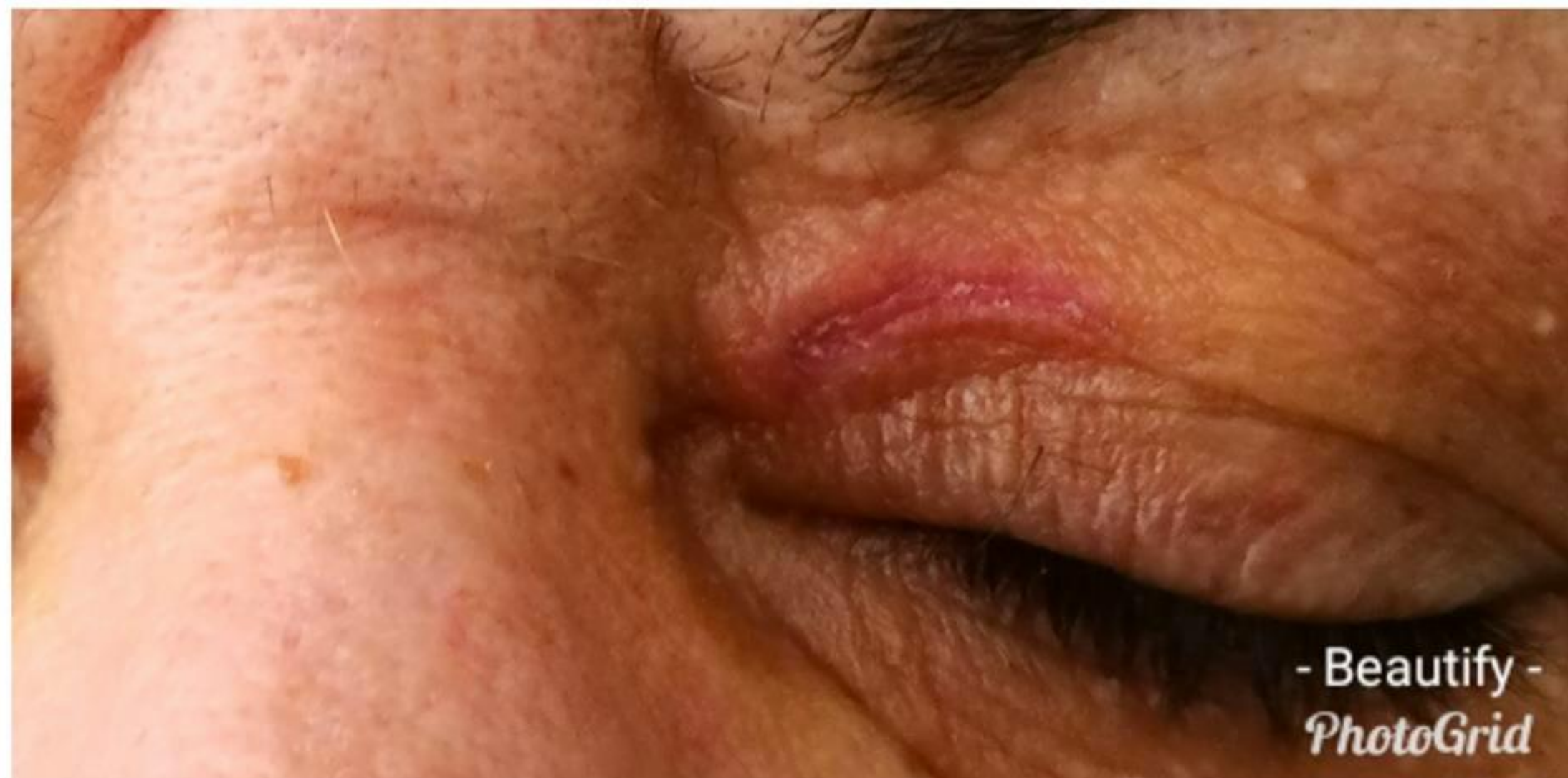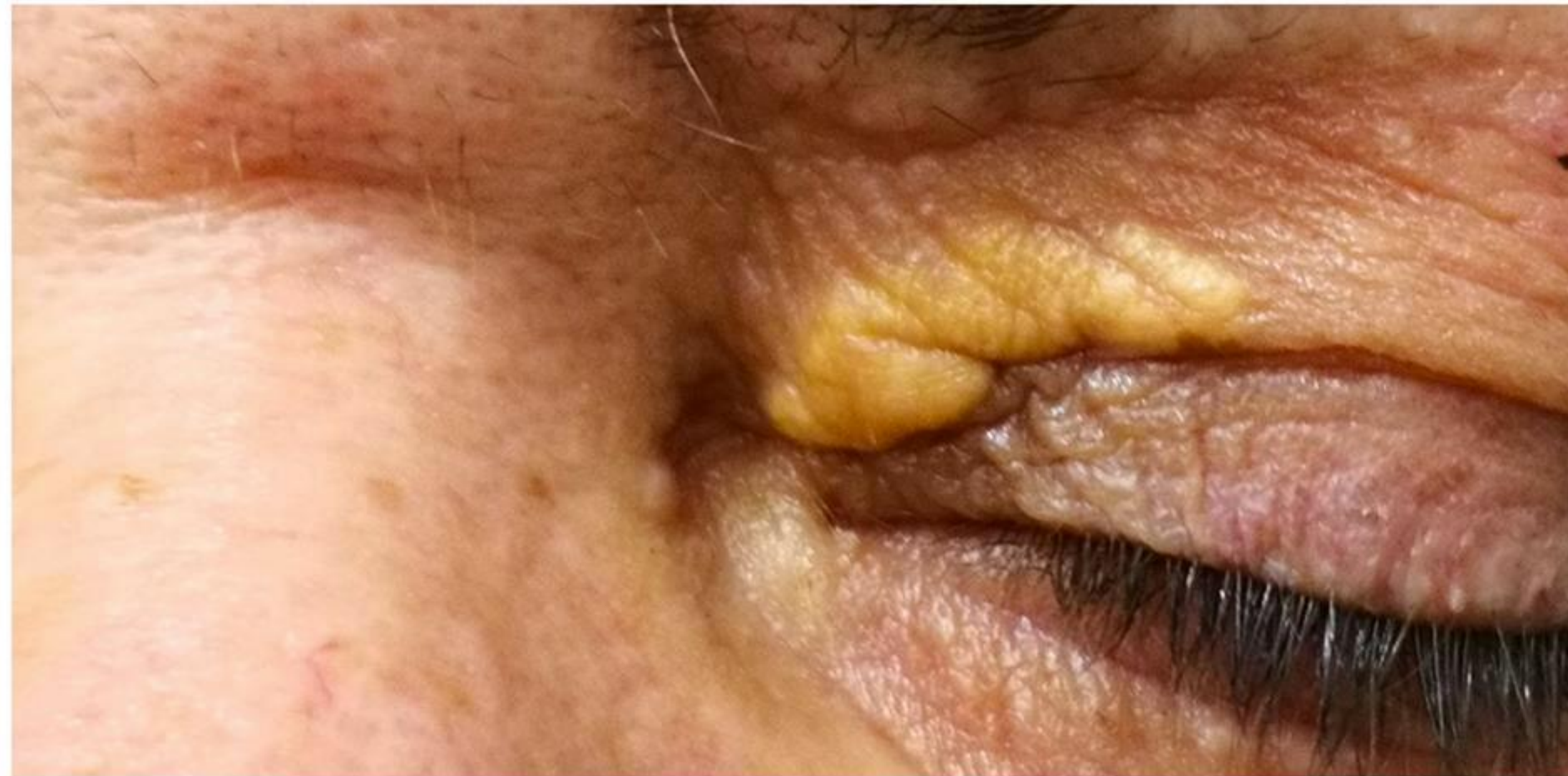Xanthelasma

- 1 session: before and after one month



PLASMA[®]GE

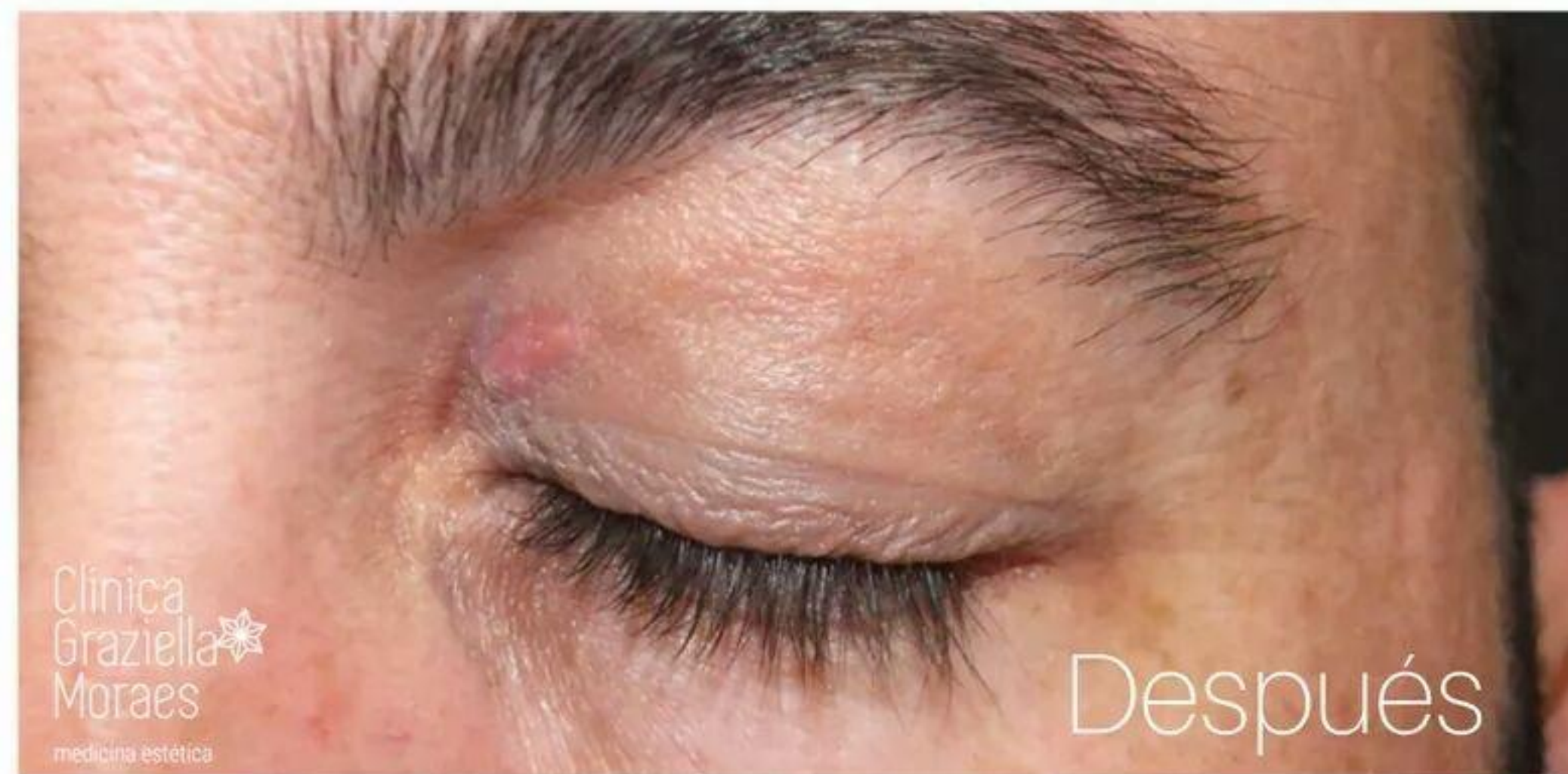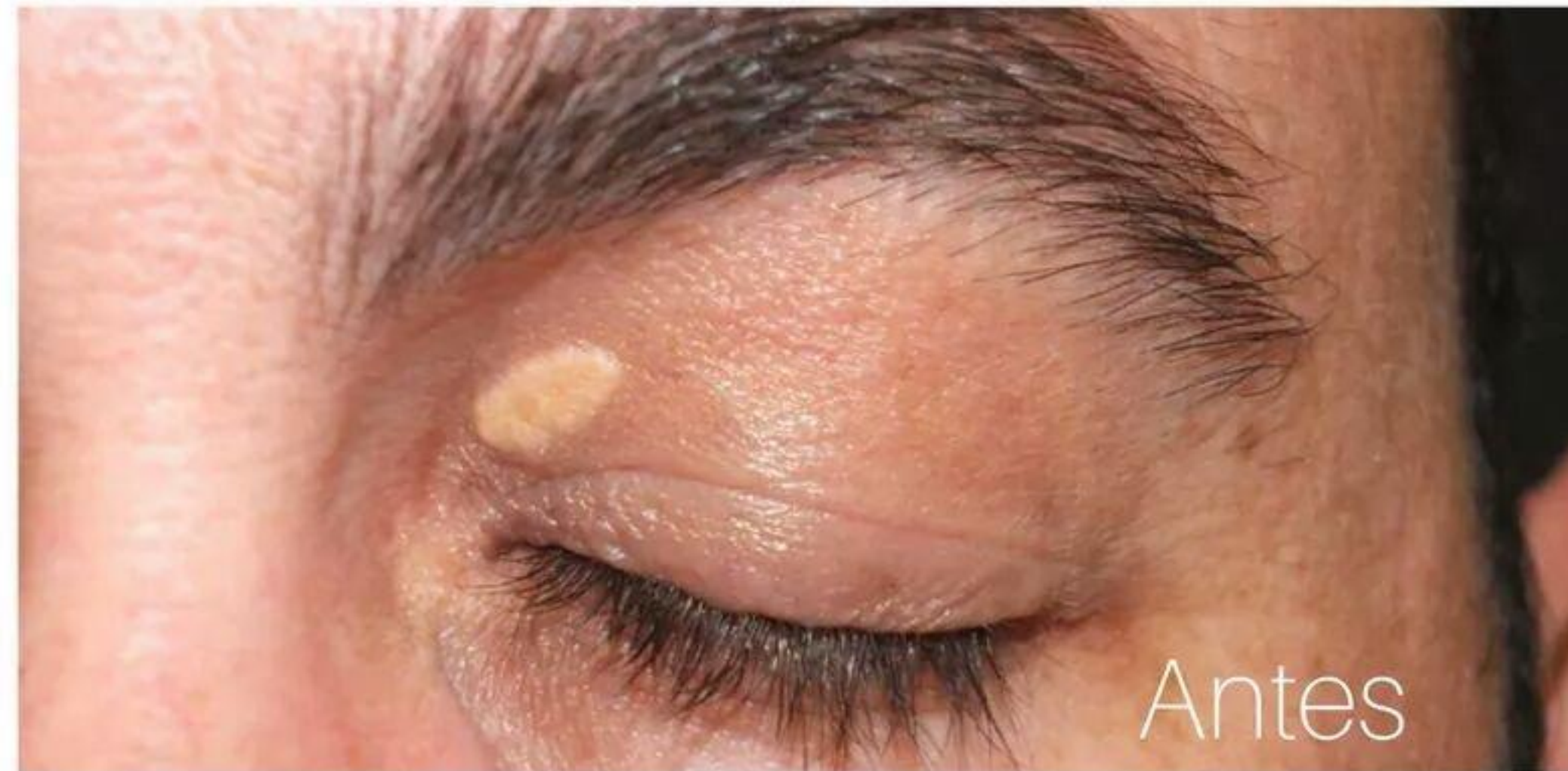Xanthelasma



- 1 session: before and after one month
- with the courtesy from Oxygen, Tbilissi Georgia
- before and after 2 weeks

PLASMA[®]GE

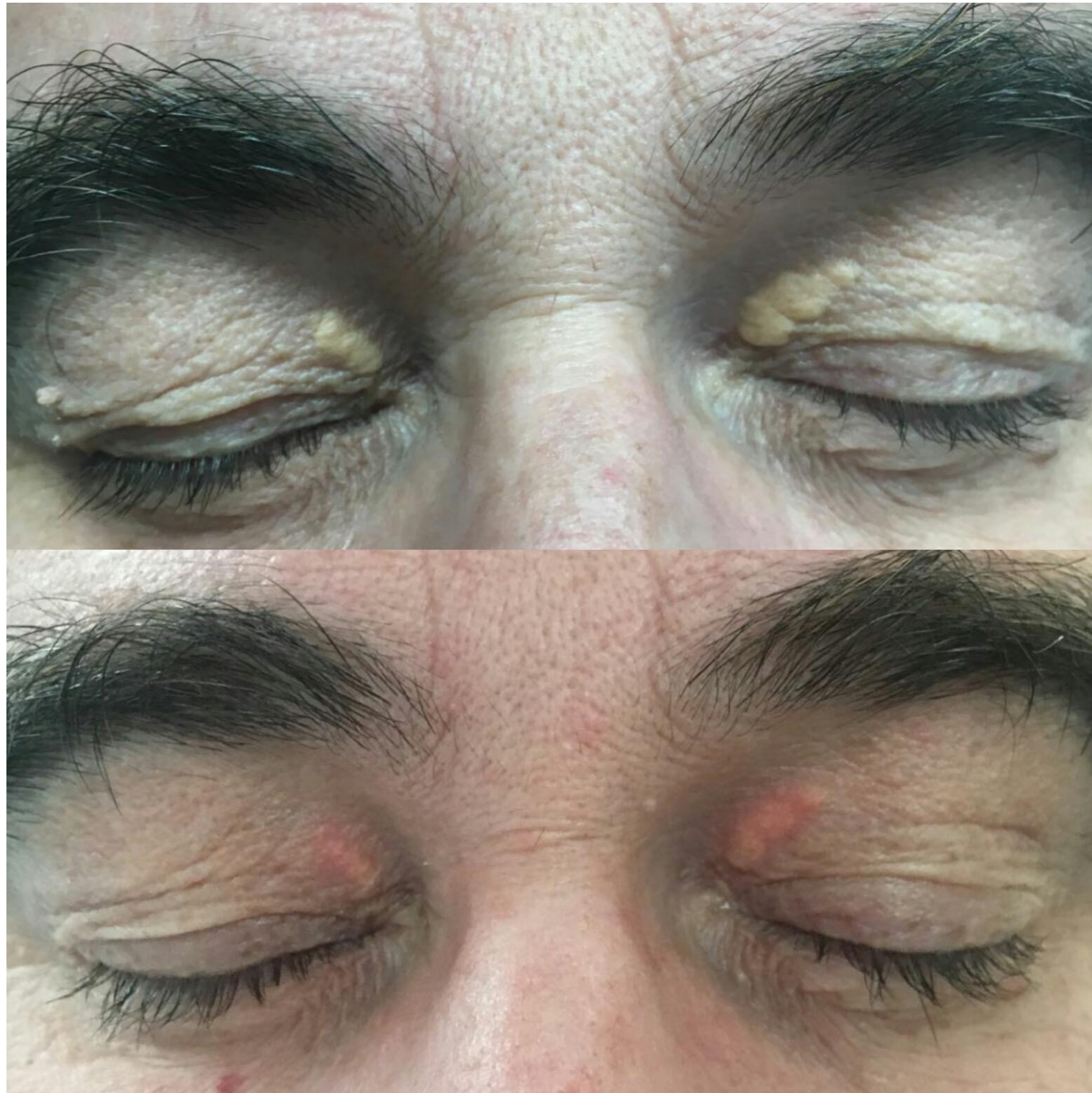Xanthelasma



- with the courtesy of Dr Graziella MORAES, Vigo Spain
- after 1 session, 10 days later

PLASMA[®]GE

Xanthelasma

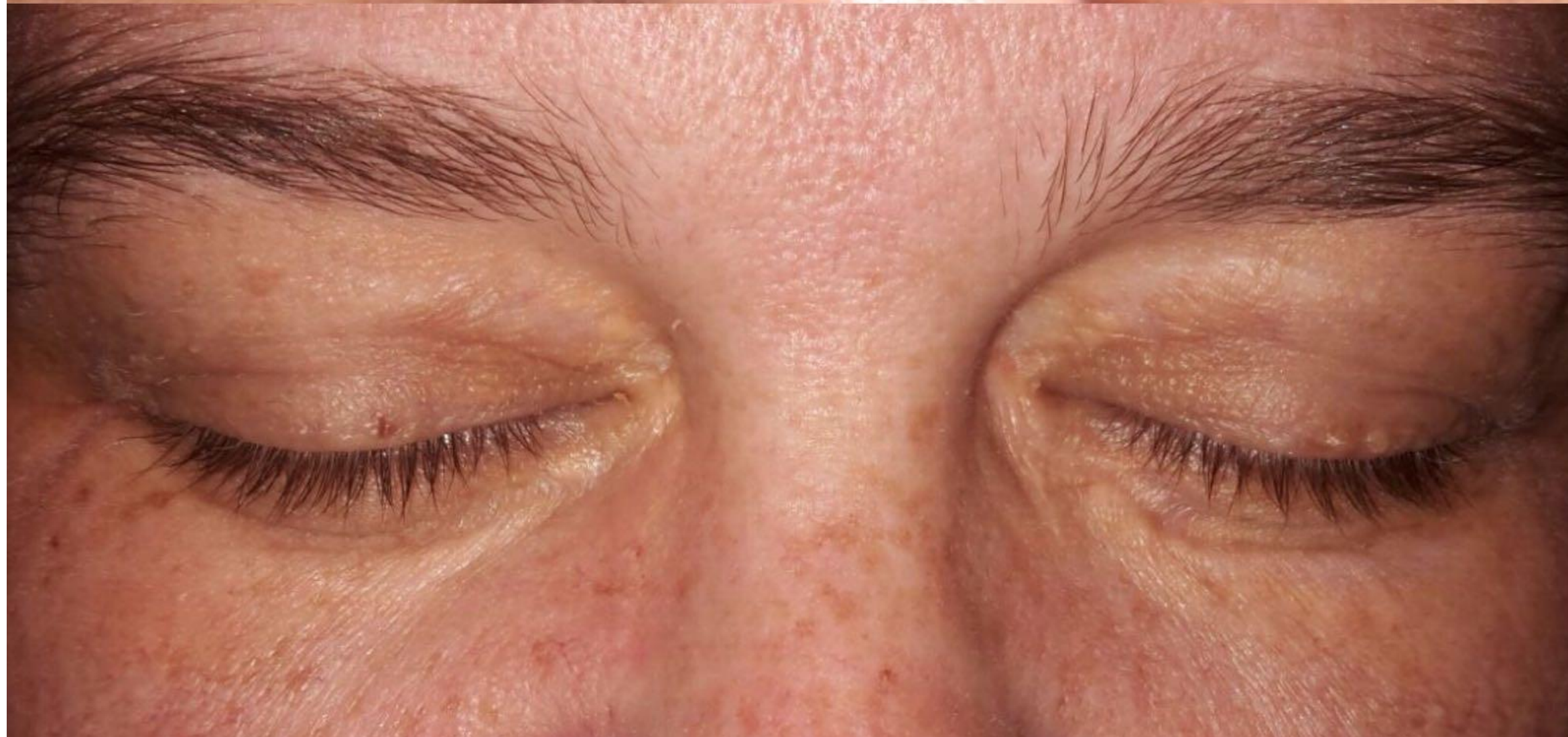
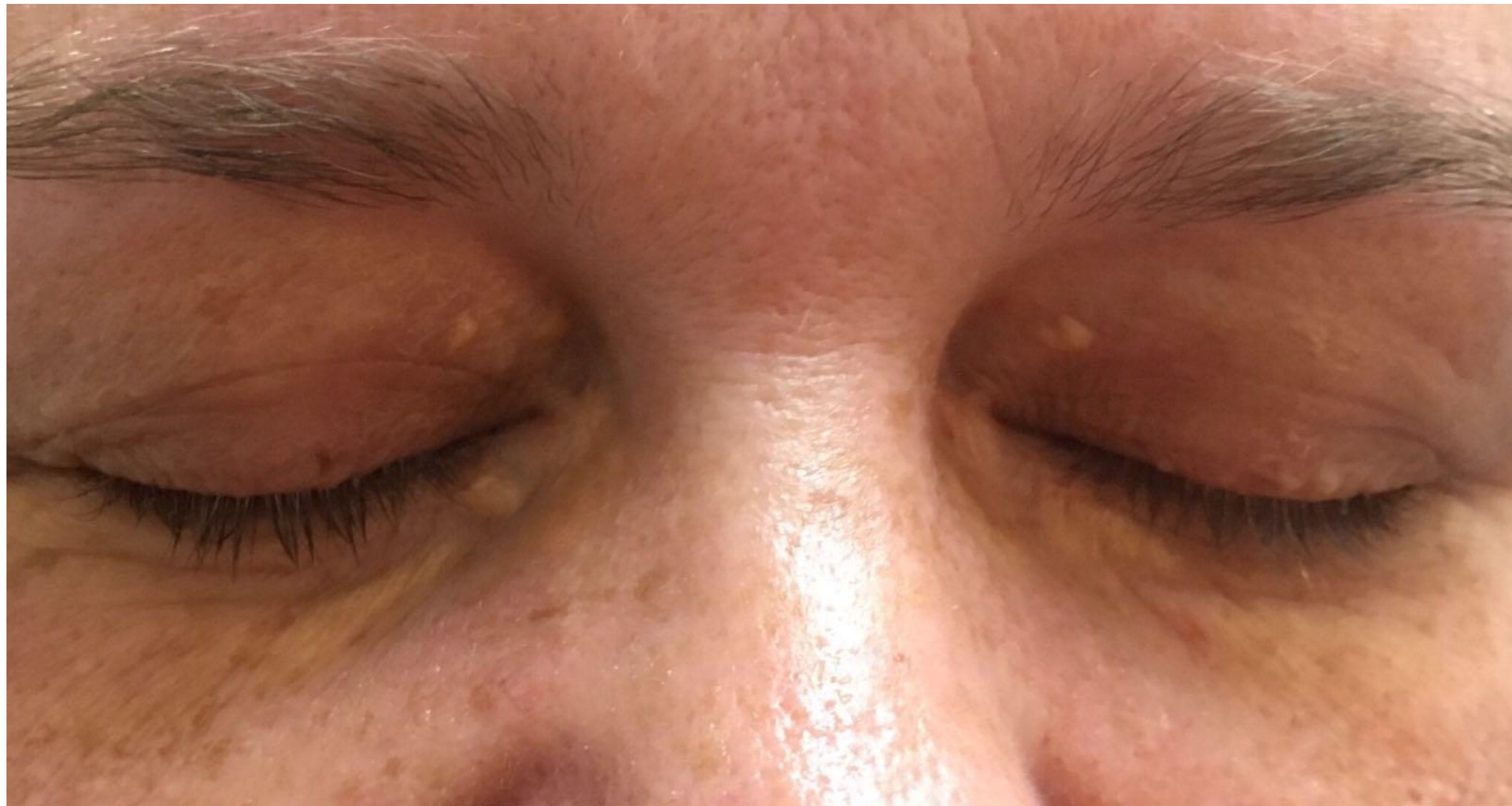
➤ after 1 session, 10 days later

PLASMA[®]GE

Xanthelasma

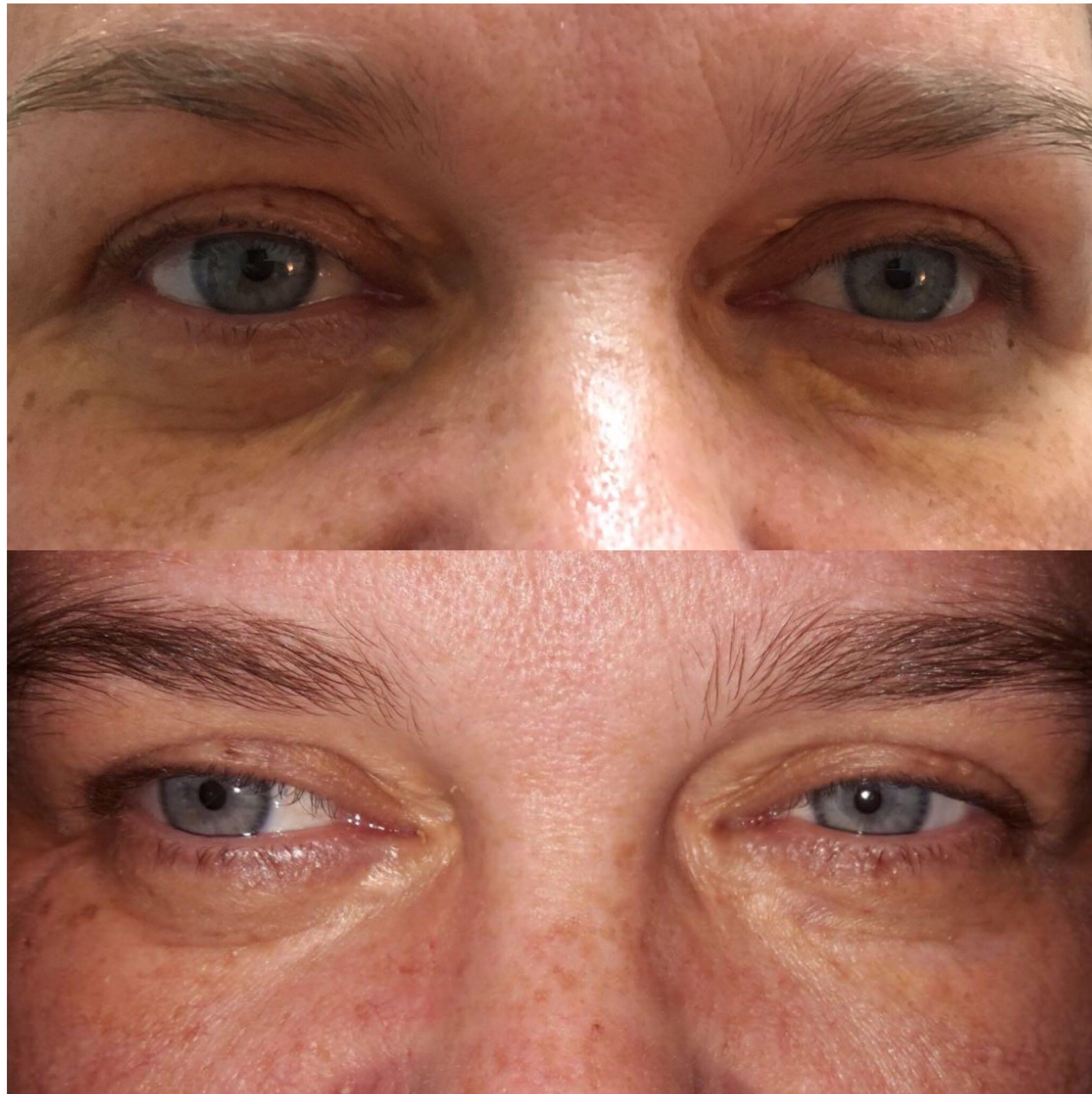- with the courtesy of Dr Nikola Milojevic, Zagreb Croatia
- 1 session: before and after two months



PLASMA[®]GE

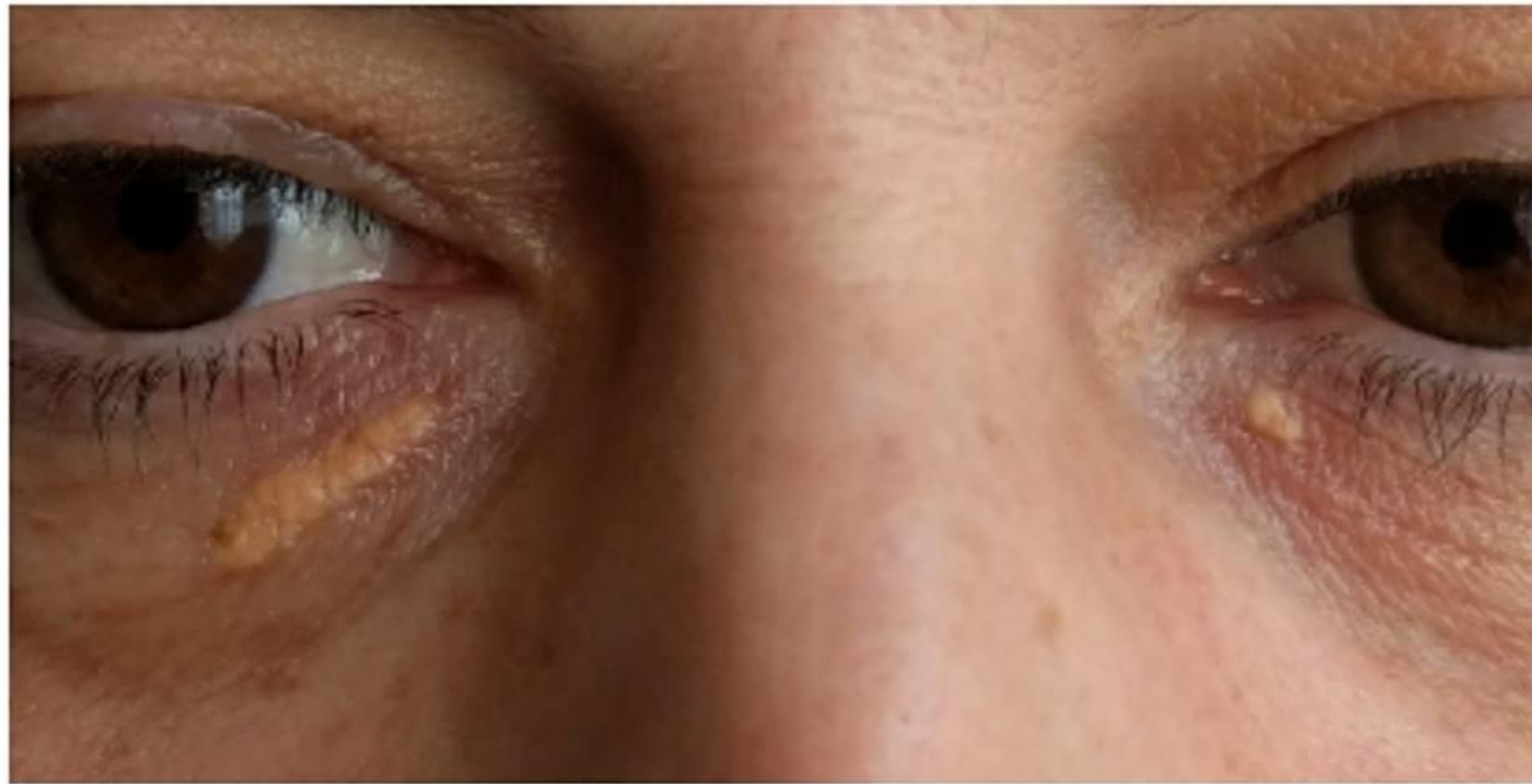Xanthelasma

- with the courtesy of Dr Nikola Milojevic, Zagreb Croatia
- 1 session: before and after two months

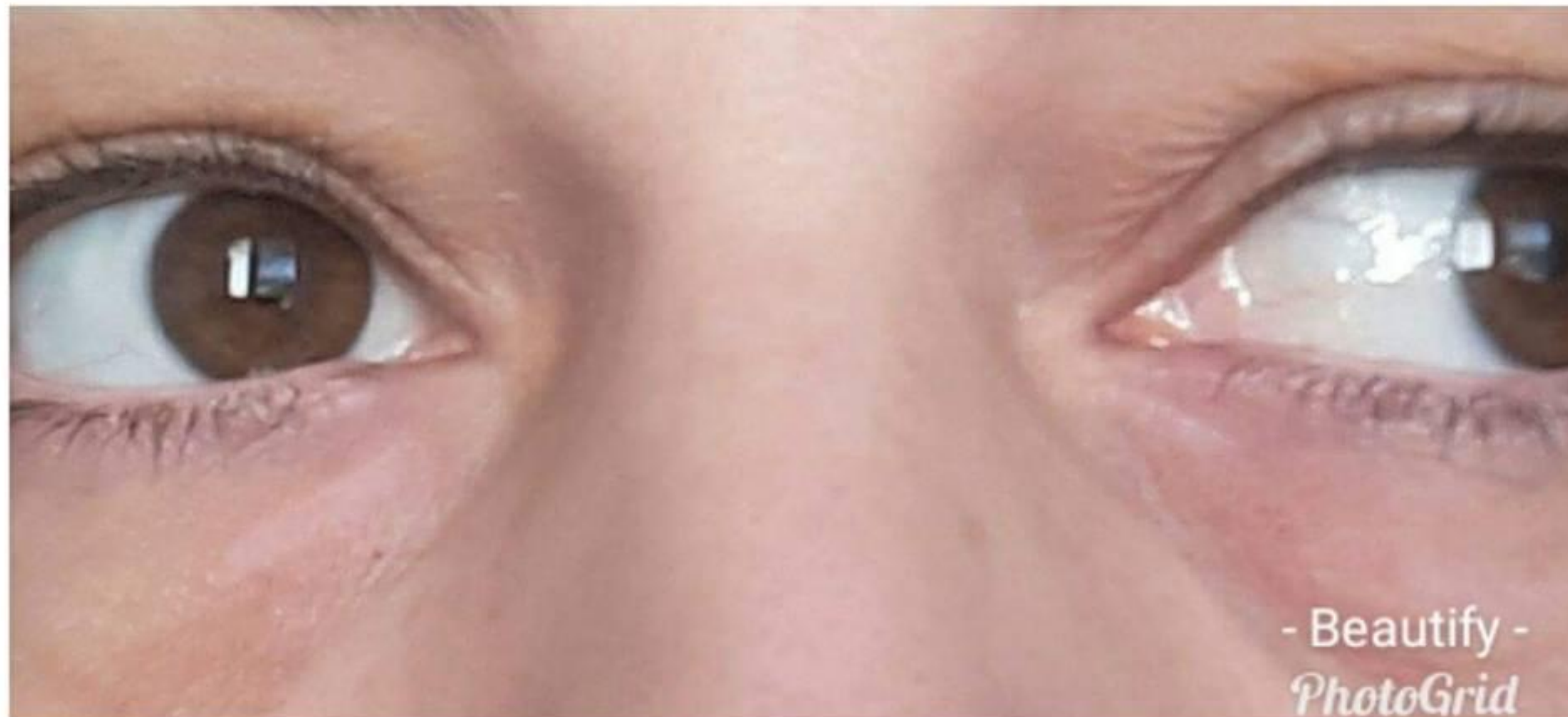

PLASMA[®]GE

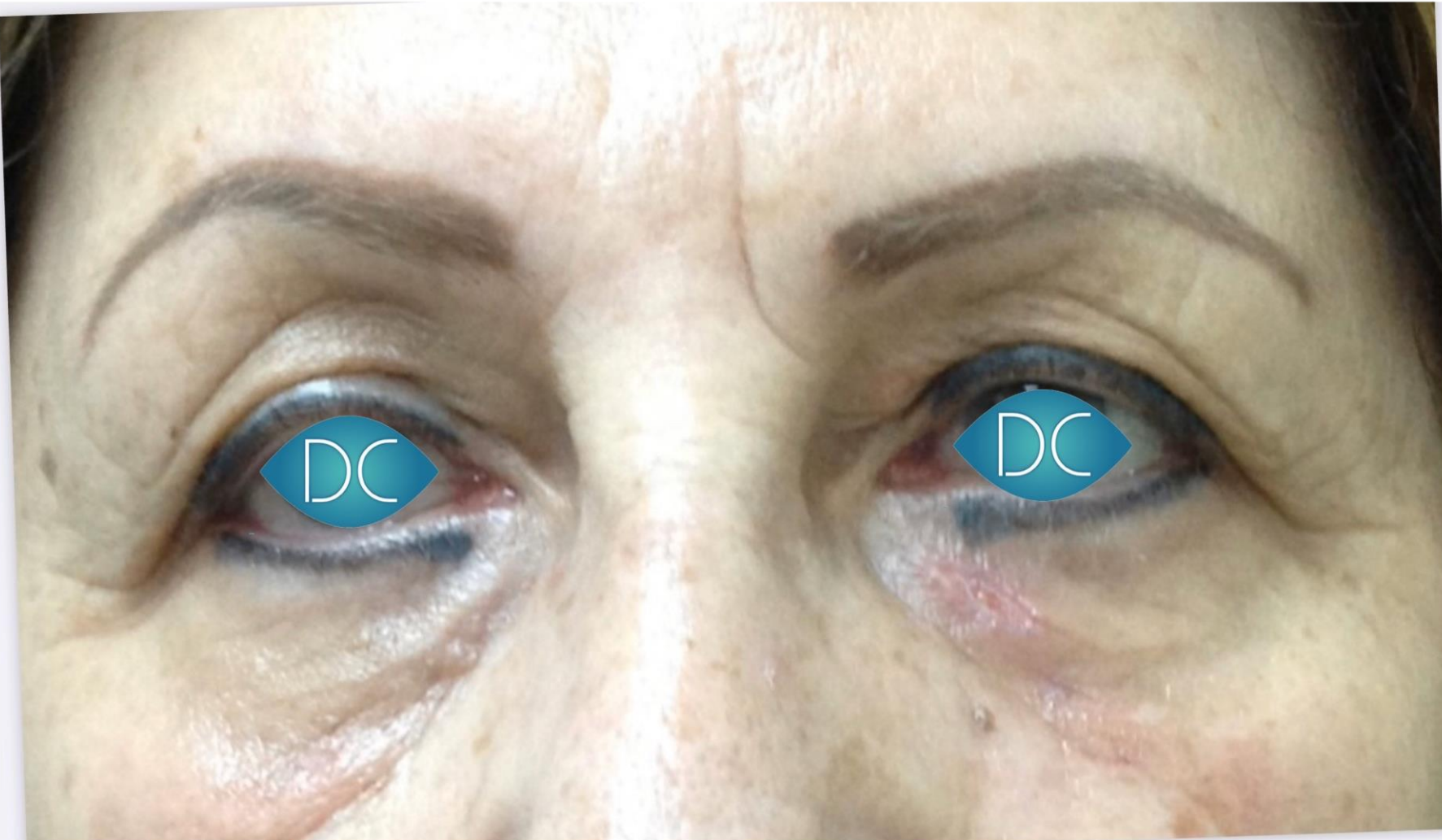
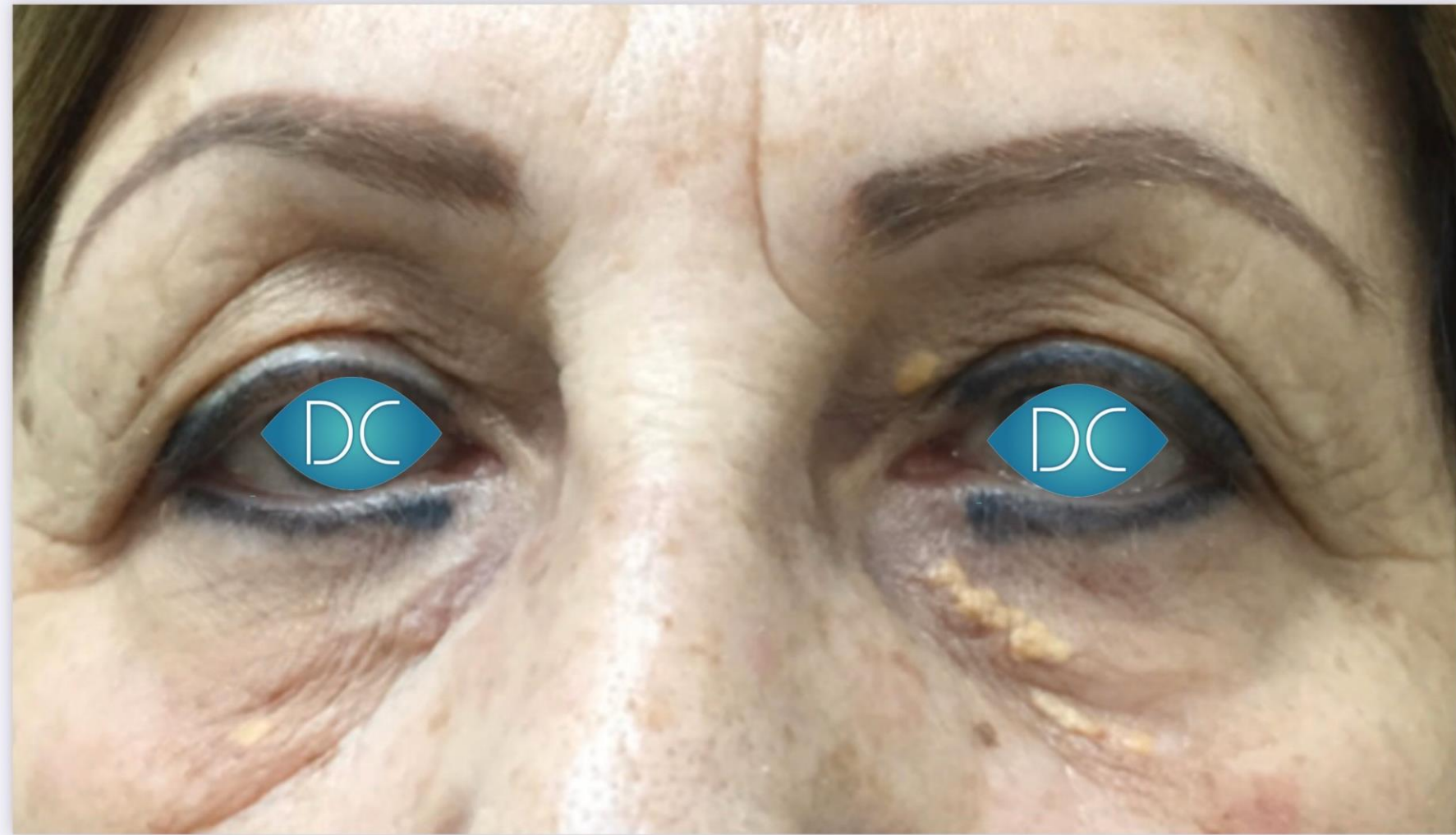
Xanthelasma



- with the courtesy of Oxygen, Tbilissi, Georgia
- 1 session: before and after one month



Xanthelasma removal with Plasmage



Dr. Dorina Cheles

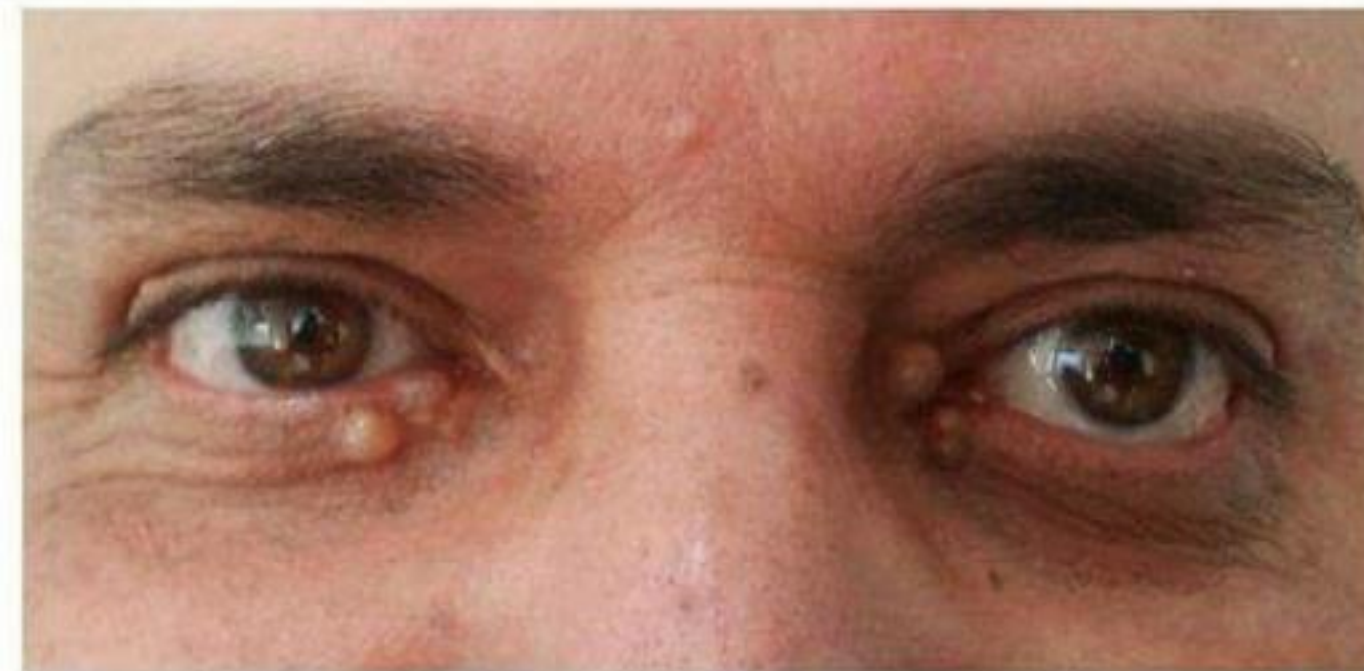PLASMAGE®

Xanthelasma

- with the courtesy of Dr Dorina Cheles, Israel
- 1 session: before and after one month

PLASMA[®]GE

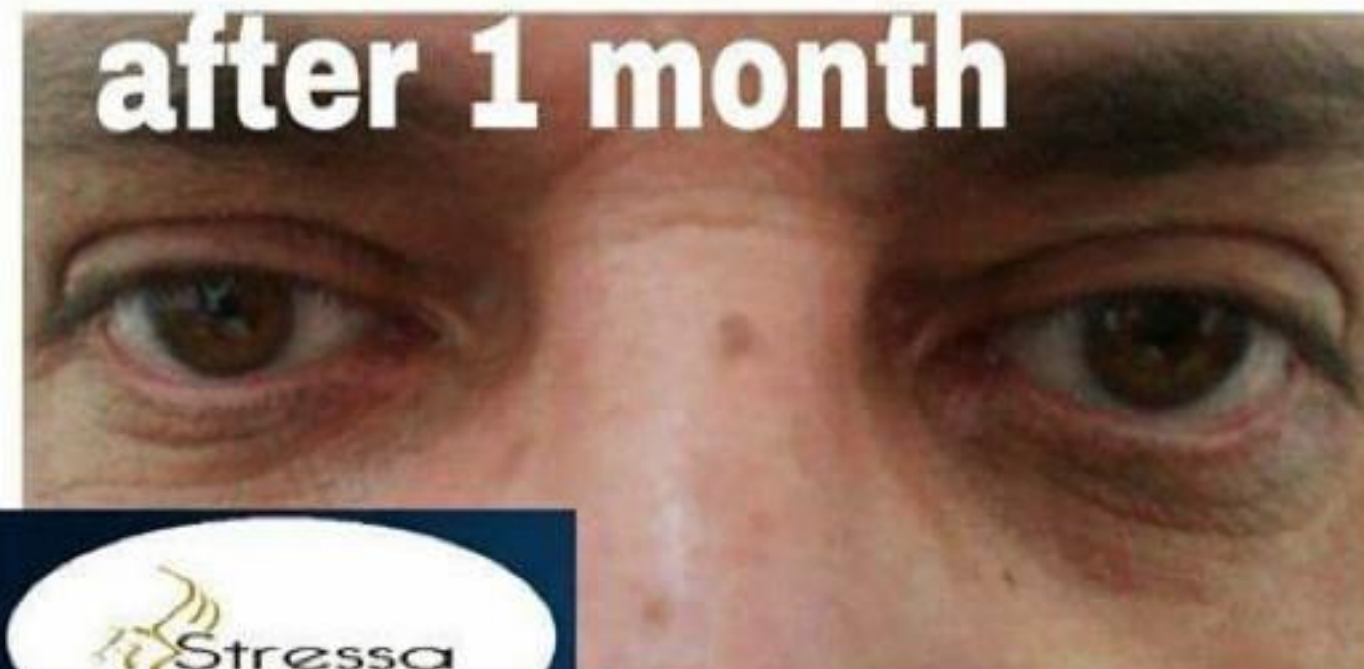Benign lesion



after the session



after 1 month



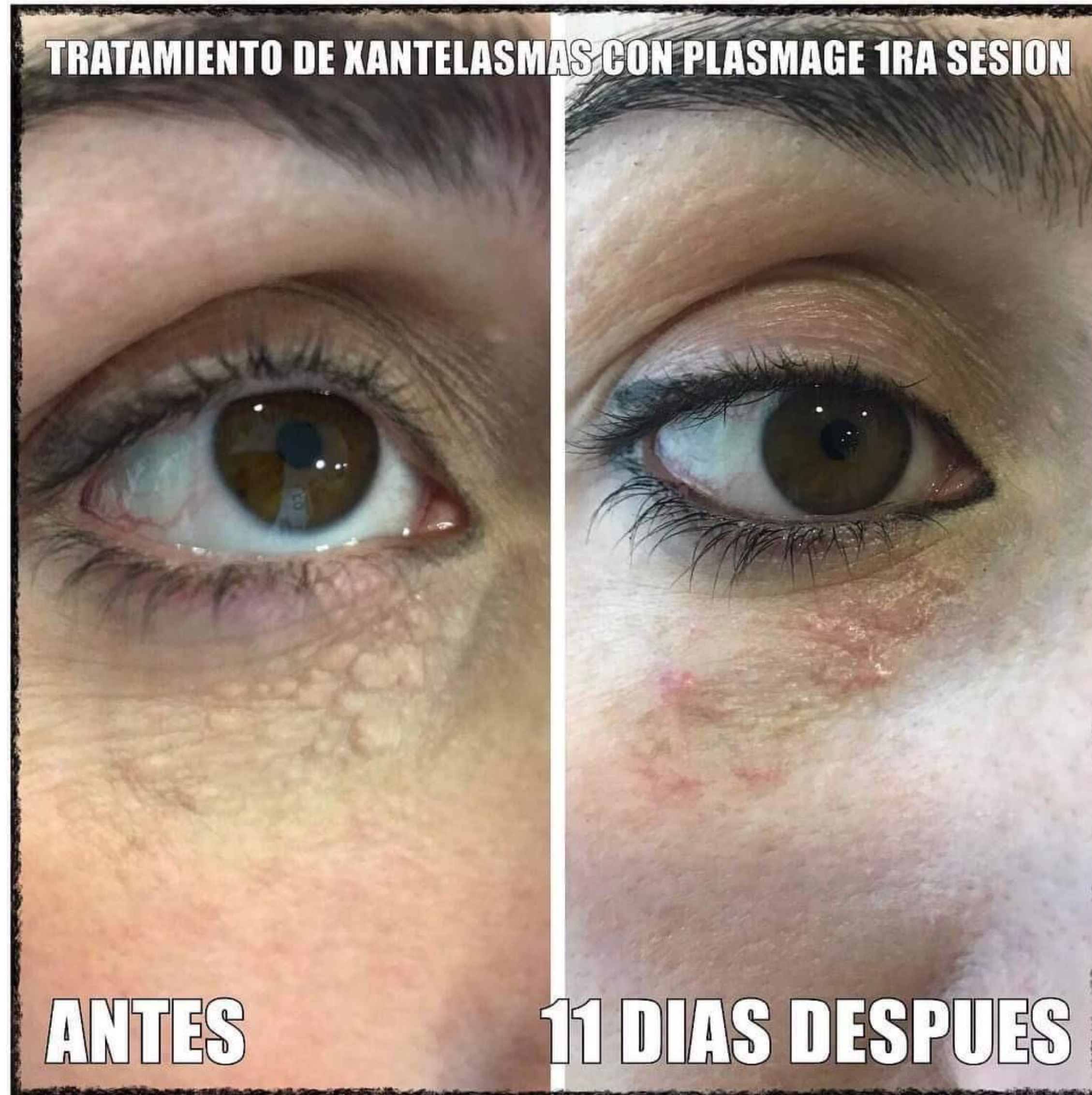- with the courtesy of Dr Asthma Mohammed, Cairo, Egypt
- one session

brera[®]
medical technologies

PLASMAGE®

Sringomas

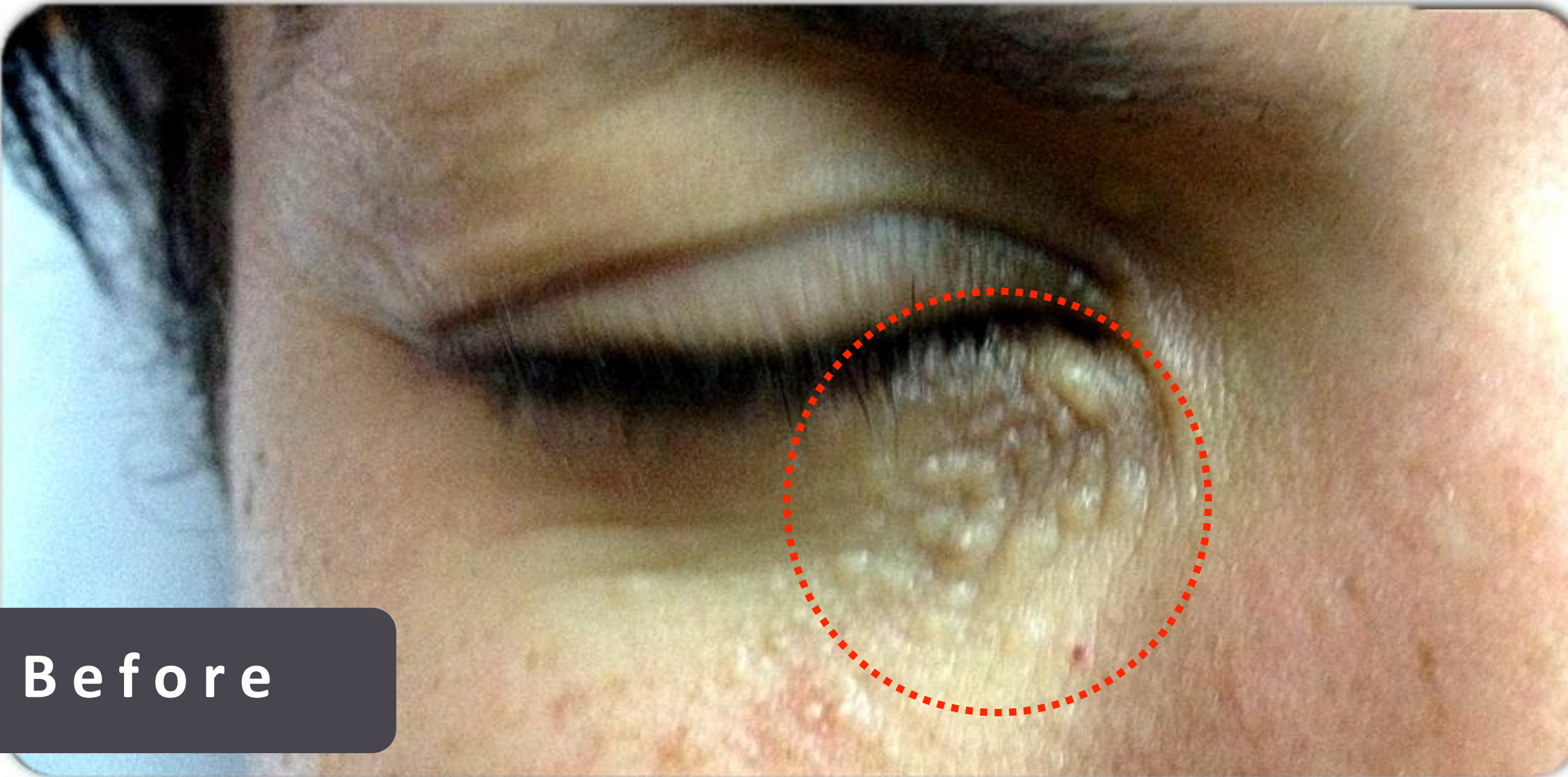- with the courtesy of Dr Alejandro ACUNA, Orense Spain
- after 1 session, 11 days later



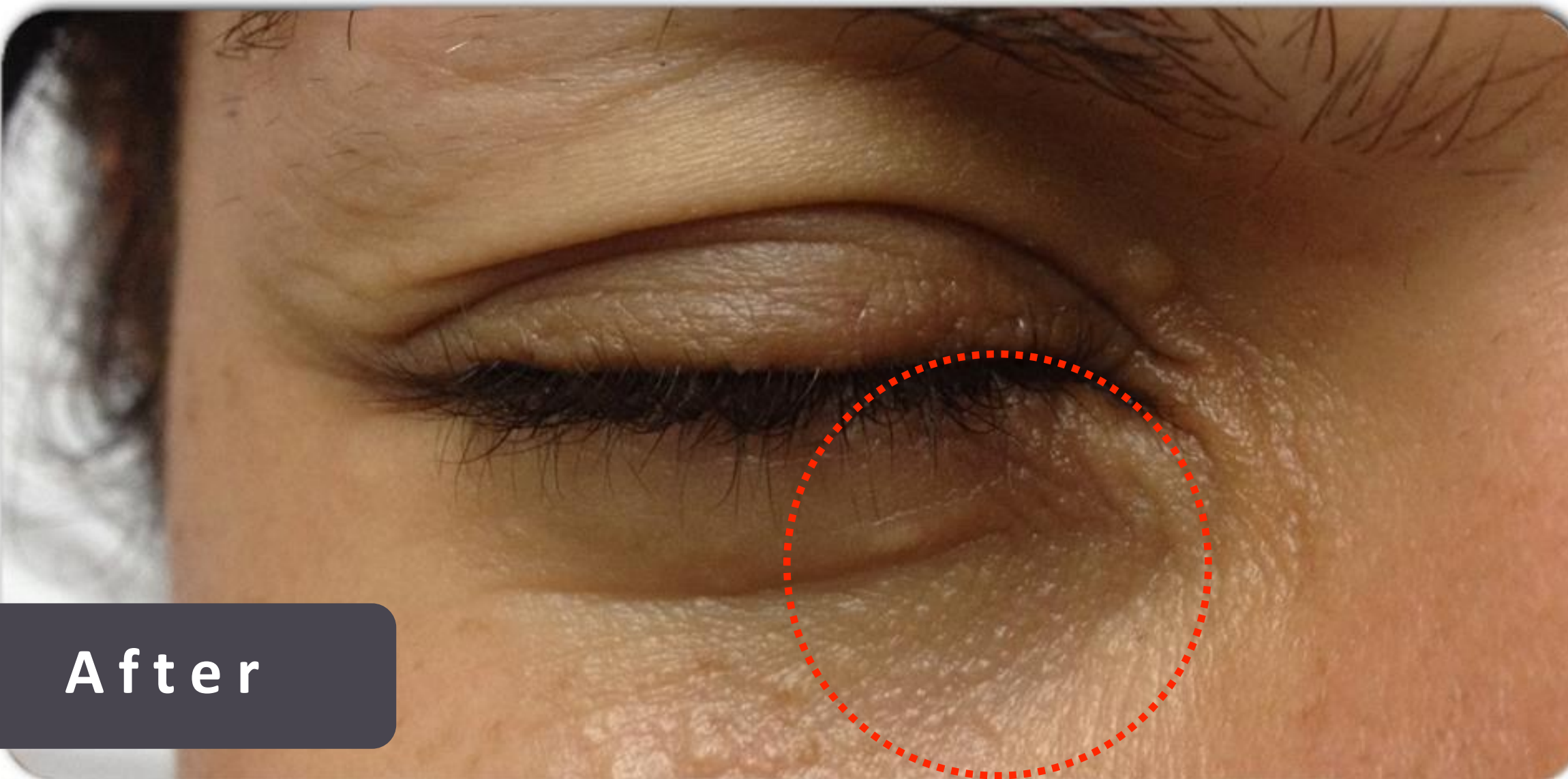PLASMA[®]GE

Sringomas

- with the courtesy of Dr Al Shaimaa Embaby, Cairo, Egypt
- 35 years old Female
- with multiple Sringomas around eyes
- after 1 session



Before



After

PLASMA[®]GE

Siringoma

- with the courtesy of Dr Serkan Oztuk Ankara, Turkey
- 1 session: before and 10 days after the treatment

PLASMA[®]GE

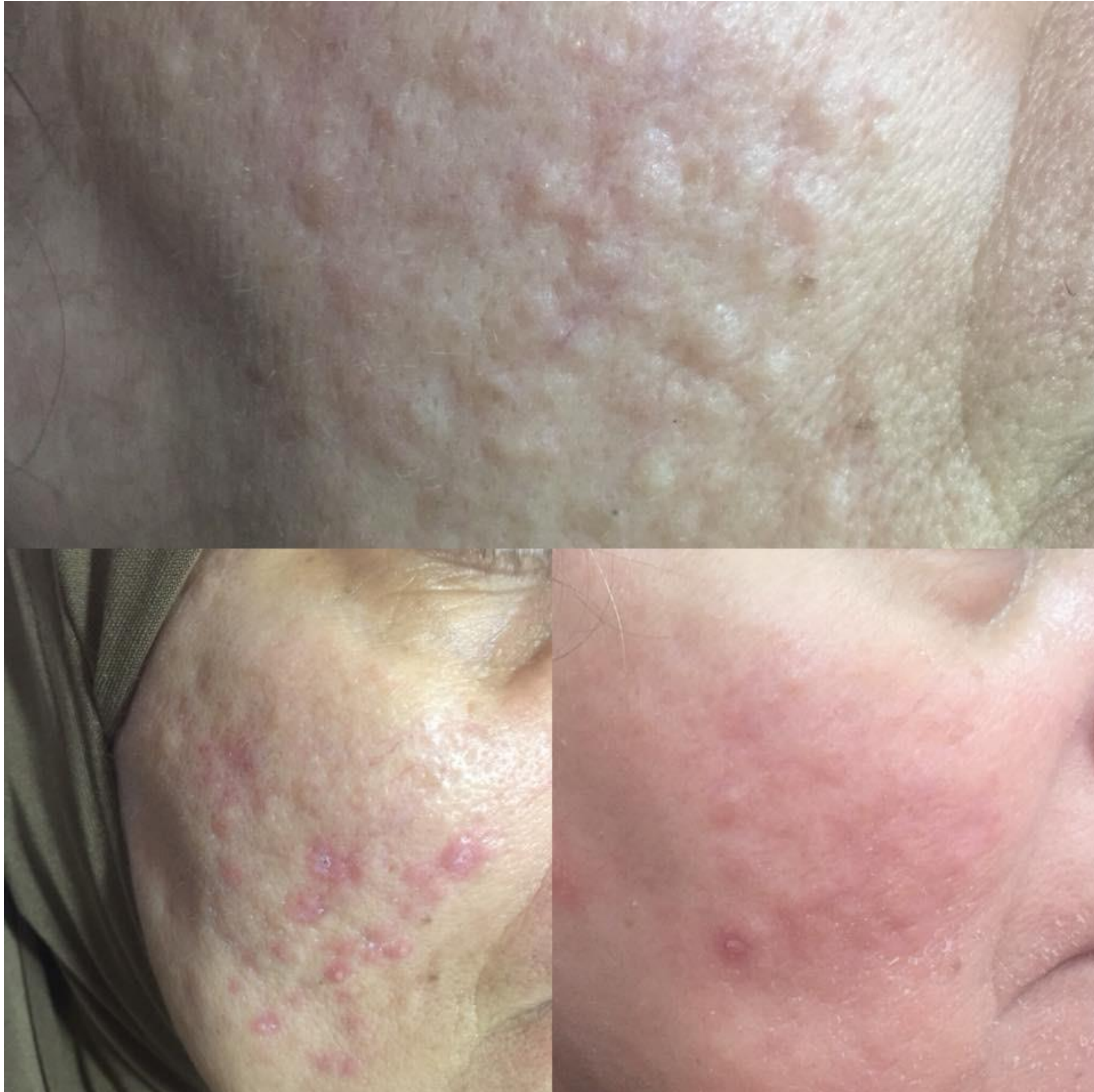Cheratosi

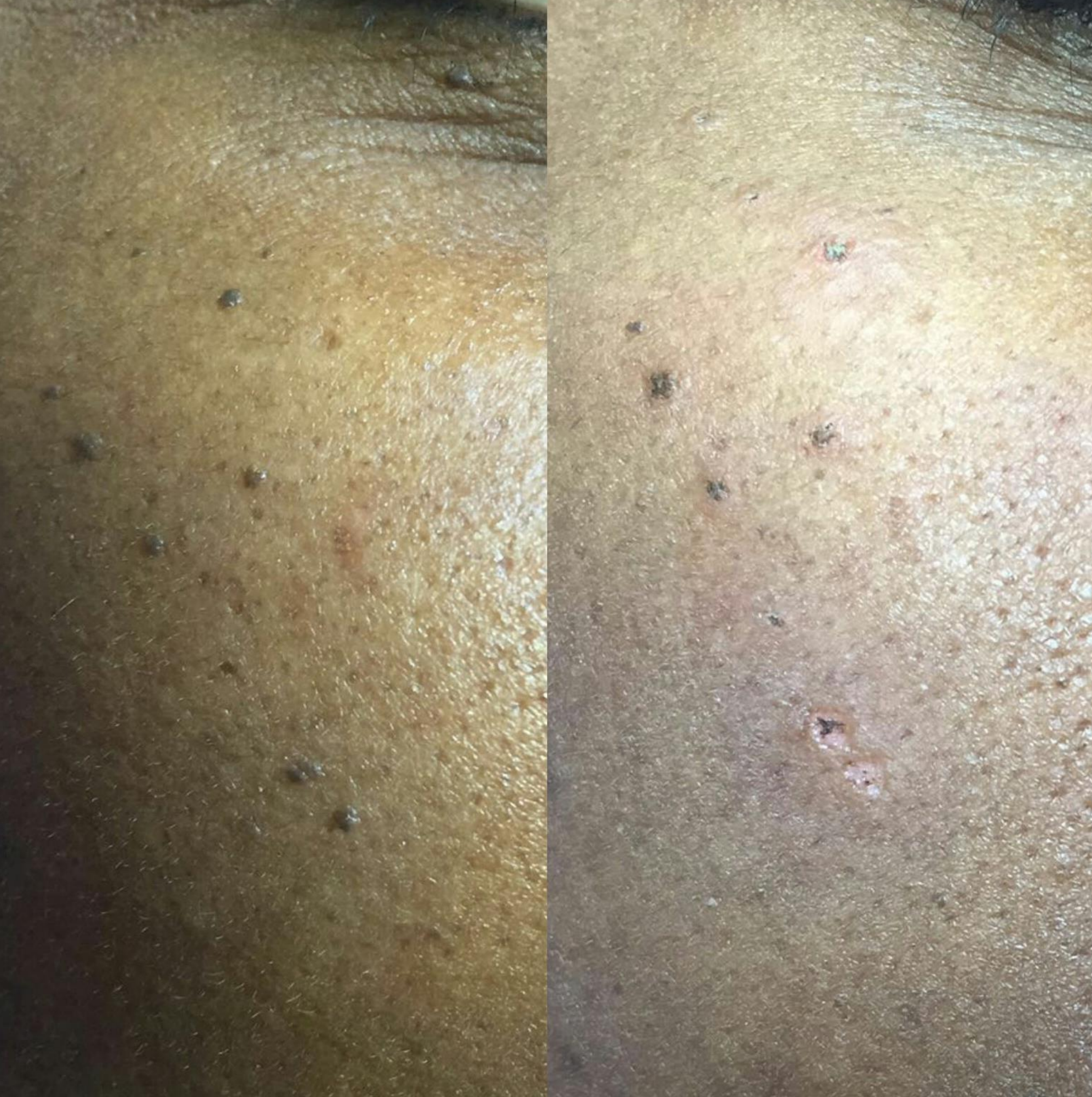- with the courtesy of Dr. Mohammad, Arbil, Iraq
- cheratosis removal
- 1 session: before, after the treatment and 7 days after

PLASMA[®]GE

Calcinosis cutis

- with the courtesy of Dr Salma Rifai Alkhatib, Amman Jordan
- Skin calcinosis (calcinosis cutis) on cheek of 45 year woman who suffered for long time with no response to any treatment
- 1 session: before, right after the treatment and one week later





PLASMA**GE**[®]

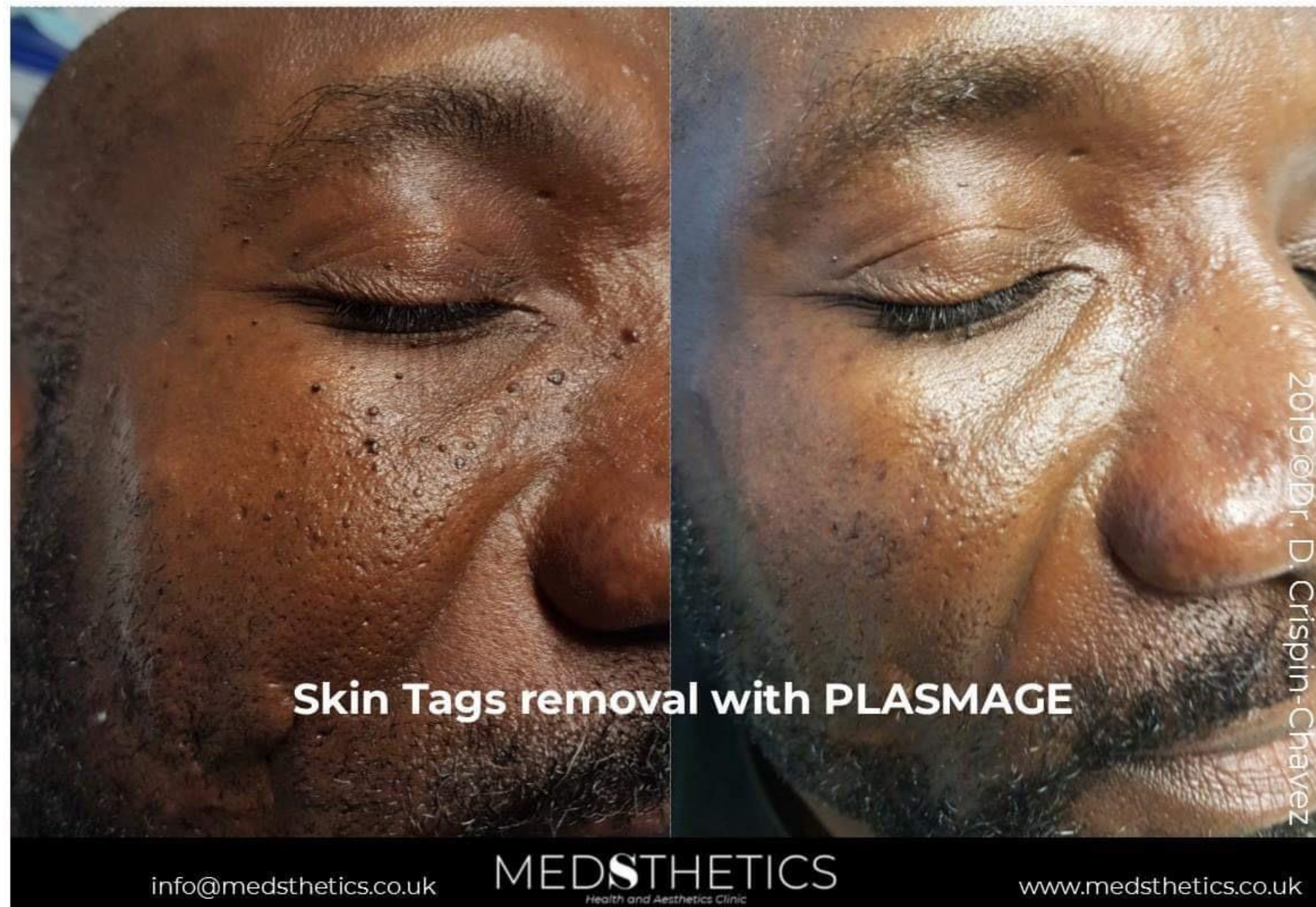Papulosa nigra

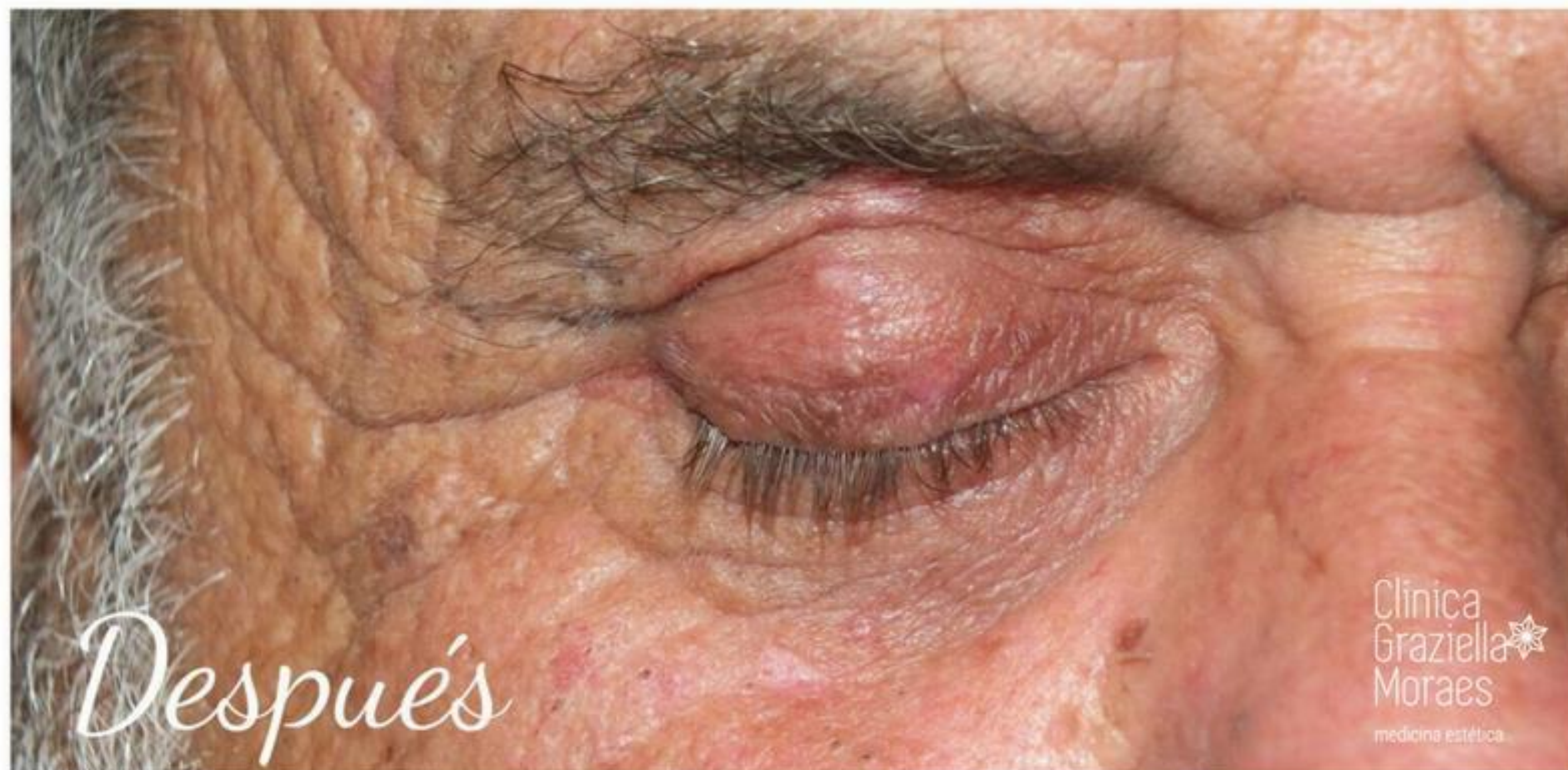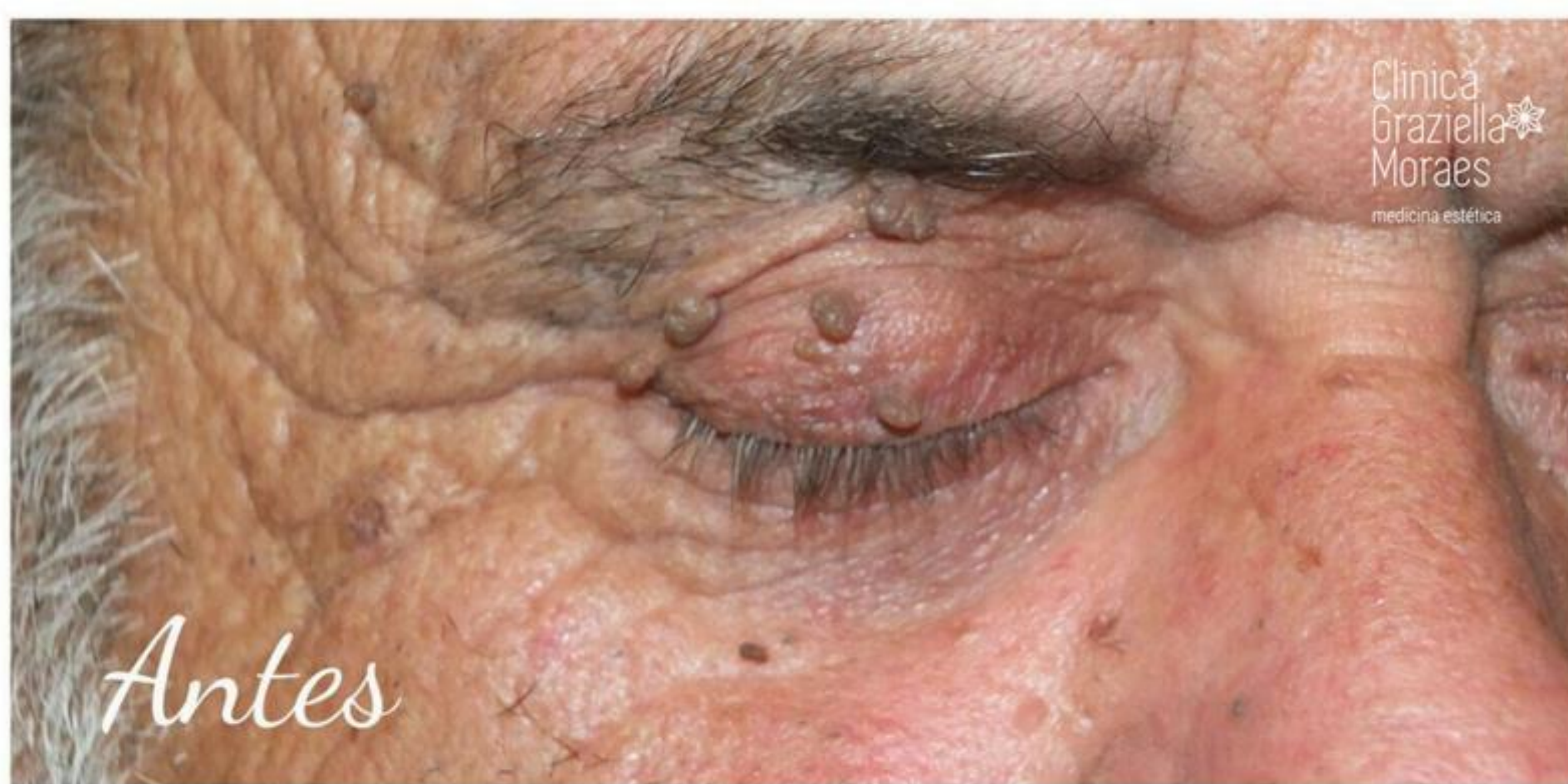- with the courtesy of Joanne Staniforth, Johannesburg, South Africa
- dermatosis papulosa nigra removal
- 1 session: before and right after the treatment

PLASMAGE®

Papulosa nigra

- with the courtesy of Dr David Crispin Chaves, UK
- dermatosis papulosa nigra removal
- 1 session: before and after





PLASMA[®]GE

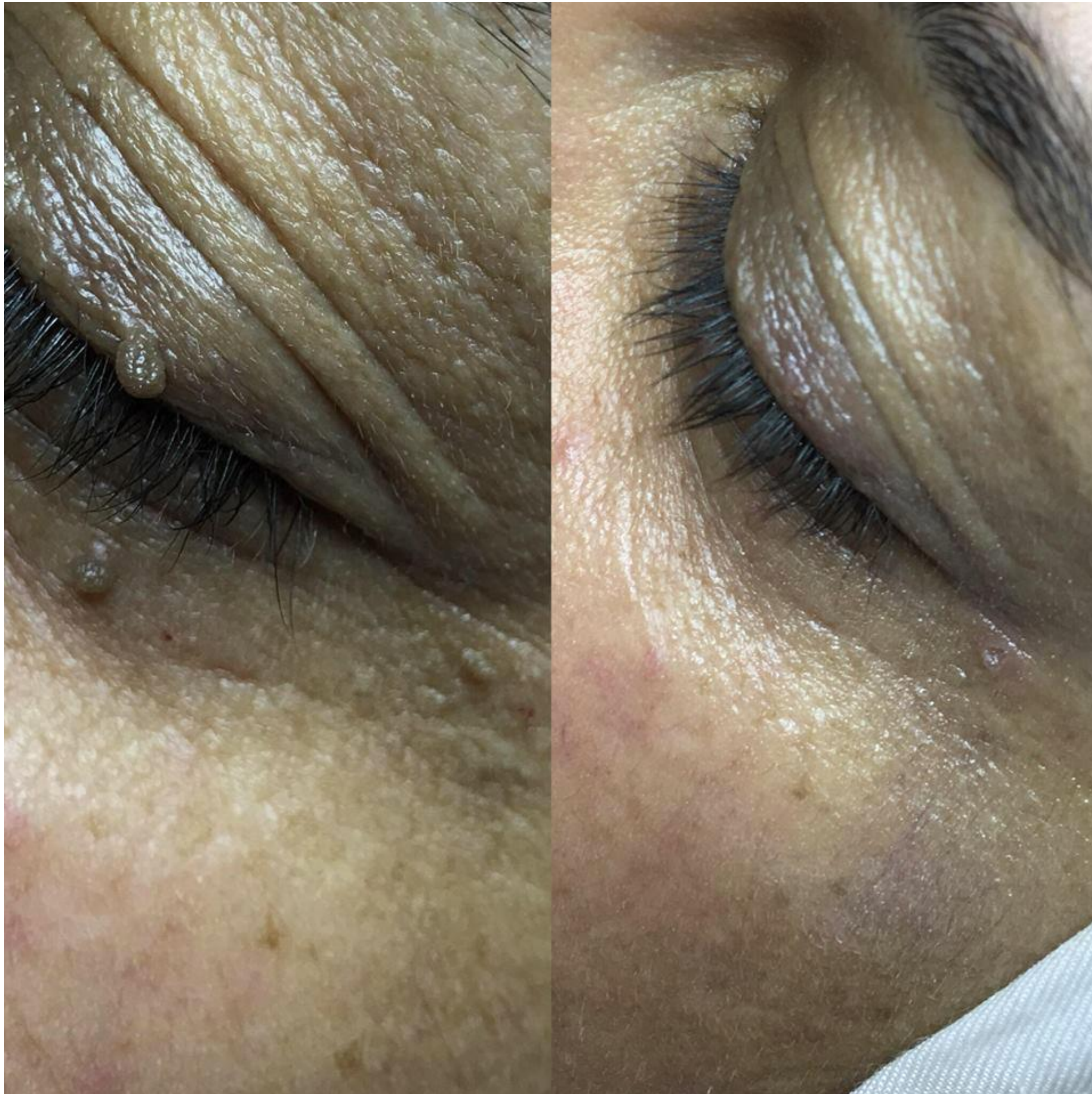skin tag

- with the courtesy of Dr Graziella Moraes, Vigo Spain
- skin tags on the eyelid
- 1 session: before and one month later

PLASMA[®]GE

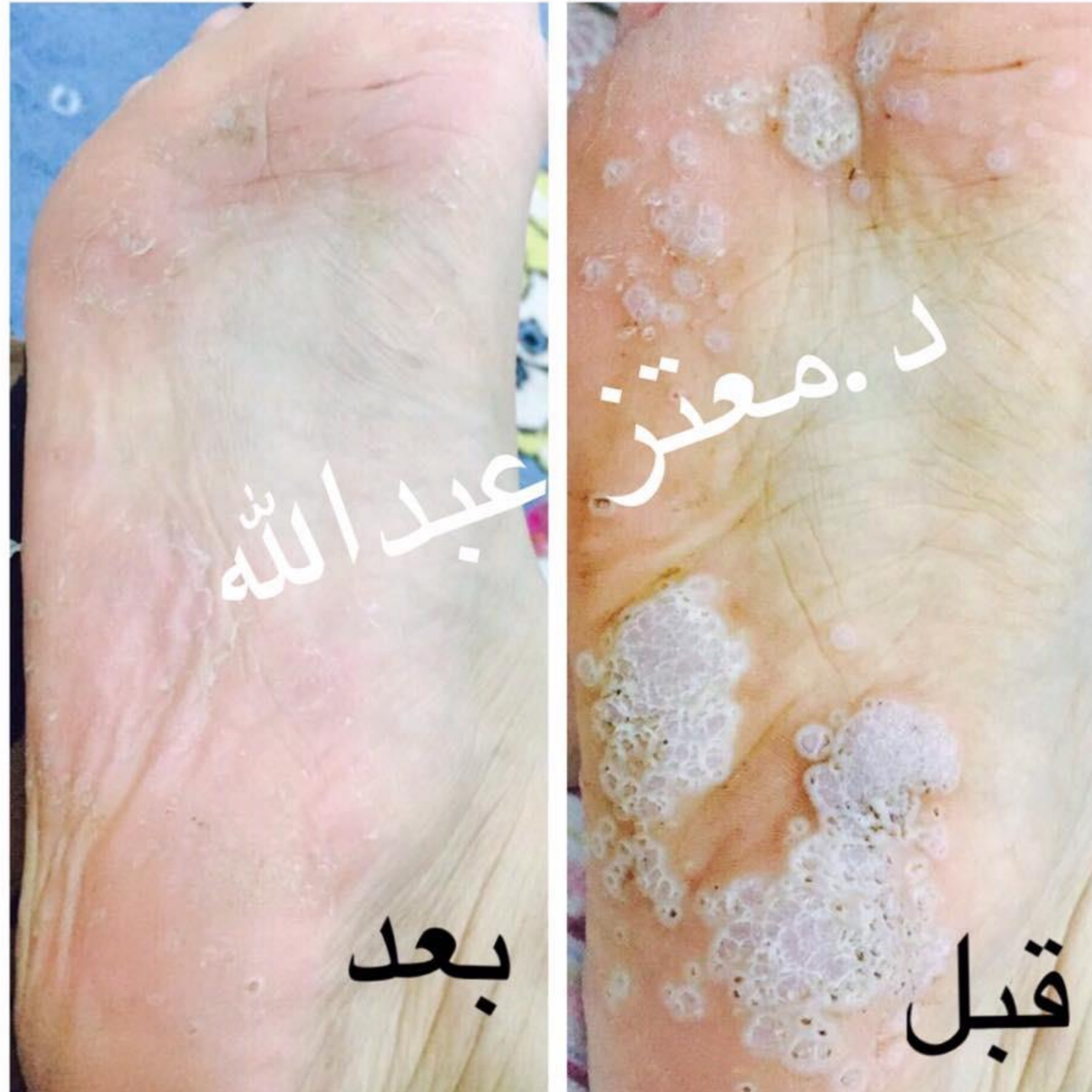skin tags

- with the courtesy of Dr Zafer Gökdemir, Adana Turkey
- skin tags
- 1 session: before and after 2 weeks



PLASMA[®]GE

warts

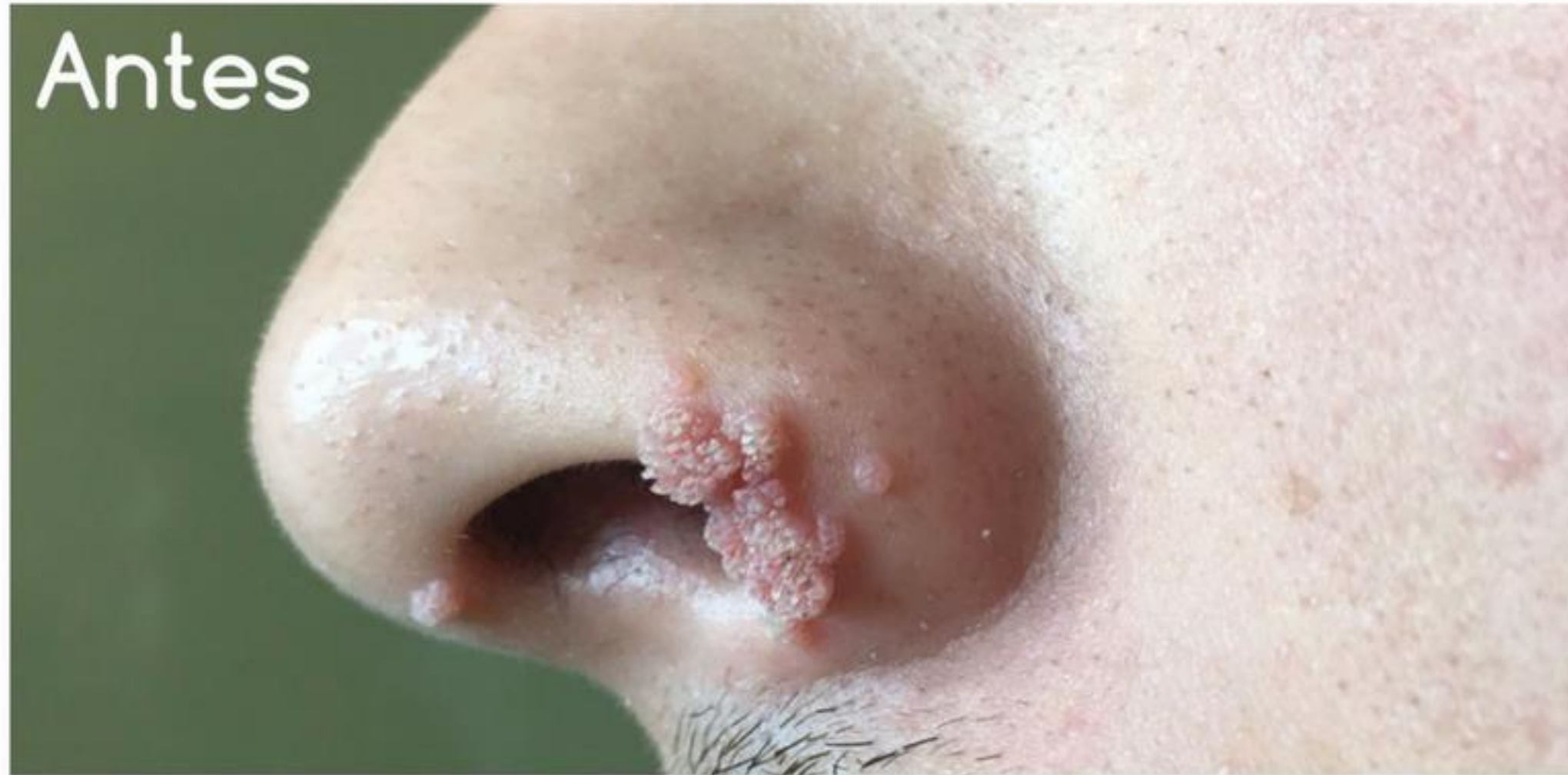

- with the courtesy of Dr Mutaz Al Rahmani
- after 1 session one month later

PLASMA[®]GE

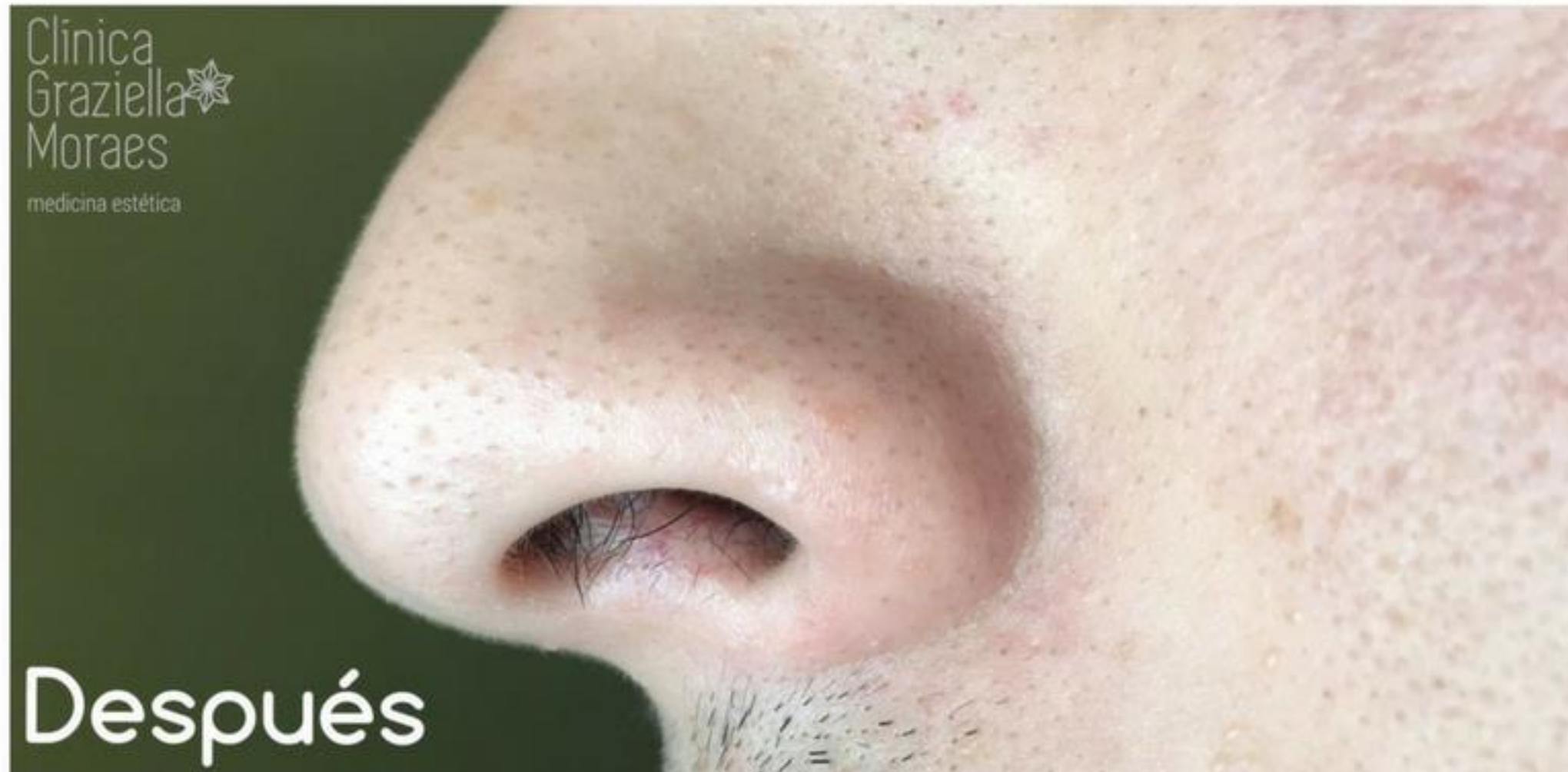warts

Antes



Clinica
Graziella
Moraes
medicina estética

Después



- with the courtesy of Dr Graziella MORAES, Vigo Spain
- after 1 session, 30 days later

brera[®]
medical technologies



PLASMA[®]GE

The new tool for dermatology
and aesthetic medicine:

- hypertrophic scars
- atrophic scars

PLASMA[®]GE

Keloid scars

- with the courtesy of Dr Al Shaimaa Embaby, Cairo, Egypt
- 27 years old male
- keloid scar in the face since 2 years
- results after 3 sessions

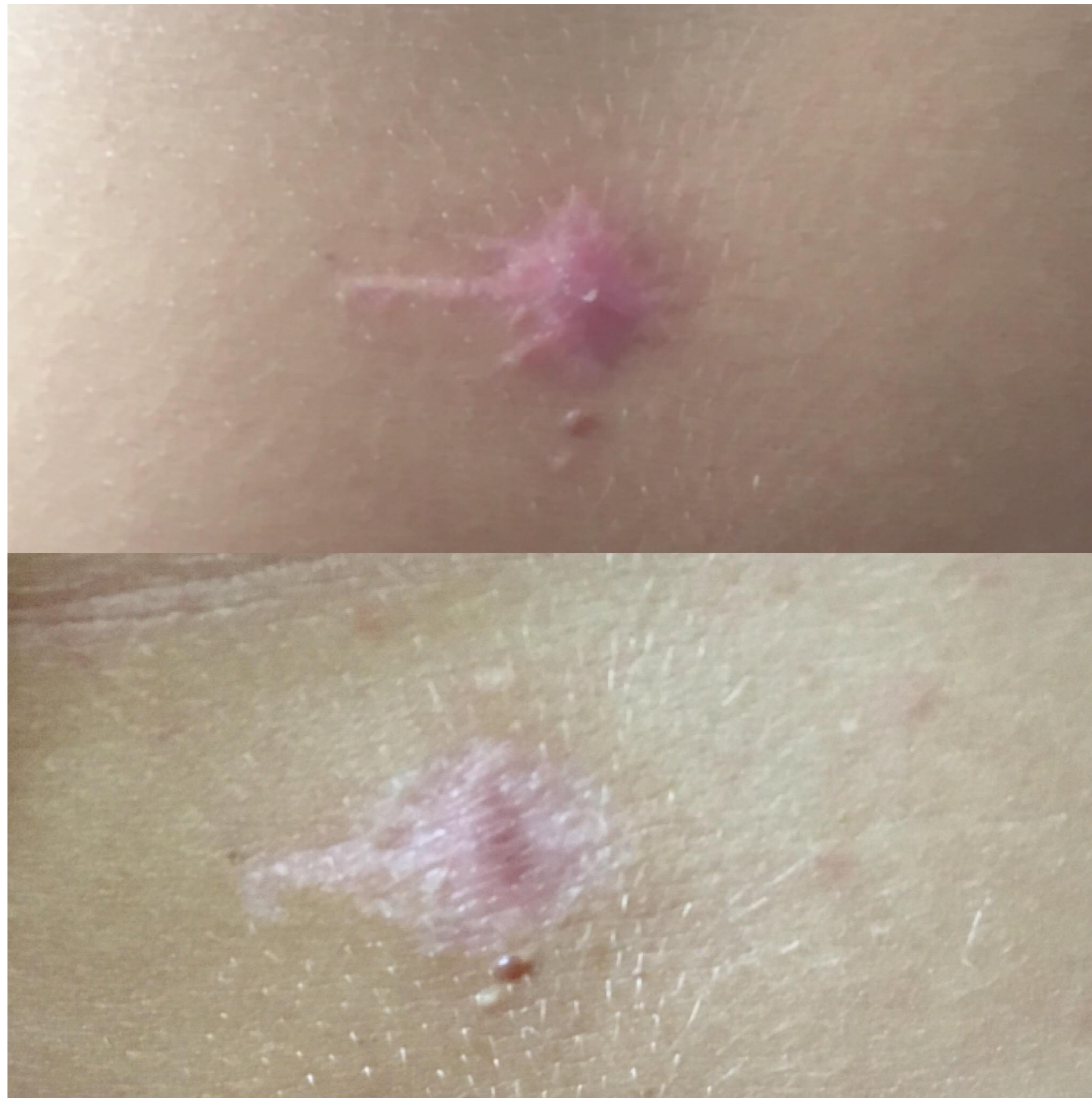Before

After

PLASMA[®]GE

Scar

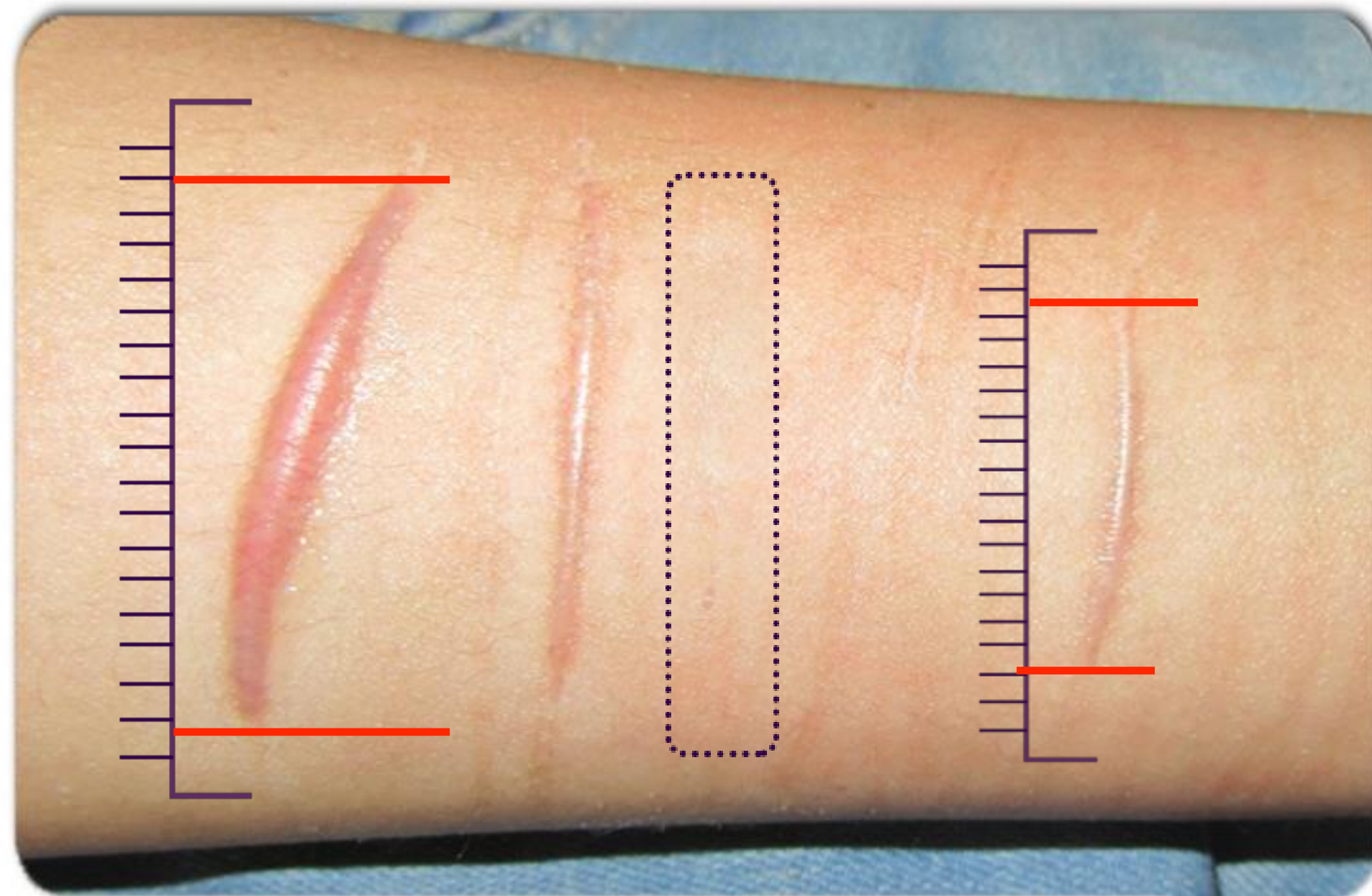
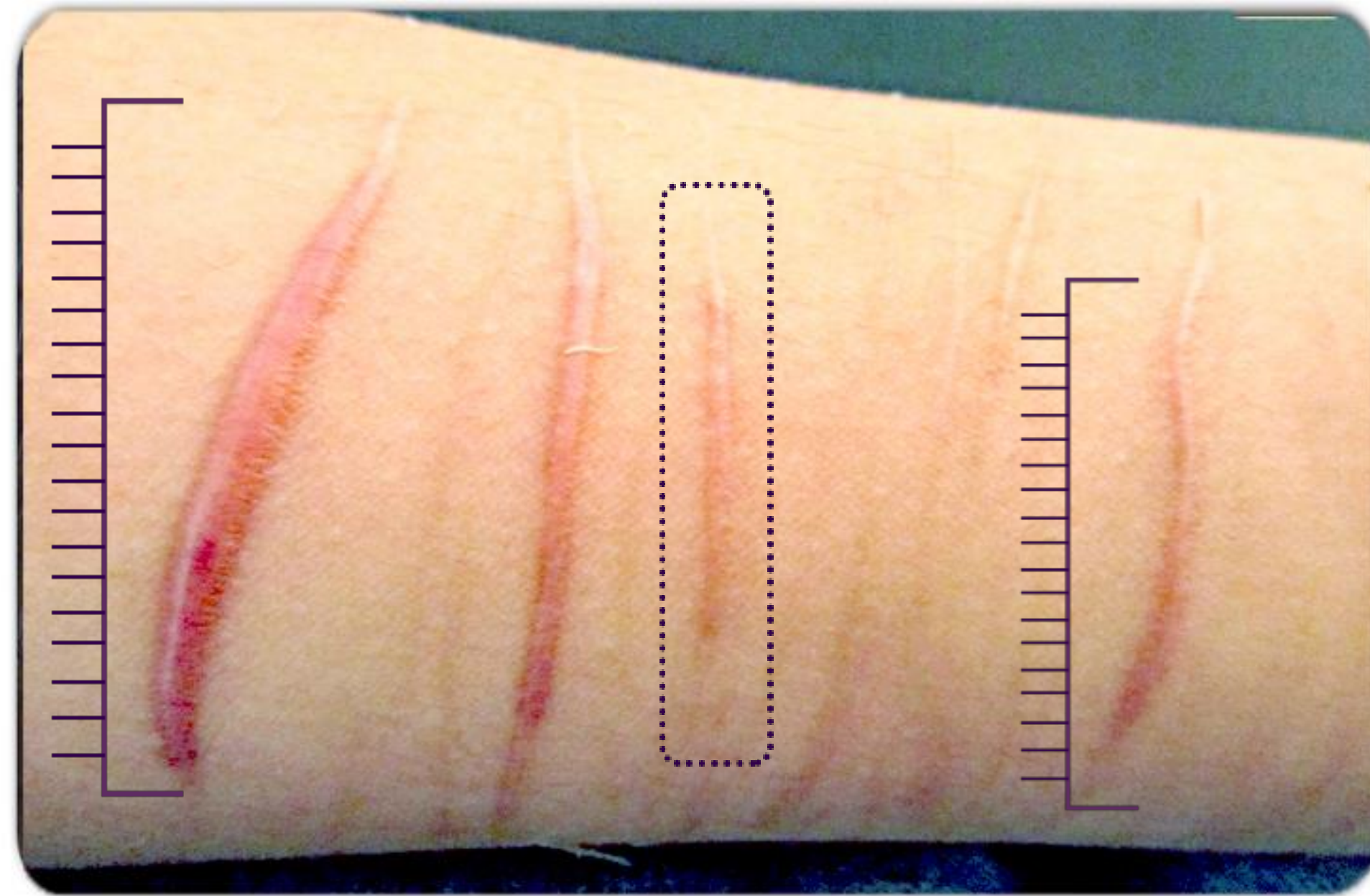
- with the courtesy Dr Nikola Milojevic, Zagreb, Croatia
- stable hypertrophic scar
- After two sessions



PLASMA[®]GE

Keloid scars

- with the courtesy of Dr Al Shaimaa Embaby, Cairo, Egypt
- 16 years old Female
- with Keliod scar in left forearm
- after 2 sessions



PLASMA[®]GE

Post acne scars

- with the courtesy of Dr Al Shaimaa Embaby, Cairo, Egypt
- 23 years old Female
- with Post acne Scars in left cheek
- after 2 sessions

A close-up photograph of a person's left cheek before the PLASMA[®]GE treatment. The skin shows several distinct, raised, and textured post-acne scars of varying sizes and depths.

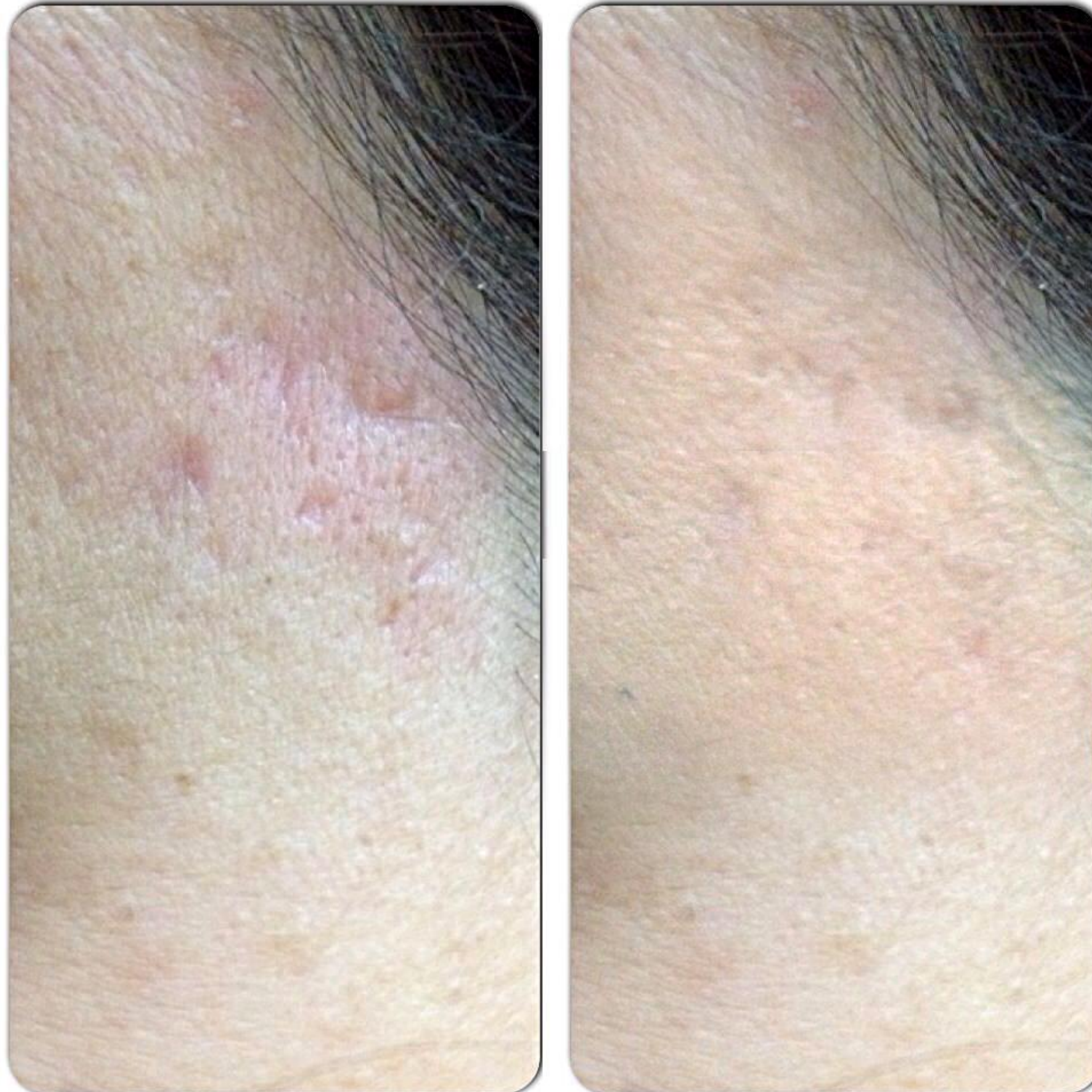Before

A close-up photograph of the same person's left cheek after two sessions of PLASMA[®]GE treatment. The skin appears significantly smoother and more uniform in color, with the previously visible scars being much less pronounced and more integrated into the surrounding skin texture.

After

PLASMA[®]GE

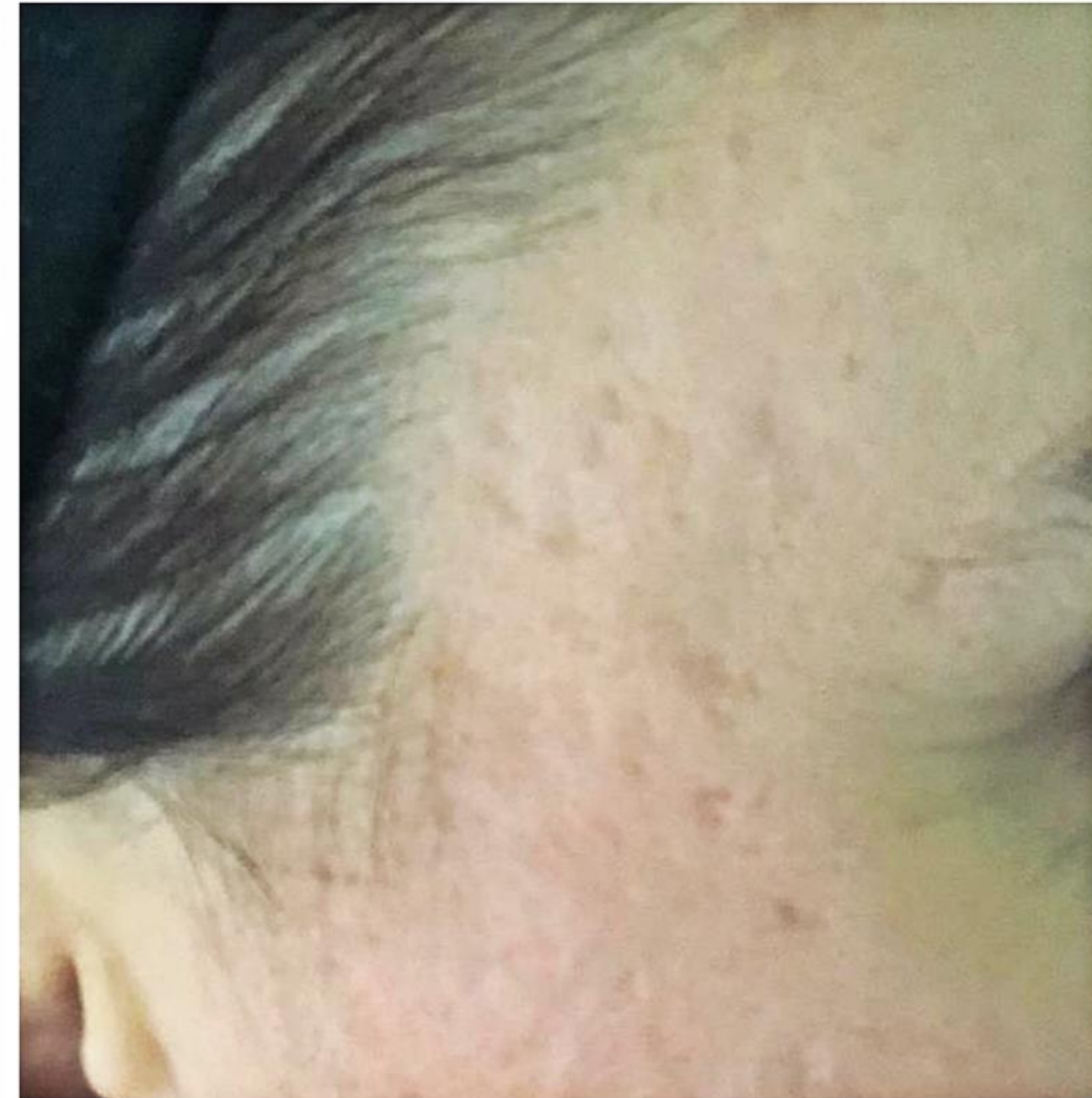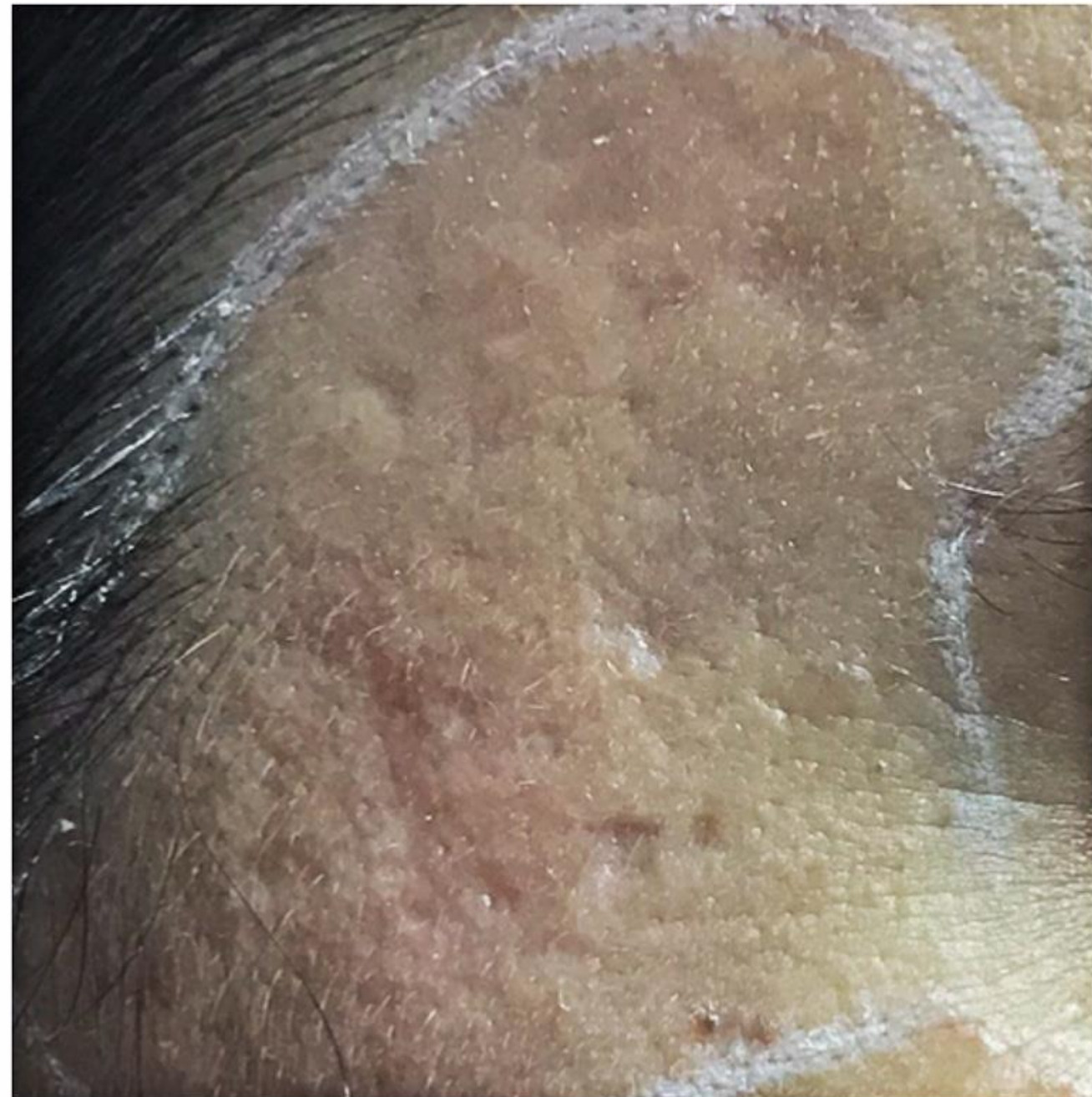Post acne scars



- with the courtesy of Dr Al Shaimaa Embaby, Cairo, Egypt
- 40 years old Female
- with Post Acne scars on left temporal area.
- after 1 session

PLASMA[®]GE

Post acne scars

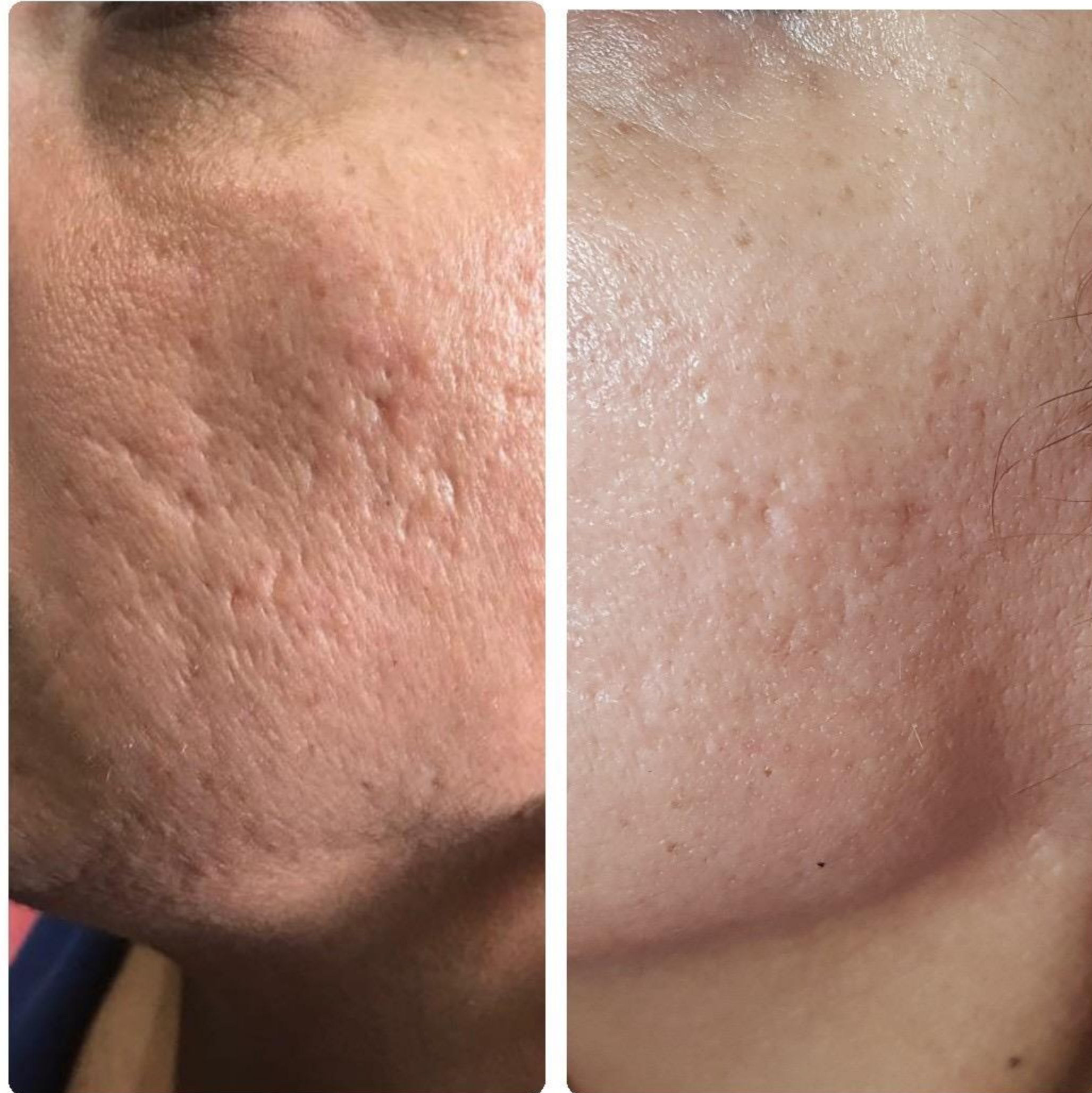

- with the courtesy of Dr Daniela Taher, Romania
- Post Acne scars on temporal area
- after 1 session

PLASMA[®]GE

Post acne scars

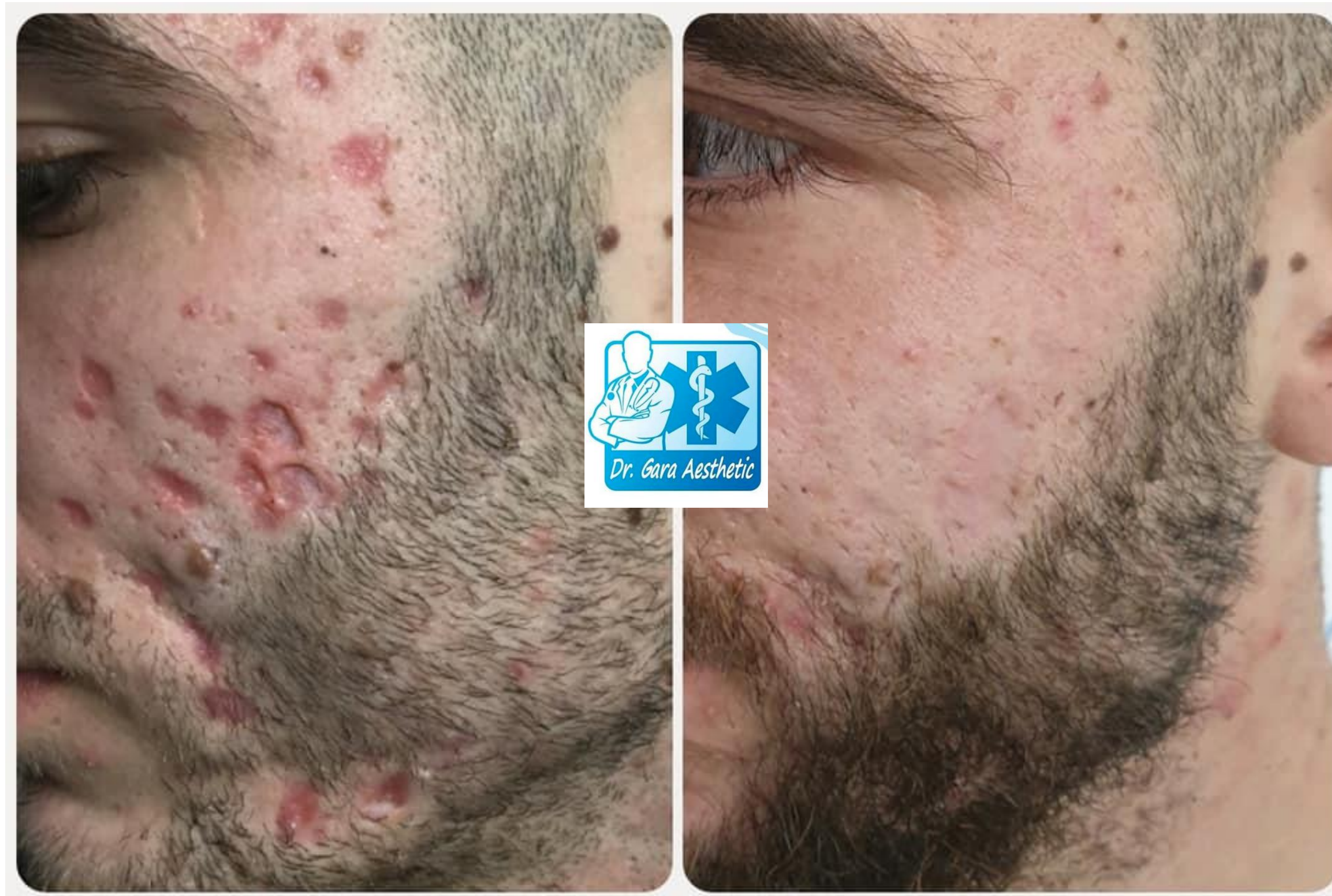- with the courtesy of Dr Raed Rtail, Lebanon
- after 1 session, one month later



PLASMAGE®

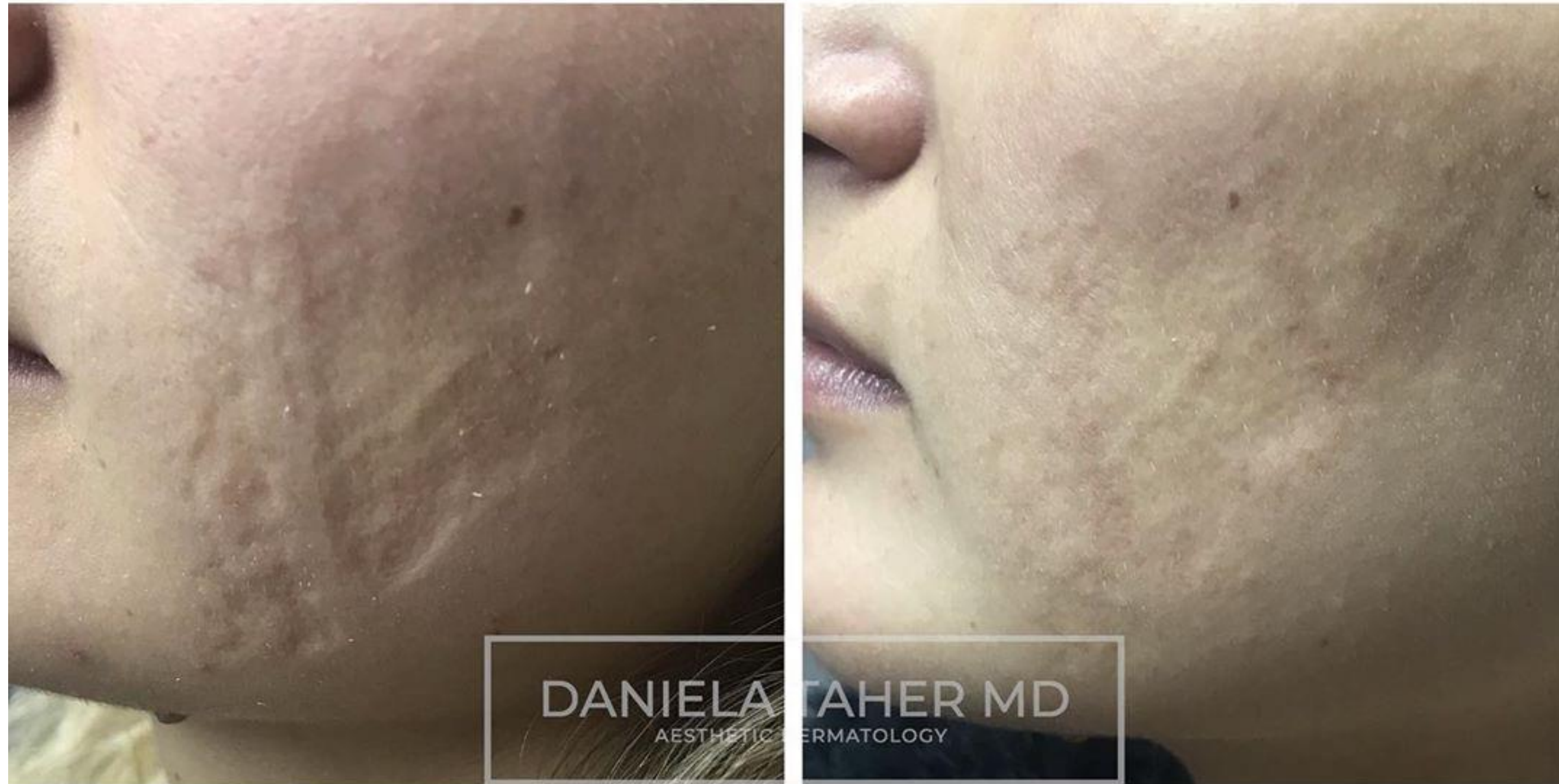Post acne scars

- with the courtesy of Dr Mohammed Gara, Israel
- three sessions of Plasmage, 2 sessions of subcision in between, 1 month intervals

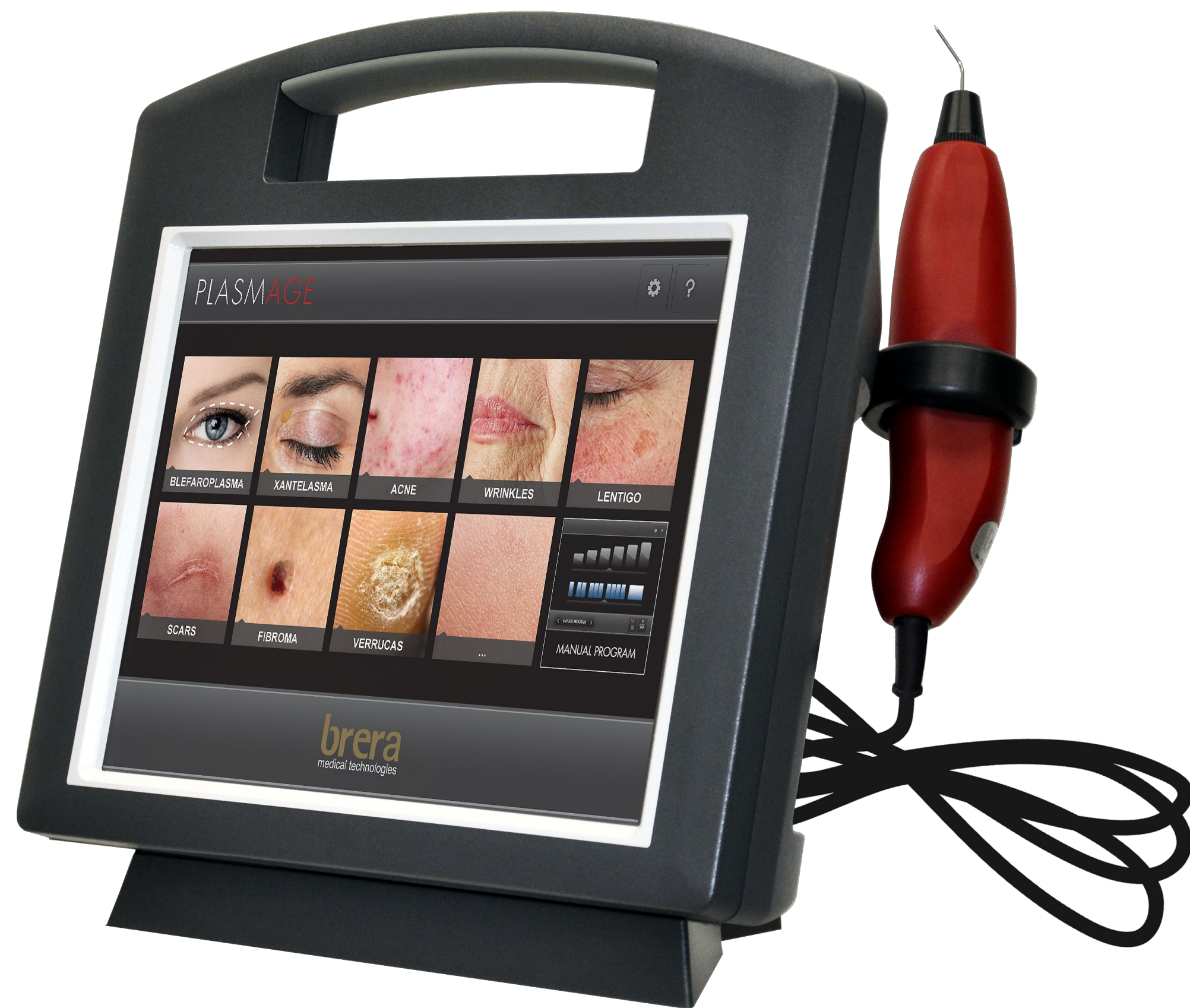

PLASMAGE®

Post acne scars



- with the courtesy of Dr Daniela Taher, Romania
- after 1 session
- combination of Plasmage, subcision and RF needling



PLASMAGE®

Be on cutting edge of medical technologies:

- fractional plasma
- already in more than 45 countries
- 30 possible combinations
- great results
- new protocols

THANK YOU!

www.breramedical.com

www.plasmage.com

[brera](http://www.brera.com)[®]
medical technologies